

Nonoperative treatment of PIPJ flexion contractures associated with Dupuytren's Disease

J. Larocerie-Salgado and J. Davidson
J Hand Surg Eur Vol published online 30 September 2011
DOI: 10.1177/1753193411422680

The online version of this article can be found at:
<http://jhs.sagepub.com/content/early/2011/09/30/1753193411422680>

Published by:



<http://www.sagepublications.com>

On behalf of:

[British Society for Surgery of the Hand](#)



[Federation of the European Societies for Surgery of the Hand](#)



Additional services and information for *Journal of Hand Surgery (European Volume)* can be found at:

Email Alerts: <http://jhs.sagepub.com/cgi/alerts>

Subscriptions: <http://jhs.sagepub.com/subscriptions>

Reprints: <http://www.sagepub.com/journalsReprints.nav>

Permissions: <http://www.sagepub.com/journalsPermissions.nav>

>> [Proof](#) - Sep 30, 2011

[What is This?](#)

Nonoperative treatment of PIPJ flexion contractures associated with Dupuytren's Disease

J. Larocerie-Salgado

Hotel Dieu Hospital, Kingston, Ontario, Canada

J. Davidson

Division of Plastic Surgery, Department of Surgery, Queen's University, Hotel Dieu Hospital, Kingston, Ontario, Canada

The Journal of Hand Surgery
(European Volume)
0(00) 1-6
© The Author(s) 2011
Reprints and permissions:
sagepub.co.uk/journalsPermissions.nav
DOI: 10.1177/1753193411422680
jhs.sagepub.com



Abstract

Post-surgical outcomes in patients with Dupuytren's disease causing flexion contractures of the proximal interphalangeal joint can be inconsistent and are often associated with protracted rehabilitation, reduced flexion, recurrence of the contracture, and patient dissatisfaction. An alternative treatment option, comprised of splinting and soft tissue mobilization techniques, was introduced to stabilize early contractures of the proximal interphalangeal joint in the hopes of delaying or obviating surgery. Over the course of approximately 12.6 months (± 7.8), thirteen patients were followed at the hand clinic at Hotel Dieu Hospital in Kingston. One patient was unable to complete the course of therapy. Of the remaining patients, analysis showed significant improvement in active proximal interphalangeal joint extension of approximately 14.6° (SD: $\pm 5.1^\circ$; range: $5-25^\circ$) over the course of the treatment ($p < .05$). Nighttime static extension splinting and soft tissue mobilization techniques appear to delay and possibly prevent the need for surgery in individuals with flexion contractures of the proximal interphalangeal joint due to Dupuytren's disease.

Keywords

Dupuytren's disease, PIPJ contractures, splinting, low load forces

Date received: 2nd December 2010; revised: 12th July 2011; accepted: 15th August 2011

Introduction

Outcomes following surgical management of proximal interphalangeal joint (PIPJ) contractures in Dupuytren's disease (DD), and in the little finger in particular, are at best inconsistent. There is frequently decreased range of motion, pain, protracted rehabilitation and recurrence and sometimes worsening of the contracture that can lead to significant functional impairments and patient dissatisfaction (Andrew, 1991; McFarlane, 1993; Weinzweig et al., 1996; Denkler, 2010). Once considered an absolute indication for surgical intervention, even early PIPJ contractures are approached with surgical trepidation, with partial correction or stabilization of the progression of the disease being an acceptable therapeutic goal (McFarlane, 1993). The experience at our centre has been no different and we have consequently considered alternative approaches to the management of PIPJ contractures in patients with early stages of presentation.

It is dogma that splinting alone confers no advantage in the management of DD (Schultz-Johnson, 2002; Townley et al., 2006). However, this seems counterintuitive given the demonstrated benefit of splinting and the application of longitudinal load forces on collagen remodelling in traumatic scars not to mention their important role in post-surgical rehabilitation of patients with DD (Engstrand et al., 2009; Flowers and LaStayo, 1994; Glasglow et al., 2003; Mckee and Morgan, 1998). We have examined the role of splinting, tissue mobilization, and the use of low load forces to lengthen contracted tissue in patients with mild to moderate PIPJ contractures

Corresponding author:

John Davidson MD MSc, Hotel Dieu Hospital, 166 Brock St, Kingston - On, K7L 5G2, Canada
Email: davidsoj@hdh.kari.net

with respect to delaying or obviating surgical intervention.

Methods

The study was approved by the Ethics Review Board of the Faculty of Medicine, Queen's University, Kingston, Ontario.

Patients sequentially referred to the hand surgical service at Hotel Dieu Hospital for assessment of early Dupuytren's disease with flexion contractures of the PIPJ were offered a trial of nonoperative treatment. These patients primarily manifested mild to moderate PIPJ flexion contractures (between 15° and 60°) of the long, ring and/or little fingers and no significant functional limitations associated with the condition. Those consenting to participate in the intervention protocol outlined below were included in this case series for data analysis.

The intervention protocol was comprised of nighttime splinting and tissue mobilization techniques, based on the premise of tissue remodelling related to the exposure to a maximum tolerable, prolonged low load torque applied at its end range (Cyr and Ross, 1998; Flowers and LaStayo, 1994; Glasgow et al., 2003; McKee and Morgan, 1998). The splinting regimen consisted of a hand-based volar extension splint, with an adjustable strap placed over involved PIP joints (Figure 1). Patients were instructed to wear the splint at nighttime (6–8 hours) to allow for prolonged exposure of the contracted tissue to low load forces while permitting unrestricted use of the hand during the day (Flowers and LaStayo, 1994; Glasgow et al., 2003). When appropriate, splints were adjusted to increase PIPJ extension at the time of follow-up visits. Patients were also instructed to perform stretching exercises for the PIP joint into extension within pain-free range as well as friction massage to contracted tissue (i.e. nodules and cords) during the day.

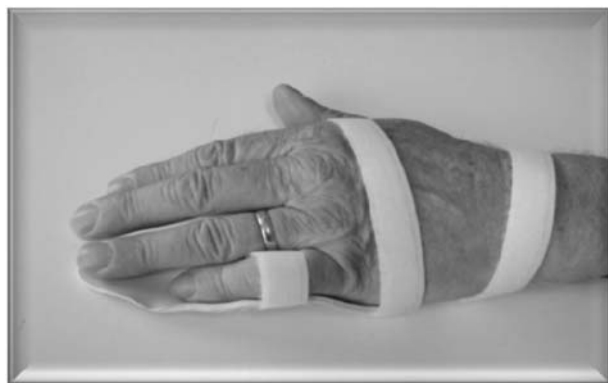

Figure 1. Volar hand-based extension splint.

Some patients having difficulty adhering with (PT5 and PT9) or alternatively demonstrating significant improvement in extension after the use of a hand-based splint (PT1 and PT3) were provided with a finger-based circumferential splint. One patient (PT5) who had three fingers affected by DD elected to wear an LMB (North Coast Medical, Morgan Hill, CA) splint in one of the involved fingers.

The degree of active PIP joint extension of involved fingers was used to monitor the progression of the disease as well serve as an outcome measure of the efficacy of this splinting modality. Extension was measured at the time of initial consultation and at variable intervals during follow-up consultations using a stainless-steel finger goniometer (Sammons Preston, Bolingbrook, IL, USA) according to standardized procedures (Ellis and Bruton, 2002; Finn et al., 2008). Measurements were always taken by the same therapist to ensure intra-rater reliability and consistency (Ellis and Bruton, 2002; Flowers and LaStayo, 1994).

The data set was tested for normality and Wilcoxon Signed Ranks Test was used to assess changes in active PIP joint extension measured at the time of initial and last follow-up consultations.

Results

Thirteen patients (19 fingers) with measurable PIPJ flexion contractures were followed by an Occupational Therapist and Plastic Surgeon at Hotel Dieu Hospital in Kingston between April 2007 and August 2010. The demographic and clinical characteristics of the patients are shown in Table 1. The average time between the initial consultation and last follow-up visit was 12.6 months (SD: ± 7.8 ; range: 2–27 months). On average, patients were 69.4 years old (± 5.9 years). There were eight males and five females patients. Four patients (PT6, PT7, PT11 and PT13) showed concomitant flexion contractures of the metacarpophalangeal joint (MCPJ) between 30–45°.

Twelve of the 13 patients demonstrated stability or improvement in active PIPJ extension over the course of the intervention period. Figure 2 summarizes the change in active PIPJ extension for each of the fingers in each of the patients measured at the time of the initial and last follow-up consultations after splinting and tissue mobilization techniques had been instituted. Thirteen fingers demonstrated a general improvement of approximately 14.6° (SD: $\pm 5.1^\circ$; range: 5–25°) (Figure 2). Two fingers revealed no significant changes in PIPJ extension; one of these patients, however, had clear involvement of MCPJ (PT7). In some cases, qualitative changes in the

consistency of the fascial cords associated with DD were observed, there being the impression of softening and volume loss appreciated by both the patient and the observer. Figure 3 shows an example of typical results observed after a few months of non-operative management of PIPJ contractures associated with DD.

One patient (PT 5) was unable to adhere to the treatment protocol. This patient reported the splints to be awkward and uncomfortable, and aggravated a pre-existing sleep disturbance. This patient was unable to pursue alternative strategies even when different splinting options were discussed. It is likely relevant that this patient had diffuse and significant disease with three fingers involved. She demonstrated disease progression over the course of the treatment, with worsening of flexion contractures

and MCPJ involvement (Figure 2). This patient went on to pursue surgical release of contractures, and was subsequently excluded from statistical analyses.

Figure 4 summarizes the average change in active PIPJ extension in thirteen of the patients able to adhere with the treatment protocol. Statistical analyses of 16 fingers in 12 patients showed significant improvement or stabilization in the degree of PIPJ extension between the time of initial consultation and last follow-up visit ($z = -3.334$; $p = .001$).

Discussion

Flexion contracture of the PIPJ due to DD, even at its early stages, has long been considered an absolute indication for surgical fasciectomy (Andrew, 1991; McFarlane, 1993). The same proponents, however,

Table 1. Patient demographics and clinical characteristics

	PT1	PT2	PT3	PT4	PT5	PT6	PT7	PT8	PT9	PT10	PT11	PT12	PT13
Age (years)	73	67	73	72	69	69	55	69	73	72	63	80	66
Gender*	F	F	M	M	F	M	M	M	M	F	M	F	M
Involved fingers	L D5	L D4	L D4	L D4/ D5	L D3/ D4/D5	L D4	R D5	L D5	R D5	R D3/ D5	L D5	RD5	RD3/ D4/D5
MCP involvement**	n	n	n	n	n	y	y	n	n	n	y	n	n
Alternative splints**	y	n	y	n	y	n	n	n	y	n	n	n	n
Follow-up time (months)	22	7	13	19	20	27	7	12	17	9	5	4	2

*F = female; M = male.

**n = no; y = yes.

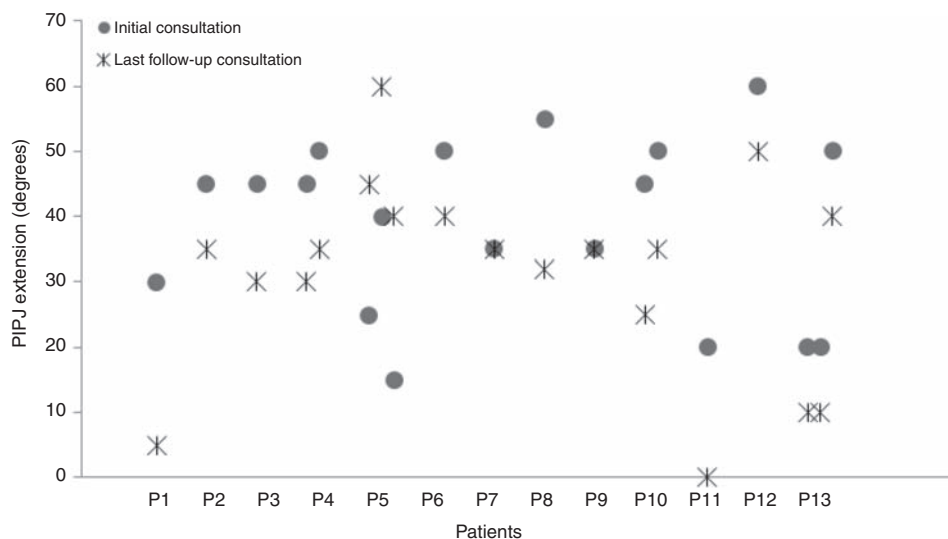


Figure 2. PIPJ extension at the time of initial and last follow-up consultations for all patients (19 fingers).

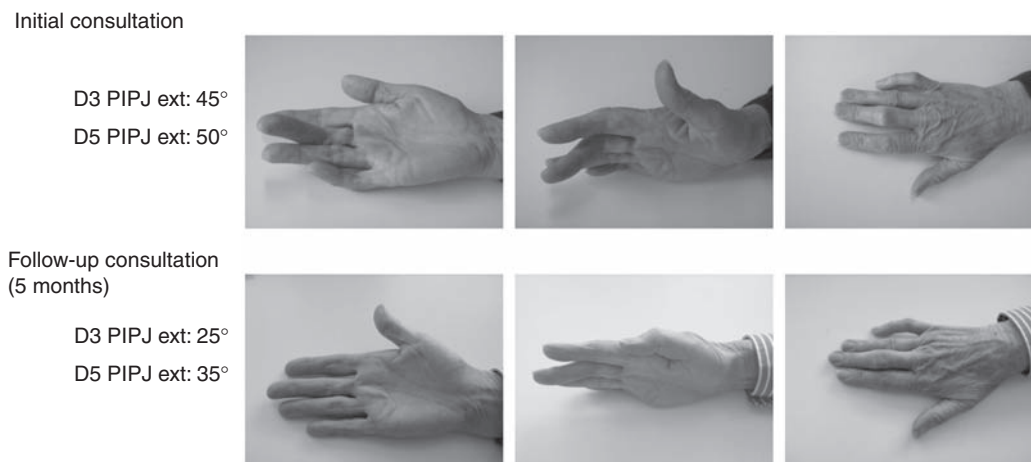


Figure 3. Patient 10 at the time of initial consultation and second follow-up visit.

have recognized that surgery involving the PIPJ in general, and the little finger in particular, can be problematic. The results achieved in our patients demonstrate that in the setting of early onset contracture of the PIPJ due to DD, a relatively simple splinting regimen, combined with stretching exercises and massage to contracted tissue, can stabilize the progression of contracture and in some cases ameliorate the degree of deformity. These observations corroborate and statistically validate those reported by Ball and Nanchahal (2002) in a pilot project on fewer patients followed for a shorter period of time examining the effect of nighttime splinting of flexion contractures associated with early stages of DD. Such a regimen would appear to be an effective

therapeutic modality in delaying or obviating surgical intervention in those with mild to moderate disease involving isolated digits.

There is much in the literature relating to non-surgical management of DD. Almost all, however, involve some form of medical intervention including colchicine (Dominguez-Malagon et al., 1992), allopurinol (Murrel et al., 1987), steroids (Ketchum and Donahue, 2000), and Ca channel blockers (Rayan et al., 1996), administered either systemically or by local injection. Only the use of clostridial collagenase (Badalamente and Hurst, 2007), has shown sustained clinical efficacy in prospective randomized trials. Furthermore these modalities have largely been applied to palmar centric disease with no specific application to isolated contractures of the PIPJ.

The use of external physical forces to address contracted fascia is not an original concept in the management of DD. Elliot (1988) noted that as early as 1826, Boyer had outlined in his important *Traite des Maladies Chirurgicales* that "one can perhaps stop the progression of the disease in its early stages by placing on the dorsum of the finger a small splint fixed with a bandage, and applying lotion and relaxants to the palm of the hand" (Figure 5). More recently the principle of primary splinting in DD has been applied, with the aid of fairly elaborate skeletal traction devices, to people with advanced disease as a precursor to surgical correction to reduce preoperative deformity, especially at the PIPJ, stretching the skin to avert the need for skin grafting or flaps, and gradually elongate the neurovascular structures (Bailey et al., 1994; Brandes et al., 1994; Messina and Messina, 1993). As appreciated in some of the patients in our case series, these studies have also commented on qualitative changes in the clinical consistency of the

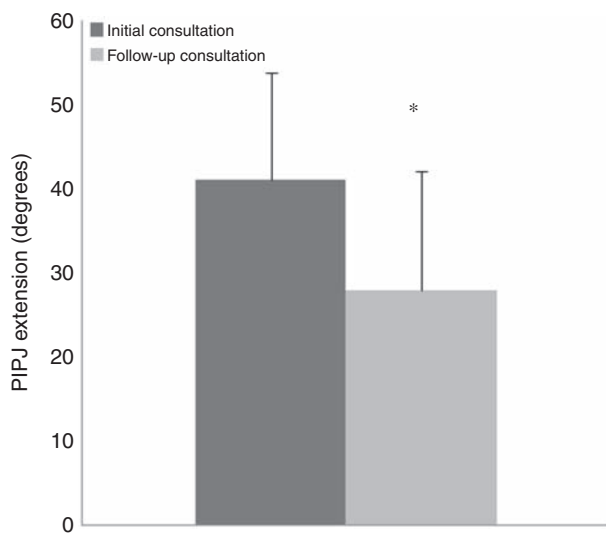


Figure 4. Average PIPJ extension at the time of the initial and last follow-up consultation. * $p < 0.05$.

du tendon et de la peau. Quoi qu'il en soit, on pourrait peut-être arrêter les progrès du mal dans son principe, en plaçant sur la face dorsale du doigt une petite attelle fixée avec une bande, et en appliquant des émolliens et des relâchans sur la paume de la main. Mais comme la flexion

Figure 5. Excerpt from *Traite des Maladies Chirurgicales* recommending splinting and massage to limit progression of contracture in early stages of Dupuytren's (Boyer, 1826).

palpable disease that has been confirmed anatomically by light microscopy as well as biochemically (Bailey et al., 1994).

It nonetheless remains Dupuytren's dogma that splinting is an ineffective treatment modality in managing DD (Townley et al., 2006). This has been reinforced recently by an in vitro study by Bisson et al. (2004) demonstrating in Dupuytren's fibroblasts an abnormal contractile response to tensional loading, consequently questioning the value of splinting, even as a postoperative adjuvant. This and other studies suggest that the rate and degree of tension load may be important determinants of the nature of the cellular and biochemical response by fibroblasts associated with DD. Some have argued that the application of tension load to Dupuytren's related contractures may in fact be counterproductive and may potentially accelerate the progression of deformity (Tarlton et al., 1998; Townley et al., 2006). On the other hand, our results suggest that the application of low load forces for prolonged periods at the end range of contracted tissues can at least delay and potentially reverse (in increments of up to 25°) the progression of PIPJ flexion contractures in DD.

The splinting protocol was maintained throughout the length of the study. It remains to be seen over what time course the stabilization or improvement in the degree of extension can be sustained. Experience using external traction devices applied to fingers with severe contractures suggests prompt recurrence of the deformity within days following the removal of the traction force (Messina and Messina, 1993). We have not yet determined in our series when the splinting can be predictably discontinued. It seems appropriate however to consider some form of long term splinting given the progressive nature of DD.

As is the case for surgery, administering non-surgical modalities also relies on careful patient selection. Occupation, vocation and age are important considerations as are factors relating to the extent and pattern of disease or deformity and the therapeutic goals of the intervention. Such is the case for prescribing a protracted splinting protocol involving frequent and repetitive massage and stretching of

the digits and the consistent use of hand or finger splints to be worn at night. It seems that such protocol is most effective for patients with mild to moderate degrees of contracture isolated to the PIPJ of one or two fingers, who simply wish to maintain their current level of function without having to submit to surgery. The most consistent results in our population were seen in patients with isolated PIPJ flexion contracture that could fully adhere to the splinting regimen. Those with more diffuse presentation of DD, or having difficulty adhering to the proposed treatment showed minimal or no improvement. The one patient in our series who lost ground over the course of the intervention had disease involving three digits and despite fully understanding the rationale of the use of splinting and low load forces was unable to adhere with the regimen.

In summary, this case series suggests that flexion contractures of the PIPJ associated with DD are responsive to the application of prolonged, low load forces. The use of a night time extension splint combined with intermittent stretching exercises and massage to contracted tissue can delay the progression and potentially improve the degree of flexion contractures of the PIPJ. This protocol can be considered an effective alternative management strategy, at least in the short term, for those who may not want or be suitable for other types of interventions, surgical or otherwise. Nevertheless, the time course for the use of a splinting protocol, patient selection, combination with adjuvant therapies and management of treatment failures remain to be determined.

Funding

This research received no specific grant from any funding agency in the public, commercial, or not-for-profit sectors.

The study was performed with the approval of and in accordance with standards outlined by the Ethical Review Board of Queen's University, Kingston, Ontario, Canada.

Conflict of interests

None declared.

References

- Andrew JG. Contracture of the proximal interphalangeal joint in Dupuytren's disease. *J Hand Surg Br.* 1991, 16: 446-8.
- Badalamente MA, Hurst LC. Efficacy and safety of injectable mixed collagenase subtypes in the treatment of Dupuytren's contracture. *J Hand Surg Am.* 2007, 32: 767-74.
- Bailey AJ, Tarlton JF, Van der Stappen J et al. The continuous elongation technique for severe Dupuytren's

- disease. A biochemical mechanism. *J Hand Surg Br.* 1994, 19: 522–7.
- Ball C, Nanchahal J. The Use of splinting as a non-surgical treatment for Dupuytren's Disease: A pilot study. *Br J Hand Ther.* 2002, 7: 76–8.
- Bisson MA, Mudera V, McGrouther DA et al. The contractile properties and responses to tensional loading of Dupuytren's disease-derived fibroblasts are altered: A cause of the contracture? *Plast Reconstr Surg.* 2004, 113: 611–21.
- Boyer A. *Traite des maladies chirurgicales.* Migneret, Paris, 1826, Vol. 11: 55–6.
- Brandes G, Messina A, Reale E. The palmar fascia after treatment by the continuous extension technique for Dupuytren's contracture. *J Hand Surg Br.* 1994, 19: 528–33.
- Cyr LM, Ross RG. How controlled stress affects healing tissues. *J Hand Ther.* 1998, 11: 125–30.
- Denkler K. Surgical complications associated with fasciectomy for Dupuytren's Disease: A 20-year review of the English literature. *Eplasty.* 2010, 10: 116–33.
- Dominguez-Malagon HR, Alfeiran-Ruiz A, Chavarria-Xicotencatl P et al. Clinical and cellular effects of colchicine in fibromatosis. *Cancer.* 1992, 69: 2478–83.
- Elliot D. The early history of contracture of the palmar fascia: Part 1: The origin of the disease: The curse of the MacCrimmons: The hand of benediction: Cline's contracture. *J Hand Surg Br.* 1988, 13: 246–53.
- Ellis B, Bruton A. A study to compare the reliability of composite finger flexion with goniometry for measurement of range of motion in the hand. *Clin Rehabil.* 2002, 16: 562–70.
- Engstrand C, Borén L, Liedberg GM. Evaluation of activity limitation and digital extension in Dupuytren's contracture three months after fasciectomy and hand therapy interventions. *J Hand Ther.* 2009, 22: 21–7.
- Finn NA, Trombly Lathan CA, Podolski CR. Assessing abilities and capacities: Range of motion, strength and endurance. In: Radomski MV, Trombly Lathan CA (eds) *Occupational therapy for physical dysfunction.* Baltimore, Lippincott Williams & Wilkins, 2008: 91–185.
- Flowers KR, LaStayo P. Effect of total end range time on improving passive range of motion. *J Hand Ther.* 1994, 7: 150–7.
- Glasgow C, Wilton J, Tooth J. Optimal daily total end range time for contracture: Resolution in hand splinting. *J Hand Ther.* 2003, 16: 207–18.
- Ketchum LD, Donahue TK. The injection of nodules of Dupuytren's disease with triamcinolone acetonide. *J Hand Surg Am.* 2000, 25: 1157–62.
- McFarlane RM. Dupuytren's contracture. In: Green (ed.) *Operative hand surgery.* 3rd edition. New York: Churchill Livingstone, 1993, Vol. 1, p.563–91.
- McKee P, Morgan L. *Orthotics in rehabilitation.* Toronto: Davis, 1998.
- Messina A, Messina J. The continuous elongation treatment by the TEC device for severe Dupuytren's contracture of the fingers. *Plast Reconstr Surg.* 1993, 92: 84–90.
- Murrell GA, Pilowoki E, Murrell TG. A hypothesis on the resolution of Dupuytren's contractures with allopurinol. *Speculations Sci Technol.* 1987, 10: 117–12.
- Rayan GM, Parizi M, Tomasek JJ. Pharmacologic regulation of Dupuytren's fibroblast contraction in vitro. *J Hand Surg Am.* 1996, 21: 1065–70.
- Schultz-Johnson K. Static progressive splinting. *J Hand Ther.* 2002, 15: 163–78.
- Tarlton JF, Meagher P, Brown RA et al. Mechanical stress in vitro induces increased expression of MMPs 2 and 9 in excised Dupuytren's disease tissue. *J Hand Surg Br.* 1998, 23: 297–302.
- Townley WA, Baker R, Sheppard N, Grobbelaar AO. Dupuytren's unfolded. *BMJ.* 2006, 332: 397–400.
- Weinzwieg N, Culver JE, Fleeger EJ. Severe contractures of the PIP joint in Dupuytren's disease: Combined fasciectomy with capsuloligamentous release versus fasciectomy alone. *Plast Reconstr Surg.* 1996, 97: 560–6.