

Reversing PIP Joint Contractures:

Applicability of the Digit Widget External Fixation System

John M. Agee M.D.



Reversing PIP Joint Contractures:
Applicability of the Digit Widget External Fixation System
John M. Agee, M.D.

Booklet P/N 325000D, 5/12
© 2002-2012, Hand Biomechanics Lab, Inc. All Rights Reserved.
No part of this document may be used or reproduced in any
manner whatsoever without written permission of
John M. Agee, M.D.

Digit Widget is a trademark and hand/arc logo a registered
trademark of Hand Biomechanics Lab, Inc.
United States Patents 6,063,087; 6,565,563; and 6,592,584

Hand Biomechanics Lab, Inc.
77 Scripps Drive, Suite 104
Sacramento, CA 95825
(800) 522-5778
www.handbiolab.com

Table of Contents

Introduction	1
Too Much Flexion Force	
Dupuytren’s Contracture	2
Palmar Descent of the Flexor Tendons	3
Other Flexor Tendon Issues	
Flexor Tendon Adhesions	4
Not Enough Extension Force	
Central Slip Laceration or Rupture	5
Maintenance of Joint Extension	6
Longstanding PIP Joint Contractures	7
Malunited Fractures of the Proximal Phalanx.....	8
Weakness or Paralysis of Intrinsic Muscles	9
Spasticity	9
Adhesions	10
Arthritis	11
The Role that MP Hyperextension Plays	
Development of MP Hyperextension.....	12-13
The Role of the MP Joint	
How Dupuytren’s at the MP Can be Beneficial.....	14
Summary.....	15

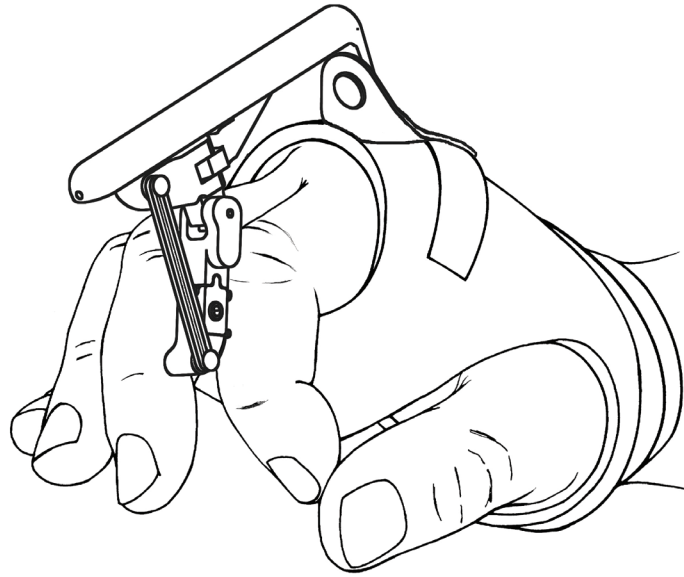


Figure 1: Installed Digit Widget

Introduction

The Digit Widget was developed to reverse severe PIP flexion contractures. It utilizes the basic principle that a gentle force, produced by an extension torque and applied over time, stimulates the growth of contracted soft tissues. As joint motion is progressively lost, the redundant soft tissues necessary for normal motion, shorten rapidly as their soft tissue compliance is lost. If the “mechanical block” to extension is removed or the force imbalance that caused the contracture reversed, the shortened palmar tissues will continue to prevent joint extension. By holding the tissues in a moderately lengthened position for an adequate time, the Digit Widget causes the otherwise normal but shortened palmar tissues to grow.

This is in contrast to noncompliant tissue which may have formed secondary to disease or injury. For example, when the surface of a tendon is disrupted, mechanical stresses frequently cause collagen fibers of a developing tendon adhesion to become oriented in a parallel fashion. These tendon like tissues, rather than responding to the extension torque by lengthening, may instead tend to hypertrophy and shorten. Similarly, a long standing PIP contracture from Dupuytren’s, especially one complicated by scar from previous surgery, frequently contains

“parallel” collagen that is rigid and noncompliant. In contrast, an extension torque applied to the nodules and bands of an evolving Dupuytren’s contracture typically will reverse that contracture.

It is very difficult to determine the etiology of every PIP joint contracture. History, physical exam, X-rays, associated disease, active and passive range of motion measurements and special studies (such as MRI to visualize subluxed flexor tendons) all help formulate a treatment plan optimal for each patient. Currently, there is insufficient data to provide guidelines for the sequencing of Digit Widget contracture reversal with the additional surgery necessary to restore force balance to the joint. The individual hand surgeon’s training and experience, combined with the etiology and pathology of the patient’s contracture, define the staging of each patient’s surgical and hand therapy care.

After the Digit Widget is applied, the need for knowledge of the compliance of the soft tissues does not diminish. Routine monitoring of the response of the contracted soft tissue to the applied force will help identify when noncompliant soft tissue may be limiting joint extension.

Too Much Flexion Force

Dupuytren's Contracture of the PIP Joint

In Dupuytren's contracture, the Digit Widget transmits a tension force into the contracted palmar soft tissues. Although not thought of as compliant, Dupuytren's tissue has been shown to respond favorably to a tension force stimulating longitudinal growth of contracted soft tissues on the palmar side of the joint.

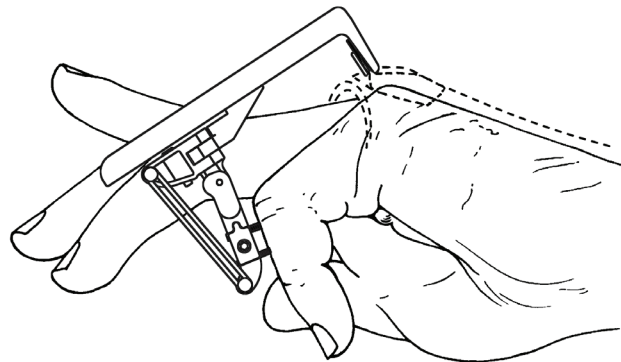


Figure 2

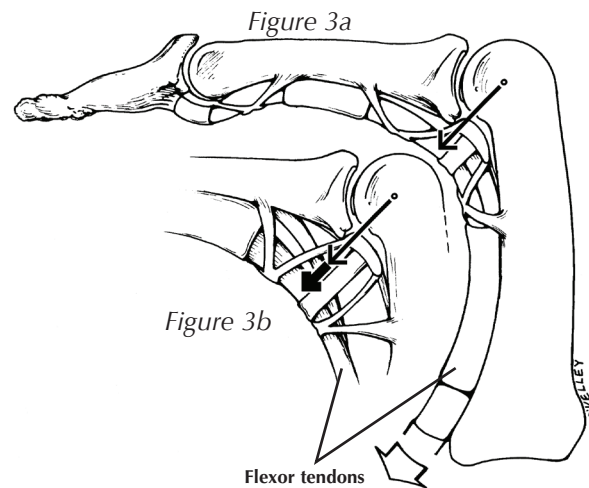
Too Much Flexion Force

Palmar Descent of the Flexor Tendons

Traumatic rupture of the ligaments that suspend the profundus and sublimus palmar to the PIP joint may cause those tendons to sublux. This increases their moment arms for joint flexion thereby overpowering the extensor mechanism. Hemorrhage between these subluxed tendons and the palmar side of the joint creates scar that contracts and forms a progressively more noncompliant tether that resists joint extension. This tether and the increased torque from tendon subluxation can prevent the Digit Widget from restoring joint extension. Because this force imbalance is significant, even if the device is initially successful, once the extension force is removed, the joint contracture will likely recur.

Long standing PIP contractures from various etiologies may produce “stretching” of these pulleys thereby creating increased flexion torque on the joint. This palmar translation of the flexor tendons may be evident by physical exam. It can be imaged using MRI.

Normal profundus tendon moment arm depicted in *Figure 3a*. Increased profundus moment arm depicted in *Figure 3b*.

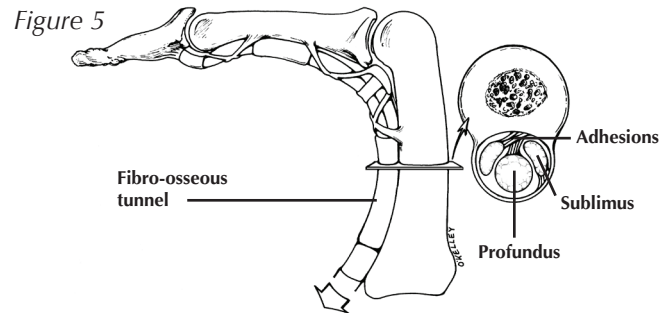
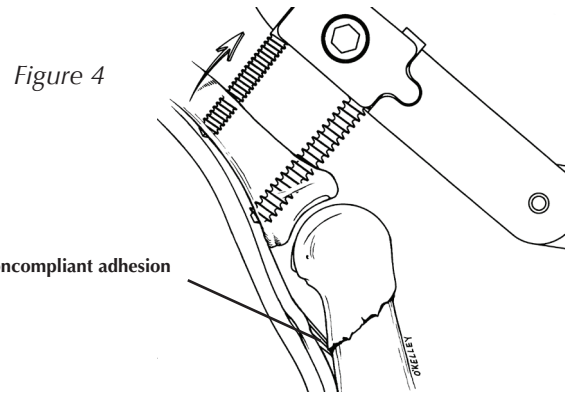


Other Flexor Tendon Issues

Flexor Tendon Adhesions

Injury to the flexor tendons, especially those adjacent to phalangeal fractures may cause adhesions between the tendons and their fibro-osseous tunnel. As depicted in *Figure 4*, noncompliant adhesions proximal to the PIP joint may limit or prevent the Digit Widget from restoring joint extension.

In *Figure 5*, note that different tendon adhesions occur in the fibro-osseous tunnel. Although each, as depicted artistically, should have characteristic physical findings, differentiating sublimus from profundus adhesions may be difficult. The more rigid and noncompliant adhesions may require surgical division before the device can reverse the contracture.



Not Enough Extension Force

Central Slip Laceration or Rupture (Boutonniere Deformity)

When this deformity develops, the central slip retracts proximally as the joint progressively flexes and the lateral bands descend. When the palmar soft tissue contracture is not complicated by rigid scar, the Digit Widget can return the joint to full extension with simultaneous return of the lateral bands to their normal position. Contracture reversal must be followed by maintenance of a joint extended position with concomitant surgical repair of the central slip if needed.

Figure 6a

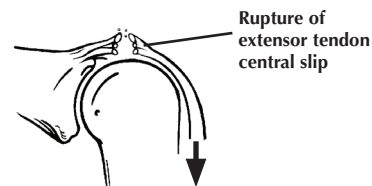
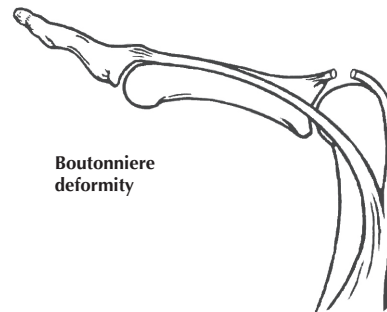


Figure 6b



Not Enough Extension Force

Maintenance of Joint Extension

Prolonged extension splinting at the PIP joint combined with active flexion exercises for the DIP joint is thought to draw the lateral bands distally and dorsally and helps to rebalance the length relationships between the central slip and the lateral bands. A combined exercise and extension splinting program should be maintained for a minimum of 2-3 months and often much longer to prevent recurrence¹.

Prolonged extension splinting is effective in patients where it is believed that the central slip can be “reconstituted” through conservative treatment. In these cases, once contracture reversal has been achieved, the Digit Widget can be used to maintain PIP joint extension by placing 3-4 heavy elastic bands on the posts. Be aware that when the connector assembly is detached from the cuff, the PIP joint will be allowed to flex. If the patient removes the cuff for short periods each day for bathing, this should not be a detriment to their recovery if they do not actively or passively force the PIP joint into flexion.

In very long-standing contractures, surgical reconstruction of the central slip may be indicated once PIP joint extension is achieved.

¹Green, David P., Hotchkiss, Robert N., and Pederson, William C., eds. 1999. *Green's Operative Hand Surgery*. Fourth Edition. Philadelphia: Churchill Livingstone: Volume 2: 2010.

Not Enough Extension Force

Long Standing PIP Joint Contractures

In long standing PIP contractures, the lateral bands may become “stuck” in a palmar position. This may occur in Dupuytren’s and other diseases with or without prior surgery. Restoration of extension requires return of the lateral bands to a position dorsal to the axis of joint rotation.

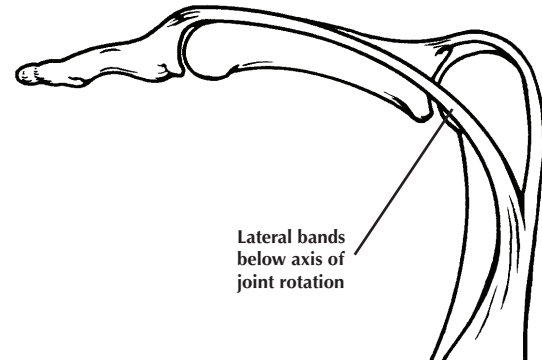


Figure 7

Not Enough Extension Force

Malunited Fractures of the Proximal Phalanx

Malunited fractures of the proximal phalanx are typically shortened on the dorsal side. This dorsal shortening renders the extensor mechanism and its central slip incompetent to extend the PIP joint. Restoration of joint extension requires reversal of the joint contracture and restoration of the geometry and length of the proximal phalanx close to anatomically normal.

The illustration depicts a shortened proximal phalanx and the lax incompetent extensor tendon. Restoring anatomical length to the proximal phalanx restores competence of the central slip to extend the joint. If the bone is not restored to anatomical length, the flexion contracture will recur.

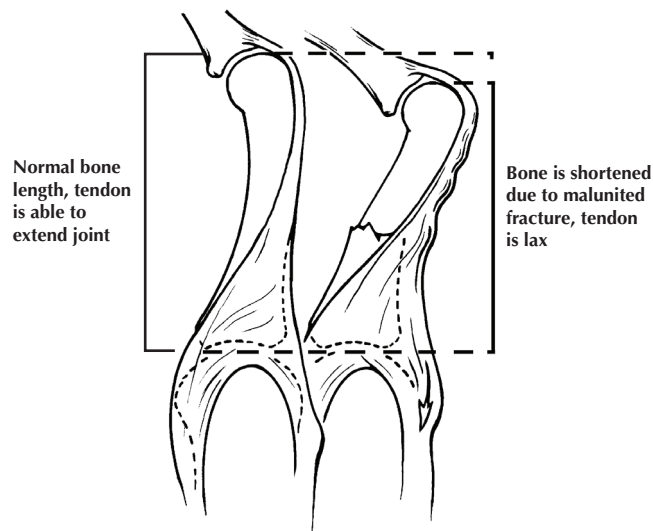


Figure 8

Not Enough Extension Force

Weakness or Paralysis of Intrinsic Muscles

Spasticity

Ulnar nerve palsy creates clawing of the fingers with secondary flexion contractures of the PIP joints. Restoration of joint extension is complex and requires:

1. Reversal of the flexion contracture using the Digit Widget.
2. Clinical demonstration of a competent extensor central slip to the PIP joint following restoration of joint extension or, if incompetent, surgically reconstructing the central slip.
3. Prior recovery of intrinsic muscle function or tendon transfer operation to reconstruct intrinsic muscle function.

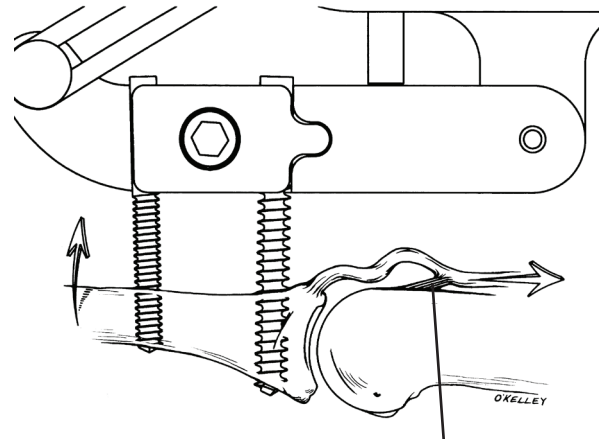
Spastic flexor muscles from conditions such as cerebral palsy or stroke create finger flexion contractures that cannot be reversed by the Digit Widget.

Not Enough Extension Force

Adhesions

Extensor adhesions proximal to the PIP joint prevent the extensor mechanism from gliding over the proximal phalanx. Successful reversal of the flexion contracture using extension torque will be followed by recurrent joint flexion and contracture unless the extensor tendon adhesions are diagnosed and released surgically.

Note extensor tendon laxity distal to the adhesion prevents force transmission needed for active joint extension.



Adhesions between extensor tendon and bone preventing active extension

Figure 9

Not Enough Extension Force

Arthritis of the Joint Surface with Loss of Gliding Motion

Figure 10 depicts advanced joint surface incongruity secondary to a prior dorsal fracture dislocation. Active joint range of motion is limited as the joint toggles from flexion (dotted line) to extension. Limited joint motion occurs in this rocking fashion as the apex of the degenerate joint surface distally rocks on an ulcer created by pressure into the head of the proximal phalanx.

Extensor torque from the external fixator is impotent in the presence of this non gliding joint. As depicted in *Figure 11*, the Digit Widget forces the dorsal base of the middle phalanx into the condyle of the proximal phalanx as the palm side of the joint opens like a book. Evident in joints damaged by prior fractures, similar mechanisms of abnormal joint motion prevent many stiff arthritic joints from enjoying a permanent increase in range of motion following Digit Widget treatment.

Figure 10

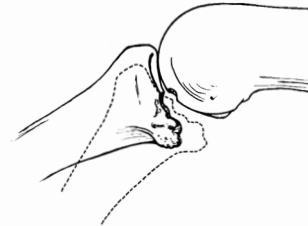
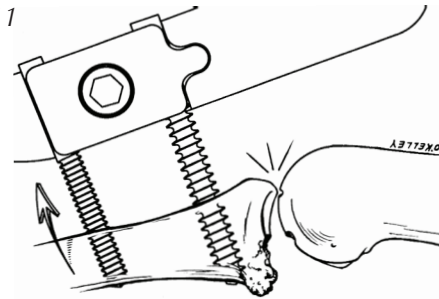


Figure 11



The Role of MP Hyperextension

Development of MP Hyperextension

As the angular degree of each PIP flexion contracture increases, an extension torque is created for its MP joint. This force imbalance is created as PIP flexion pulls the extensor hood mechanism distally, thereby creating increased torque to extend the MP. On the flexor side of the finger, resting tension in the profundus and sublimus tendons is incrementally reduced by their proximal translation to create a decrease in flexion torque on the palm side of the MP joint. This simple model of increased extension and reduced flexion torques at the finger's MP joint reveals how a PIP contracture creates a torque imbalance for its MP joint, favoring extension.

As depicted in *Figure 12*, a PIP flexion contracture creates an extension torque for its MP joint by pulling the extensor hood mechanism distally (A to B), creating increased torque to extend the MP (C). In addition, the resting tension in the profundus and sublimus tendons is reduced by their proximal translation (D to E), creating a decrease in flexion torque on the palm side the MP joint. Therefore, a PIP flexion contracture creates a torque imbalance that favors extension of its MP joint.†

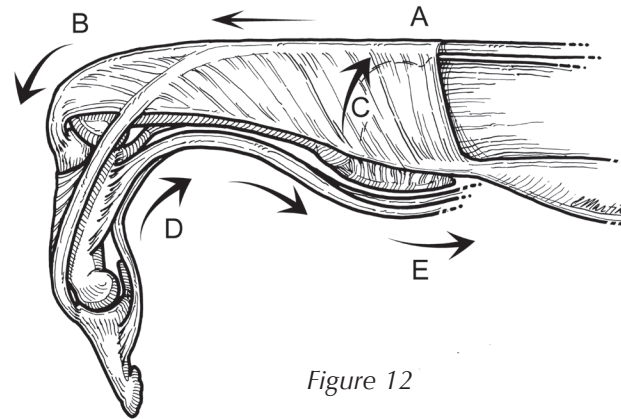


Figure 12

The Role of MP Hyperextension

Development of MP Hyperextension

The progression of MP hyperextension is shown in *Figure 13*. As compliant palmar tissues enable the MP joint to hyperextend, the extensor tendon gradually lifts off the dorsal side of the metacarpal head to increase its moment arm (F) and create additional torque for MP hyperextension. Dorsal displacement of the extensor tendon at the level of the MP joint tightens the transverse fibers of its extensor hood mechanism (G), limiting the proximal excursion of the extensor tendon and its central slip that are required for PIP extension.[†]

This tendency of the finger's PIP and MP joints to become clawlike is greater on the little and ring fingers, because their CMC joints have an arc of active motion. In contrast, the absence of CMC motion of the middle and index fingers decreases the fingers' tendency to collapse into a claw. This explains, in part, why the worst Dupuytren contractures occur on the ulnar two fingers.

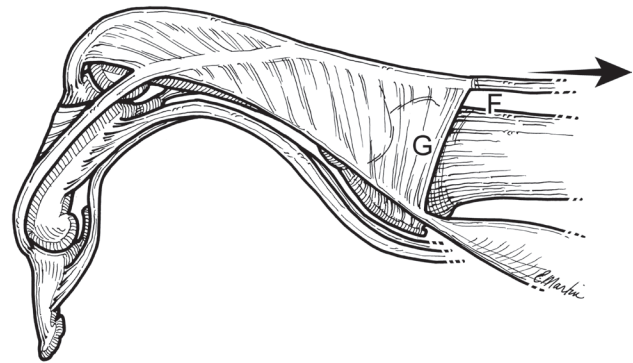


Figure 13

The Role of the MP Joint

How Dupuytren's at the MP Can be Beneficial

Figure 14 illustrates that, although advanced degrees of an MP flexion contracture may complicate surgery for Dupuytren disease, just enough contracture or the addition of a splint to prevent MP hyperextension (H) actually enhances distal transmission of tension forces (I) across the MP to extend the PIP. Restoring central slip tension and excursion are the two critical issues in obtaining and maintaining active PIP joint extension after reversal of the PIP contracture.[†]

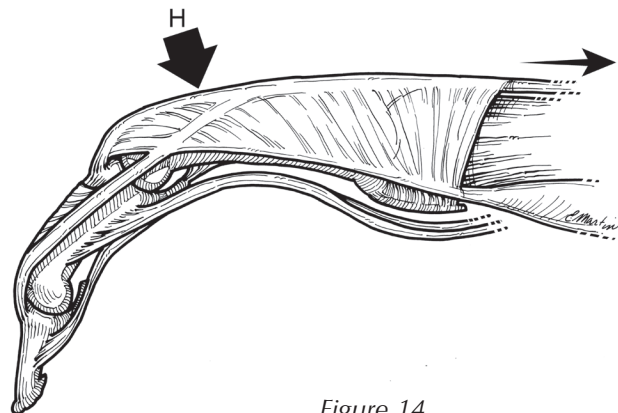


Figure 14

[†] Agee J, Goss B. The Use of Skeletal Extension Torque in Reversing Dupuytren Contractures of the Proximal Interphalangeal Joint. *J Hand Surg*, 2012;37:1467-1474.

Summary

An extension torque transmitted by skeletal pins will typically reverse the PIP contracture. However, it is difficult to maintain what appears to be a notable improvement in active PIP extension if its flexor profundus and sublimis have gained a larger lever arm than normal, by the pulley's or joint capsule's prior injury or surgical release.

The etiology of most persistent or recurrent PIP contractures can be traced to our incomplete preoperative understanding of the force imbalance that created the contracture.