

Hypertrophic Scarring and Keloids: Pathomechanisms and Current and Emerging Treatment Strategies

Gerd G Gauglitz,^{1,2} Hans C Korting,¹ Tatiana Pavicic,¹ Thomas Ruzicka,¹ and Marc G Jeschke^{2,3,4,5}

¹Department of Dermatology and Allergology, Ludwig Maximilians University, Munich, Germany; ²Shriners Hospitals for Children, Department of Surgery, University Texas Medical Branch, Galveston, Texas, United States of America; ³Ross Tilley Burn Centre and ⁴Sunnybrook Research Institute, Sunnybrook Health Sciences Centre, Toronto, Ontario, Canada; and ⁵Department of Surgery, Division of Plastic Surgery, University of Toronto, Toronto, Ontario, Canada

Excessive scars form as a result of aberrations of physiologic wound healing and may arise following any insult to the deep dermis. By causing pain, pruritus and contractures, excessive scarring significantly affects the patient's quality of life, both physically and psychologically. Multiple studies on hypertrophic scar and keloid formation have been conducted for decades and have led to a plethora of therapeutic strategies to prevent or attenuate excessive scar formation. However, most therapeutic approaches remain clinically unsatisfactory, most likely owing to poor understanding of the complex mechanisms underlying the processes of scarring and wound contraction. In this review we summarize the current understanding of the pathophysiology underlying keloid and hypertrophic scar formation and discuss established treatments and novel therapeutic strategies.

© 2011 The Feinstein Institute for Medical Research, www.feinsteininstitute.org

Online address: <http://www.molmed.org>

doi: 10.2119/molmed.2009.00153

INTRODUCTION

A total of 100 million patients develop scars in the developed world alone each year as a result of 55 million elective operations and 25 million operations after trauma (1). Excessive scars form as a result of aberrations of physiologic wound healing and may develop following any insult to the deep dermis, including burn injury, lacerations, abrasions, surgery, piercings and vaccinations. By causing pruritus, pain and contractures, excessive scarring can dramatically affect a patient's quality of life, both physically and psychologically.

Excessive scarring was first described in the Smith papyrus about 1700 BC (2). Many years later Mancini (in 1962) and Peacock (in 1970) differentiated excessive scarring into hypertrophic and keloid scar formation. Per their definition, both scar types rise above skin level, but while hypertrophic scars do not extend beyond

the initial site of injury, keloids typically project beyond the original wound margins (3,4). Nevertheless, clinical differentiation between hypertrophic scars and keloids can be problematic. Incorrect identification of scar type may result in inappropriate management of pathologic scar formation, and occasionally contribute to inappropriate decision making related to elective or cosmetic surgery (5).

Although there are clinical similarities between hypertrophic scars and keloids, there are some clinical, histological and epidemiological differences (Table 1 and Figure 1) that indicate that these entities may be distinct from one another (5,6).

HYPERTROPHIC SCARS VERSUS KELOIDS

Clinical Characteristics

Hypertrophic scarring usually occurs within 4 to 8 weeks following wound in-

fection, wound closure with excess tension or other traumatic skin injury (7), has a rapid growth phase for up to 6 months, and then gradually regresses over a period of a few years, eventually leading to flat scars with no further symptoms (8,9). Keloids, in contrast, may develop up to several years after minor injuries and may even form spontaneously on the midchest in the absence of any known injury. Keloids also persist, usually for long periods of time, and do not regress spontaneously (10). Keloids appear as firm, mildly tender, bosselated tumors with a shiny surface and sometimes telangiectasia. The epithelium is thinned and there may be focal areas of ulceration. The color is pink to purple and may be accompanied by hyperpigmentation (11). The borders of the tumor are well demarcated but irregular in outline. A hypertrophic scar has a similar appearance, but is usually linear, if following a surgical scar, or papular or nodular, following inflammatory and ulcerating lesions (12). Both lesions are commonly pruritic, but keloids may even be the source of significant pain and hyperesthesia (7,9).

In the majority of cases, hypertrophic scarring develops in wounds at anatomic

Address correspondence and reprint requests to Marc Jeschke, Sunnybrook Research Institute, Rm D704, 2075 Bayview Avenue, Toronto, Ontario, Canada M4N 3M5. Phone: 416-480-6703; Fax: 416-480-6763; E-mail: marc.jeschke@sunnybrook.ca.

Submitted October 22, 2009; Accepted for publication October 4, 2010; Epub (www.molmed.org) ahead of print October 5, 2010.

Table 1. Hypertrophic scars and keloids: epidemiological, clinical and histological differences.

	Hypertrophic scarring	Keloids
Incidence	40% to 70% following surgery, up to 91% following burn injury Equal in sex distribution with highest incidence in the second to third decade	6% to 16% In African populations
Predilection sites	Shoulders, neck, presternum, knees and ankles Less affected: eyelids, cornea, palms, mucous membranes, genitalia and soles	Anterior chest, shoulders, earlobes, upper arms and cheeks
Time course	Within 4 to 8 weeks following wounding, rapid growth phase for up to 6 months, then regression over a period of a few years Low recurrence rates after excision of the original hypertrophic scar	Within years after minor injuries or spontaneous formation on the midchest in the absence of any known injury. Persistence for long periods of time. No spontaneous regression High recurrence rates following excision
Appearance	Do not extend beyond the initial site of injury	Projects beyond the original wound margins
Histological characteristics	Primarily fine, well-organized, wavy type III collagen bundles oriented parallel to epidermis surface with abundant nodules containing myofibroblasts and plentiful acidic mucopolysaccharide. Proliferating cell nuclear antigen (PCNA)/p53-level/ATP expression low	Disorganized, large, thick, type I and III hypocellular collagen bundles with no nodules or excess myofibroblasts. Poor vascularization with widely scattered dilated blood vessels. PCNA/p53-level/ATP expression high

locations with high tension, such as shoulders, neck, presternum, knees and ankles (9,12,13), whereas anterior chest, shoulders, earlobes, upper arms and

cheeks have a higher predilection for keloid formation. Eyelids, cornea, palms, mucous membranes, genitalia and soles are generally less affected (14). Keloids tend to recur following excision, whereas new hypertrophic scar formation is rare after excision of the original hypertrophic scar (13,15).

Epidemiology

The occurrence of keloids and hypertrophic scars has equal sex distribution and the highest incidence in the second to third decade (17,18). Incidence rates of hypertrophic scarring vary from 40% to 70% following surgery to up to 91% following burn injury, depending on the depth of the wound (19,20). Keloid formation is seen in individuals of all races, except albinos, but dark-skinned individuals have been found to be more susceptible to keloid formation, with an incidence of 6% to 16% in African populations (14,21). The concept of a genetic predisposition to keloids has long been suggested, because patients with keloids often report a positive family history, unlike patients suffering from hypertrophic scarring. Bayat and colleagues (22) compared the profiles of patients of Afro-Caribbean origin with keloid scars at single versus multiple anatomical site and found the latter to be more common in younger age groups and in females. An important finding was that more than 50% of all keloid patients had a positive family history of keloid scarring, and family history was strongly associated with the formation of keloid scars in

Histology

Histologically, both hypertrophic scars and keloids contain an overabundance of dermal collagen. Hypertrophic scars contain primarily type III collagen oriented parallel to the epidermal surface with abundant nodules containing myofibroblasts, large extracellular collagen filaments and plentiful acidic mucopolysaccharides (6). Keloid tissue, in contrast, is mostly composed of disorganized type I and III collagen, containing pale-staining hypocellular collagen bundles with no nodules or excess myofibroblasts (Table 1) (6,16). Both scar types demonstrate overproduction of multiple fibroblast proteins, including fibronectin, suggesting either pathological persistence of wound healing signals or a failure of the appropriate downregulation of wound-healing cells (16).

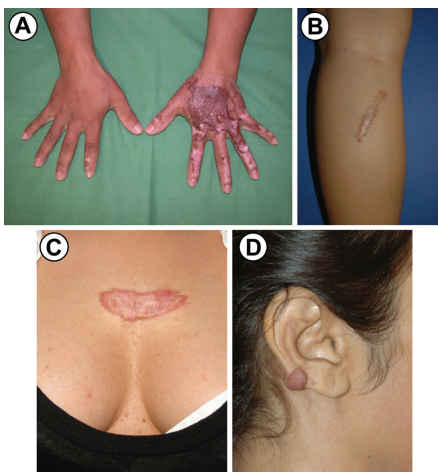


Figure 1. Clinical appearance of hypertrophic scars and keloids. Development of hypertrophic scars after a scald burn (A); hypertrophic scar on lower leg 4 months after surgical procedure (B); keloid on chest after two minor operations (C); keloid on right ear, no history of trauma (D).

multiple sites as opposed to a single anatomical site. Marneros and colleagues (23) studied two families with an autosomal-dominant inheritance pattern of keloids and identified linkage to chromosome 7p11 and chromosome 2q23 for the African and Japanese family, respectively. Brown and colleagues (24) found a genetic association between HLA-DRB1*15 status and the risk of developing keloid scarring in white individuals. Also, carriers of HLA-DQA1*0104, DQB1*0501 and DQB1*0503 have been reported to be have an increased risk of developing keloid scarring (24). Keloid growth may also be stimulated by various hormones, as indicated by some studies in which results have suggested a higher incidence of keloid formation during puberty and pregnancy, with a decrease in size after menopause (18,25,26). Also, immunologic associations of keloids have been proposed. A study by Placik and Lewis (27) revealed a direct correlation between the incidence of keloid formation and levels of serum immunoglobulin E, and Smith *et al.* (28) found a higher incidence of allergic symptoms in keloid-afflicted patients compared with individuals with hypertrophic scars, suggesting a possible role of mast cells in the pathophysiology of keloid formation. Other investigators have reported an association between the formation of keloids and blood type A (14,29).

PATHOPHYSIOLOGY OF EXCESSIVE SCAR FORMATION

The physiologic response to wounding in adult tissue is the formation of a scar, a process that can be temporally grouped into three distinct phases (Figure 2): inflammation, proliferation and remodeling (14).

Immediately following wounding, platelet degranulation and activation of the complement and clotting cascades form a fibrin clot for hemostasis, which acts as a scaffold for wound repair (30). Platelet degranulation is responsible for the release and activation of an array of potent cytokines, such as epidermal growth factor (EGF), insulinlike growth

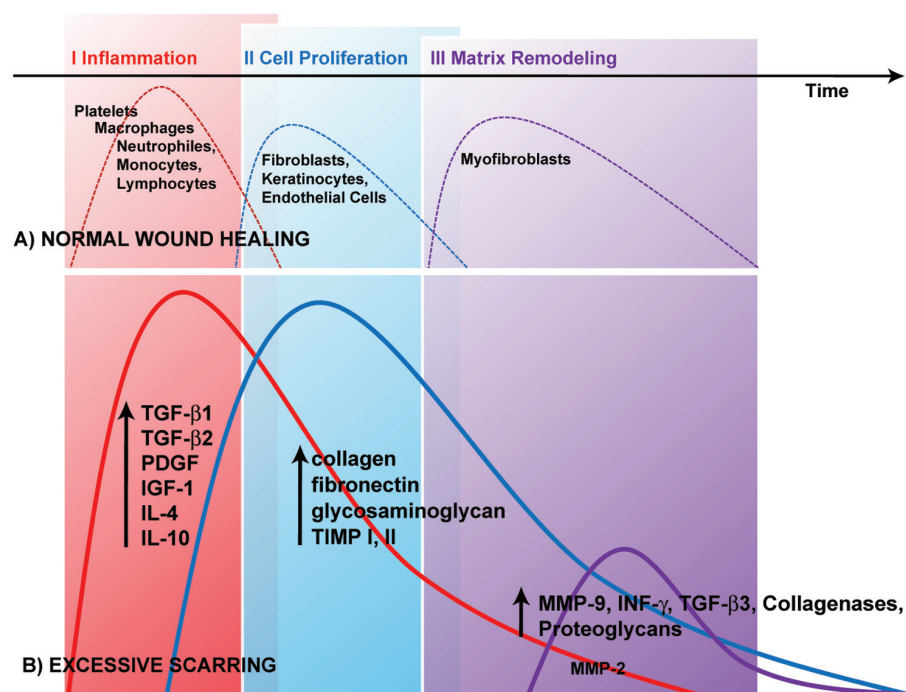


Figure 2. Differences between normal wound healing and excessive scar formation over time. Processes of wound repair follow a specific time sequence and can be temporally grouped into three distinct phases: inflammation (I), proliferation (II) and remodeling (III). Platelet degranulation is responsible for the release and activation of an array of potent cytokines, which serve as chemotactic agents for the recruitment of, for example, macrophages, neutrophils, epithelial cells and fibroblasts. In normal wounds, a balance is achieved between new tissue biosynthesis and degradation mediated by apoptosis and remodeling of ECM (A). During excessive scar formation, a dysfunction of the underlying regulatory mechanisms may lead to persistent inflammation, excessive collagen synthesis or deficient matrix degradation and remodeling (B).

factor (IGF-I), platelet-derived growth factor (PDGF) and transforming growth factor β (TGF- β), which serve as chemotactic agents for the recruitment of neutrophils, macrophages, epithelial cells, mast cells, endothelial cells and fibroblasts (14,30). Within 48 to 72 hours after the initial event, the healing process transitions into the proliferation phase, which may last for up to 3 to 6 weeks (6). Recruited fibroblasts synthesize a scaffold of reparative tissue, the so-called extracellular matrix (ECM). This granulation tissue is made of procollagen, elastin, proteoglycans and hyaluronic acid and forms a structural repair framework to bridge the wound and allow vascular ingrowth (6). Modified fibroblasts, so-called myofibroblasts, which contain actin filaments, help to initiate wound contraction. Once

the wound is closed, the immature scar can transition into the final maturation phase, which may last several months. The abundant ECM is then degraded and the immature type III collagen of the early wound can be modified into mature type I collagen (6).

The transformation of a wound clot into granulation tissue thus requires a delicate balance between ECM protein deposition and degradation, and when this process is disrupted, abnormalities in scarring appear, resulting in either keloid or hypertrophic scar formation.

Both lesions represent aberrations in the fundamental processes of wound healing, in which there is an obvious imbalance between the anabolic and catabolic phases; however, keloids seem to be a more sustained and aggressive fi-

brotic disorder than hypertrophic scars (31). Evidence to date strongly suggests a more prolonged inflammatory period, with immune cell infiltrate present in the scar tissue of keloids, the consequence of which may contribute to increased fibroblast activity with greater and more sustained ECM deposition (31). The elucidation of this process may help to explain why keloid scars spread beyond the margins of the original wound, while hypertrophic scars, in which the immune cell infiltrate decreases over time, remain within the original wound margins and often regress over time. However, only a few published studies on the pathophysiology of keloid and hypertrophic scar formation have included direct comparison of the two entities.

Inflammation

Recent evidence suggests that it is not simply the severity of inflammation that predisposes individuals to hypertrophic and keloid scarring, but also the type of immune response (31). T-helper (Th) CD41 cells have been implicated as major immunoregulators in wound healing. The characteristic cytokine expression profile of the CD41 T cells represents the basis for describing either a predominantly Th1 or Th2 response to a specific or unspecific stimulus (32). While the development of a Th2 response (with production of interleukin [IL]-4, IL-5, IL-10 and IL-13) has been strongly linked to fibrogenesis, a predominance of Th1 CD41 cells has been shown to almost completely attenuate the formation of tissue fibrosis via production of interferon- γ (IFN- γ) and IL-12 (33,34).

Secretion and activation of these mediators during the inflammatory phase of healing are prerequisites for subsequent processes, such as angiogenesis, reepithelialization, recruitment and proliferation of fibroblasts and matrix deposition (30). Angiogenesis is stimulated by endothelial chemoattractants and mitogens such as heparin, fibroblast growth factor (FGF)- β , IL-8 and IGF-I. Wound reepithelialization occurs following the migration

of epithelial cells from the wound margin and epidermal appendages within the wound bed and has been shown to be enhanced by EGF, TGF- α and IGF-I (30). Fibroblast recruitment and proliferation, and production of ECM, as well as inhibition of production of proteases required to maintain the balance between production and degradation, are influenced predominantly by the fibrogenic growth factors PDGF, IGF-I and FGF- β , as well as TGF- β (14).

Fibrogenic Response

Inflammation is not the only critical step in the development of the fibrotic response. One reason for this hypothesis is the failure of current antiinflammatory therapies, even in combination with potent immunosuppressives, to improve outcomes in fibroproliferative diseases such as pulmonary fibrosis (35). Current research thus focuses on direct inhibition of specific fibrogenic events such as cytokine elaboration, fibroblast proliferation and ECM deposition (36). Central to the formation of hypertrophic scar and keloid scar tissue is an alteration of the fibroblast phenotype (36,37). Indeed, when compared with normal fibroblasts, keloid fibroblasts show increased numbers of growth-factor receptors and respond more briskly to growth factors like PDGF and TGF- β , which may upregulate these abnormal cells from the beginning of wound healing (38,39). Using Affymetrix-chip analysis to identify pathways critical to keloid pathogenesis, Smith and colleagues found increased expression of several IGF-binding and IGF-binding-related proteins and decreased expression of a subset of Wnt-pathway inhibitors and multiple IL-1-inducible genes, providing preliminary evidence for epigenetic silencing of a subset of genes in the altered program of keloid fibroblasts (40).

TGF- β . Many of the biologic actions of TGF- β contribute to the normal wound-healing process and have been implicated in a wide variety of fibrotic disorders. Early after injury, high levels of TGF- β are being released from degranu-

lating platelets at the site of injury, where they act as chemoattractants for lymphocytes, fibroblasts, monocytes and neutrophils (41).

The TGF- β family consists of at least five highly conserved polypeptides, with TGF- β 1, - β 2 and - β 3 being the principal mammalian forms. TGF- β 1 and - β 2 are among the most important stimulators of collagen and proteoglycan synthesis, and they affect the ECM not only by stimulating collagen synthesis but also by preventing its breakdown (42,43). In contrast, TGF- β 3, which is predominantly induced in the later stages of wound healing, has been found to reduce connective tissue deposition (44). TGF- β has been linked to hypertrophic scar and keloid formation in a number of ways. Strong and persistent expression of TGF- β and its receptors has been shown in fibroblasts of post-burn hypertrophic scars (45). Also, overexpression of TGF- β 1 and - β 2 has been found in keloid and keloid-derived fibroblasts, with significantly lower TGF- β 3 mRNA expression (46,47). Comparing the expression profiles of TGF- β 1, - β 2 and - β 3 and their receptors in keloids, hypertrophic scar and normal skin derived fibroblasts, Bock and colleagues found significantly lower TGF- β 2 mRNA expression in hypertrophic scar fibroblasts compared with fibroblasts derived from keloids and normal skin, while TGF- β 3 mRNA expression was significantly lower in keloid fibroblasts in comparison with fibroblasts derived from hypertrophic scar and normal skin (44). Thus, specifically, beyond 1 week, differential expression of TGF- β isoforms, receptors and activity modulators, rather than the mere presence or absence of TGF- β , may have a major role in the development of both keloids and hypertrophic scarring (48).

Indeed, antisense phosphorothioate oligonucleotides against TGF- β 1 and - β 2 have been used *in vivo* to significantly reduce postoperative scarring in rabbit and mouse models of glaucoma surgery (49). In two studies, Shah and colleagues (50,51) found that dermal wounds of adult rats healed without scar-tissue for-

mation after injection of a neutralizing antibody to TGF- β 1 and - β 2 into the wound margins, compared with controls.

The SMAD signal-transduction pathway as a downstream mediator of TGF- β action. The SMADs are a family of intracellular regulatory proteins that act downstream of the TGF- β type I receptor in the cell's response to a specific TGF- β (Figure 3). Once these SMADs are phosphorylated, they form a complex with the common mediator Co-SMAD 4. This SMAD complex translocates to the nucleus, where it is recruited to DNA by site-specific inhibitors, activators or coactivators to regulate the transcription of specific genes (52).

SMAD intracellular signaling proteins can be categorized into receptor-regulated SMADs (R-SMADs), common-mediator SMADs, and inhibitory SMADs (53). R-SMADs 3 and 4 have been identified as the predominant mediators of autocrine stimulation by TGF- β in hypertrophic-scar-derived fibroblasts (54). The potential importance of SMAD3 and its relationship with TGF- β in keloid etiology has been demonstrated by Wang *et al.*, who showed that downregulation of SMAD3 expression can significantly decrease procollagen gene expression and reduce ECM deposition by keloid fibroblasts (55). Inhibitory SMAD 7 prevents phosphorylation of R-SMADs by forming stable associations with activated type I TGF- β receptors and thus provides negative feedback to the actions of TGF- β (56). Indeed, a potential therapeutic benefit of SMAD 7 overexpression has already been shown in bleomycin-induced lung fibrosis, postobstructive renal fibrosis and excessive cutaneous scar formation (57–59). SMAD 3 inhibition and SMAD 7 overexpression may thus be potential therapeutic targets to improve excessive scarring.

Interactions between keratinocytes and fibroblasts. Keratinocytes have been shown to mediate the behavior of fibroblasts during wound healing through their secretion, activation or inhibition of growth factors such as TGF- β (32). In particular, the release of IL-1 from keratinocytes at the wound site seems to

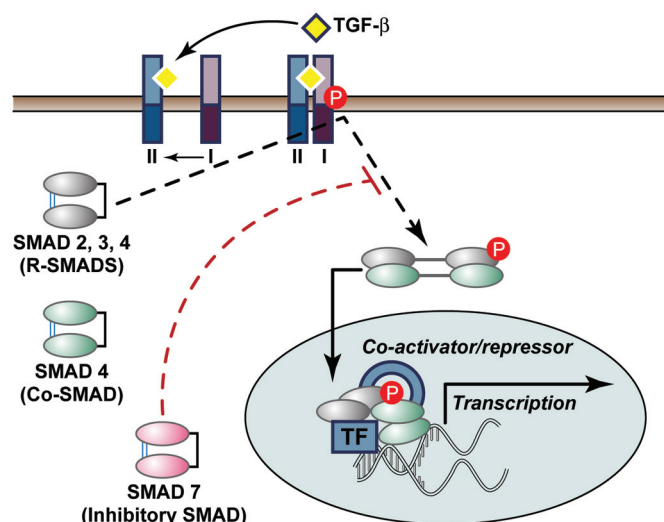


Figure 3. The SMAD signal-transduction pathway as a downstream mediator of TGF- β action. The TGF- β receptor consists of type I and type II subunits that are serine-threonine kinases that signal through the SMAD family of proteins. Binding of TGF- β to its cell-surface receptor type II causes phosphorylation of the type I receptor by type II. The type I receptor is then able to phosphorylate and activate the R-SMAD proteins. Once these SMADs are phosphorylated, they form a complex with the common mediator Co-SMAD 4. This SMAD complex translocates to the nucleus, where the activated SMAD complex recruits other transcription factors (TF) that together activate the expression of target genes mediating the biological effects of TGF- β . Inhibitory SMAD 7 is able to prevent phosphorylation of R-SMADs by forming stable associations with activated type I TGF- β receptors and thus provides negative feedback to the actions of TGF- β .

represent the initial trigger for the inflammatory reaction and serves as an autocrine signal to fibroblasts and endothelial cells, resulting in a pleiotropic effect on them (60,61). Greater thickness of neodermis production was seen in fibroblast-seeded skin models when keratinocytes from hypertrophic scars were added in culture (32). Similar results were detected with coculturing of keloid-derived keratinocytes and fibroblasts (62), suggesting that keratinocytes might have an important role in keloid and hypertrophic scar pathogenesis by producing signals that stimulate the fibroblasts in the underlying dermis to proliferate or produce more ECM. The basis for an inherent abnormality among hypertrophic scar and keloid-derived keratinocytes remains elusive, however.

Mast cells. Our understanding of the role of the mast cell in scar formation is expanding with new discoveries regarding cell-cell communication. Mast cells are an additional leukocyte subset present

in the skin, and they are an important source of a variety of proinflammatory mediators that can promote inflammation and vascular changes (63). Mediated by the release of soluble mediators such as histamine, heparin and cytokines, mast cells have been shown to promote fibroblast proliferation (64). Increased numbers of mast cells have been reported during the active period of hypertrophic and keloid scar formation (28,65). Clinically, the release of histamine by these cells likely contributes to the common patient complaint of itchiness. In addition, the vasodilatory effect of histamine may promote erythema and leakage of plasma proteins into the regional tissues (30).

Matrix Remodeling/Maturation Phase Matrix metalloproteinases (MMPs).

The major effectors of ECM degradation and remodeling belong to a family of structurally related enzymes called MMPs. The MMP family consists of about 25 zinc-dependent and calcium-

dependent proteinases in the mammalian system (66). The levels of MMP expression in normal cells are low and allow healthy connective tissue remodeling. An imbalance in expression of MMPs has been implicated in a number of pathological conditions such as dermal fibrosis (67) and tumor invasion and metastasis (68). In both conditions, cell interactions between either fibroblasts and keratinocytes or fibroblasts and tumor cells result in increased MMP production. In particular, secreted cytokines and growth factors, including IL-1 β , PDGF, EGF and TNF- α , seem to play important roles in controlling the signal mechanism involved in regulation of MMP expression in fibroblasts (69). Several MMPs have been shown to mediate the breakdown of type I and III collagen, the most abundant types of collagen in the skin ECM (66). Specifically, MMP-2 and MMP-9 activity persists after wound closure and seems to play a potent role in the remodeling process (70). Interestingly, hypertrophic scars and keloids were found to have high levels of MMP-2 and low levels of MMP-9 (71). MMP-2 was shown to have major effects on matrix remodeling later in wound healing via degrading denatured collagen, and MMP-9 was found to be typically involved in early wound repair by degrading native types IV and V collagen, elastin and fibronectin (72,73). Also, recent *in vitro* data suggested that MMPs may downregulate inflammation via cleavage of chemokines, which then act as antagonists (74,75).

Decorin. Decorin, a small proteoglycan with one dermatan sulfate sugar chain, is normally prevalent in the dermal ECM. Decorin regulates collagen fibril, fiber and fiber-bundle organization and has been shown to be decreased by about 75% in hypertrophic scars (76). Decorin is able to bind and neutralize TGF- β , thus minimizing the stimulatory effects of this cytokine on collagen, fibronectin and glycosaminoglycan production (32). The low levels of decorin found in hypertrophic scarring may thus account for their irregular collagen organization, as well as increased ECM production (77). Zhang and

colleagues (78) showed similar results, with decorin inhibiting both the basal and TGF- β 1-enhanced contraction of collagen gel by both normal and hypertrophic scar fibroblasts, suggesting that decorin may have therapeutic potential for excessive skin contraction as observed in hypertrophic scarring. Mukhopadhyay and colleagues (79) examined the role of decorin in keloid tissue and found that decorin was able to decrease extracellular matrix proteins, highlighting its importance as an antifibrotic agent.

Apoptosis. Recently, apoptosis has been shown to play a critical role in the transition from granulation tissue into scar formation after tissue injury (43). As described by Amour and others (32), wound epithelialization and scar collagen formation are accompanied by a gradual decrease in cellularity on cross-sectional histology. Early immature hypertrophic scars are hypercellular; and during the process of remodeling and maturing, fibroblast cell density reduces to resemble normal skin, partly due to induction of apoptosis. In particular, apoptosis of myofibroblasts can be detected 12 days after wounding, and is believed to peak on day 20 in normal scar formation (32). In hypertrophic scar tissue of severely burned patients, however, the authors found that maximal apoptosis occurred much later (19–30 months following injury). The percentage of myofibroblasts was also higher in hypertrophic scars compared with normal scars or in normal skin, and was found to correlate with the size of the original burn (80).

Scar maturation. Scar maturation is the least recognized phase in the process of wound healing, and this process is relatively underresearched in regard to the alterations in the clinical and histologic appearance of a scar over time. In a study of incisional scars in patients without any history of excessive scarring, Bond and colleagues (81) found progressive changes in relation to the dermal structure but persistent fibroblastic density at 4 months, indicating the existence of a continuing high-turnover state simi-

lar to the proliferative phase, with subjects younger than 30 years displaying a prolonged longitudinal progression of scar maturation compared with subjects older than 55 years (82). In another study in which they examined the natural history of scar redness and maturation in incisional and excisional wounds, the same authors found that the majority of scars fade at approximately 7 months. These investigators also showed that a considerable proportion of scars displayed persistent redness at 12 months, in the absence of features suggestive of hypertrophic or keloid scarring, and they advocated the term “*rubor perseverans*” to describe the physiologic redness of a normal scar as it matures beyond the first month (82).

CURRENT AND EMERGING TREATMENT STRATEGIES

Multiple studies on hypertrophic scar and keloid formation have led to a plethora of therapeutic strategies to prevent or attenuate keloid and hypertrophic scar formation. In 2002, Mustoe *et al.* published the “international clinical recommendations on scar management,” which serve as an outline for most of the currently published reviews (83). In a recently published work, Durani and Bayat (84) evaluated for the first time primary clinical studies on keloid disease therapy over the last 25 years and levels of evidence for the treatment modalities assigned. These authors concluded that high-quality research in evaluating keloid therapy is still lacking. Within this review we critically discuss the techniques currently used to avoid/treat keloid and hypertrophic scar formation based on our experience from a dermatological and surgical perspective (Table 2).

It is critical to note that generally most of the therapeutic approaches we mention may be used for both hypertrophic scarring and keloids. Nevertheless, clinical differentiation between hypertrophic and keloid scars is of central importance before the initiation of any treatment, particularly before starting any surgical

Table 2. Hypertrophic scars and keloids: current therapeutic strategies.

Treatment	Use	Indications, efficiency and comments
Prophylaxis		
Pressure therapy	Continuous pressure (15–40 mmHg) for at least 23 h/d \geq 6 months of scar healing	<ul style="list-style-type: none"> • Prophylaxis of hypertrophic burn scars, ear keloids (postexcision) • Controversial success • Reduced compliance due to frequent patient discomfort
Silicone gel sheeting	\geq 12 h/d for \geq 2 months beginning 2 weeks after wound healing	<ul style="list-style-type: none"> • Prophylaxis for the development of hypertrophic scars and keloids • No effects on mature keloids and hypertrophic scars
Silicone gel	Twice daily for 2 months beginning 2 weeks after wound closure	
Flavonoids	For example, Contractubex gel (Merz Pharma, Frankfurt, Germany), Mederma Skin Care Gel (Merz Pharmaceuticals, Greensboro, NC, USA). Twice daily for 4 to 6 months beginning 2 weeks after wound closure	<ul style="list-style-type: none"> • Limited to prophylaxis of hypertrophic scar and keloid development
Current therapies		
Corticosteroids	Intralesional injections of TAC (10–40 mg/mL), several treatments once or twice a month	<ul style="list-style-type: none"> • First-line therapy for keloids, second-line therapy for hypertrophic scars • Combination with surgery, PDL and cryotherapy • Common adverse effects: skin and subcutaneous fat atrophy, telangiectasias
Cryotherapy	Contact/spray freezing with liquid nitrogen using 10–20 s freeze-thaw cycles	<ul style="list-style-type: none"> • Overall effective for hypertrophic scars, for keloids combination with triamcinolone acetonide injections recommended • Limited to management of smaller scars • Common adverse effects: blistering and pain
Scar revision	Excision with linear, tension-free closure, split- or full-thickness skin grafting, z-plasty, w-plasty	<ul style="list-style-type: none"> • Efficacious for therapy of hypertrophic scarring • Recurrence rates of 45–100% after keloid excision without adjuvant therapy
Radiotherapy	Superficial x-rays, dosages 15–20 Gy, overall limit 40 Gy. Over 5–6 sessions in the early postoperative period	<ul style="list-style-type: none"> • Overall good efficiency rates of adjuvant radiotherapy after keloid excision • Common adverse effects: potential risk of malignant change/carcinogenesis
Laser therapy	Short-pulsed dye laser (585-nm PDL) with doses ranging from 6.0 to 7.5 J/cm ² (7-mm spot) or from 4.5 to 5.5 J/cm ² (10-mm spot), 2 to 6 treatments every 2 to 6 weeks	<ul style="list-style-type: none"> • Excellent therapeutic option for the treatment of primarily keloids and younger hypertrophic scars • High recurrence rates with other (ablative) laser techniques for the treatment of keloids
Emerging Therapies		
Interferon	Intralesional injection of INF- α 2b (1.5–2 \times 10 ⁶ IU) twice daily over 4 days	<ul style="list-style-type: none"> • Clinical studies report overall effectiveness • Common adverse effects: flu-like symptoms on injection
5-FU	Intralesional injection of 5-FU 50 mg/mL	<ul style="list-style-type: none"> • Overall effective for the treatment of keloids and hypertrophic scars • Common adverse effects: anemia, leucopenia, thrombocytopenia; blood-count monitoring is needed • No therapy in pregnant women or patients with bone marrow suppression

or laser related manipulations as specified below.

Prophylaxis

Prevention of pathologic scarring is undoubtedly more effective than treatment. Thus, avoiding all unnecessary wounds in any patient, whether or not the patient is prone to keloid/hypertrophic scars, remains an obvious but imperfect solution (6). Because delayed epithelialization beyond 10 to 14 days increases the incidence of hypertrophic scarring dramatically (83), achievement of rapid epithelialization is mandatory for avoiding excessive scar formation. In particular, wounds subjected to tension due to motion, body location or loss of tissue are at increased risk of scar hypertrophy and spreading (85). Thus, in case of cutaneous injury, the importance of rapid primary closure of wounds under little to no tension cannot be overstated. It is also crucial to adequately debride contaminated wounds, obtain good hemostasis, handle tissues gently and limit foreign bodies in the form of debris and braided polyfilamentous suture material, such as polyglactin or silk (6).

Pressure therapy. Pressure therapy has been the preferred conservative management for both the prophylaxis and treatment of hypertrophic scars and keloids since the 1970s. Currently, pressure garments are predominantly used for the prophylaxis of hypertrophic burn scar formation, despite controversial data regarding their value in reducing excessive scarring and little scientific evidence supporting their use (5). The mechanism of action of pressure therapy remains poorly understood; however, possible mechanisms are decreased collagen synthesis attributable to limiting of the supply of blood, oxygen and nutrients to the scar tissue (86–88) and increased apoptosis (89).

Recommendations for the amount of pressure and the duration of the therapy are based merely on empirical observations and advocate continuous pressure of 15–40 mmHg for at least 23 hours and/or 1 day for more than 6 months

while the scar is still active (87,90). However, compression therapy is ultimately limited by inability to adequately fit the garment to the wounded area and by patient discomfort, which frequently reduces compliance.

Silicone gel sheeting. Topical silicone gel sheeting has been a well-established treatment for management of scars since its introduction in the early 1980s, and its therapeutic effects on predominantly hypertrophic scars have been well documented in the literature (91,92). Current opinion suggests that occlusion and hydration are likely the mechanisms of the therapeutic action of silicone gel sheeting rather than an inherent antiscarring property of silicone (93). Silicone sheets are recommended to be worn for ≥ 12 hours and/or 1 day for at least 2 months beginning 2 weeks after wound healing. Silicone gel is favored for areas of consistent movement, where sheeting will not conform, and should be applied twice daily (6).

Flavonoids. Flavonoids (quercetin and kaempferol) are found in well-known topical scar creams, such as Mederma skin care gel (Merz Pharmaceuticals, Greensboro, NC, USA) and Contractubex gel (Merz Pharma, Frankfurt, Germany). So far, efficacy studies testing the ultimate benefit of these flavonoid-containing topical scar creams have provided controversial data (94–98). Interestingly however, quercetin, a dietary bioflavonoid, has been recently shown to inhibit fibroblast proliferation, collagen production and contraction of keloid and hypertrophic scar-derived fibroblasts. A study by Phan and others (94) suggested that these inhibitory effects may be mediated through inhibition of the above discussed SMAD 2, 3, and 4 expression by quercetin.

Emerging Prophylactic Approaches

Imiquimod 5% cream. Imiquimod 5% cream, a topical immune-response modifier, is approved for the treatment of genital warts, basal cell carcinoma and actinic keratoses (99). Imiquimod stimulates interferon, a proinflammatory cytokine, which increases collagen break-

down. In addition, imiquimod alters the expression of apoptosis-associated genes (100). Therefore, it has been used in an attempt to reduce keloid recurrence after excision and was reported to have positive effects on the recurrence rate of keloids after postoperative application (101). However, in a prospective, double-blind, placebo-controlled pilot study in which imiquimod 5% cream was applied nightly for 2 weeks before being given 3 times/week under occlusion for 1 month postoperatively, no significant difference in keloid recurrence rates between groups could be detected (102). The role of imiquimod in the prevention of postsurgical keloid recurrence thus remains questionable. In a preliminary, small, randomized, prospective clinical trial, imiquimod was shown to improve hypertrophic scar quality after surgery (103), but additional studies with a larger sample size and longer follow-up are necessary to determine the role of imiquimod 5% cream in hypertrophic scar therapy.

Recombinant TGF- β 3 and mannose-6-phosphate. A recently published milestone study by Ferguson and colleagues (104) on the prophylactic effects of TGF- β 3 on skin scarring has further increased the current interest in the TGF- β family. In three double-blind, placebo-controlled studies, intradermal avotermin (recombinant, active human TGF- β 3 at concentrations ranging from 0.25 to 500 ng/100 μ L per linear centimeter wound margin) was administered to both margins of 1-cm, full-thickness skin incisions before wounding and 24 hours later, in healthy subjects. In both young and old participants, only one dose regimen, 50 ng per 100 μ L per linear centimeter, achieved more than 10% scar improvement in nearly two-thirds of wounds. However, in the final phase II study, each of three doses was judged to be effective by lay observers and by clinicians (105). Although the investigators acknowledged their commercial interests in TGF- β 3, adherence to established standards in this translational investigation and the rigorous nature of the statistical

analysis in a well-powered series of studies provided strong evidence for the benefits of avotermin in this setting.

In March 2009, the company Renovo reported the results of a double-blind, placebo-controlled, randomized phase 2 efficacy trial in 195 male and female subjects to investigate the safety and efficacy of inhibition by TGF- β 1 and - β 2 using two dose levels of mannose-6-phosphate (Juvindex[®], 300 mmol/L and 600 mmol/L) via two routes of administration (intra-dermal and topical in combination and topical alone) in the acceleration of healing of split-thickness skin-graft donor sites. Although the trial did not meet its primary endpoint, which was demonstration of a statistically significant difference in the time to complete wound closure at the skin-graft site as assessed by the investigating physician, it did meet some of the specified secondary endpoints with statistical significance. These included a between-patient comparison performed by an external panel of clinical experts who assessed photographs of the donor sites, where the 300 mmol/L Juvindex topical-alone application versus standard care showed a statistically significant acceleration of healing in favor of Juvindex.

Current Treatment Strategies

Intralesional corticosteroid injections. Since the mid-1960s intralesional steroid injections have gained popularity as one of the most common approaches to attenuate hypertrophic scar and keloid formation (106), while topical administration of corticosteroid-containing creams has been used with only varying success. Most of the known effects of corticosteroids are thought to result primarily from its suppressive effects on the inflammatory process in the wound (93), and secondarily from diminished collagen and glycosaminoglycan synthesis, inhibition of fibroblast growth (107) and enhanced collagen and fibroblast degeneration (108). Two or three injections of triamcinolone acetonide (TAC, 10 to 40 mg/mL) are usually sufficient, although occasionally injections are continued for 6 months or

more (106). Response rates have been highly variable, with figures ranging from 50% to 100%, and a recurrence rate of 9% to 50% (109). An important finding was that intralesional corticosteroid injections, when used alone, have the most effect on younger keloids, which can become completely flattened. In older scars and keloids, corticosteroids can soften and flatten the scars only to some extent and can provide symptomatic relief (5). Injections may be used alone or combined with other therapies (10), of which the combination with cryotherapy or surgery are the most widely used modalities in clinical practice (110). Side effects include dermal atrophy, telangiectasia and pain at the site of injection. The latter can be averted by topical anesthesia and/or regional injections of local anesthetic around the scars to be injected (30). Despite relatively few randomized, prospective studies, TAC remains a first-line therapy for the treatment of early keloids and a second-line therapy for the treatment of early hypertrophic scars if other easier treatments have not been efficacious (83).

Cryotherapy. Cryotherapy has been used as monotherapy and in conjunction with other forms of treatment for excessive scars. In particular, the combination of cryotherapy with intralesional TAC injections seems to yield marked improvement of hypertrophic scars and keloids (111–113). We recommend cryotherapy directly before the administration of intralesional TAC injections, because success rates seem to be increased with this sequence.

Cryotherapy is believed to induce vascular damage that may lead to anoxia and ultimately tissue necrosis (114). Success rates in studies in which contact or spray cryosurgery with liquid nitrogen was used varied between 32% and 74% after two or more sessions, with higher response rates of hypertrophic scars compared with keloids (83,115,116). The usefulness of cryotherapy, however, is limited to the management of small scars. A delay of several weeks between sessions is usually required for postoperative healing, and the commonly occurring

side effects, including permanent hypo- and hyperpigmentation, moderate skin atrophy, blistering and postoperative pain, are major handicaps (5,116). Recently, the intralesional-needle cryoprobe method has been assessed in the treatment of hypertrophic scars and keloids (117), and has been demonstrated to have increased efficacy compared with that obtained with contact/spray probes and shorter reepithelialization periods (117).

Surgical manipulation. Surgical excision remains the traditional treatment for keloids and hypertrophic scars (6). However, it is imperative to clearly differentiate between hypertrophic scars and keloids before starting any surgical manipulations.

In case of hypertrophic scars, timing of surgical treatment is an important consideration in the treatment protocol of strategies for scar revision. Scars mature during a period of at least 1 year and can show decreased contractures along with flattening, softening, and repigmentation without any physical manipulation (93). Surgical excision thus might not be needed, even though postexcisional recurrence rates of the original hypertrophic scar are usually low (13,15).

Recurrence rates of keloids after excision, in contrast, range between 45% and 100% (83). Given this high recurrence rate, surgical intervention without adjuvant therapy, such as postexcisional corticosteroid injections or radiation, should be considered with caution. Excision may frequently result in a longer scar than the original keloid, and recurrence in this new area of trauma may lead to an even larger keloid (109,118). Surgical repair (core excision with low-tension wound closure, or shave excision) of earlobe keloids with corticosteroid injections and postoperative pressure on the incision site, however, usually provides good cosmetic results (119).

Radiotherapy. Superficial x-rays, electron-beam therapy and low- or high-dose-rate brachytherapy have been used with good results in scar reduction protocols, primarily as adjuncts to surgical removal of keloids (120). The effects of

radiation on keloids are thought to be mediated through inhibition of neovascular buds and proliferating fibroblasts, which result in decreased collagen production (93). Electron beam irradiation is usually started 24 to 48 h after keloid excision, and the total dose is limited to 40 Gy over the course of several administrations to prevent side effects such as hypo- and hyperpigmentation, erythema, telangiectasia and atrophy (121). However, because radiation entails a risk of carcinogenesis, particularly in areas such as the breast and thyroid, its use should be handled with caution (5,15).

Laser therapy. Since the introduction of laser treatment for keloids in the mid-1980s (122), the therapeutic use of more and more lasers with different wavelengths has been investigated, and success has varied. Until today, the most encouraging results have been obtained with the 585-nm pulsed-dye laser (PDL), which has been recognized as an excellent therapeutic option for the treatment of younger hypertrophic scars and primarily keloids (123). Nonoverlapping laser pulses at fluences ranging from 6.0 to 7.5 J/cm² (7-mm spot) or from 4.5 to 5.5 J/cm² (10-mm spot) have been recommended for the treatment of hypertrophic scars and keloids (124). Two to six treatments may be necessary to successfully improve scar resolution, including scar color, height, pliability and texture (123). By causing local ischemia via destroying blood vessels, 585-nm PDL therapy is believed to induce neocollagenesis, collagen-fiber heating with dissociation of disulfide bonds and subsequent collagen-fiber realignment, and decreased fibroblast proliferation as well as release of histamine and other factors that influence fibroblast activity (125–127). Adverse effects include transient hyper- or hypopigmentation and blistering (125,128). Hyperpigmentation has been reported with a frequency of 1–24% (129,130). The most common adverse side effect of 585-nm PDL treatment is postoperative purpura, which can persist for 7–10 days.

Emerging Therapies

IFN injections. IFN therapy, which has potential therapeutic benefit in the treatment of abnormal scars, is based on the effect of IFN in decreasing the synthesis of collagen types I and III (15,131). Specifically, IFN- α 2b has been proposed to have antiproliferative properties, and it may improve the pathologic features of dermal fibrosis directly or by antagonizing the effects of TGF- β and histamine (132). *In vivo*, systemic administration of IFN- α 2b in severely burned patients resulted in improved clinical appearance of the hypertrophic scars and a lower Vancouver Burn Scar Assessment score (133). IFN- α 2b administered intralesionally (1.5×10^6 IU, given twice daily over 4 days) was found to result in a 50% reduction of keloid size by 9 days and thus was much more effective than intralesionally injected corticosteroid (132). Hypertrophic scars injected three times weekly with IFN- α 2b showed significant mean rates of improvement and sustained reduced serum TGF- β levels (134). Unfortunately, adverse effects are common with IFN treatment and include flu-like symptoms and pain on injection (15). Although IFN is an expensive form of therapy, it remains a promising therapeutic approach in the management of excessive scars.

Bleomycin. Bleomycin sulfate, another antineoplastic agent that was found to directly inhibit collagen synthesis via decreased stimulation by TGF- β 1 (135), was first investigated in the mid-1990s as a scar-reducing agent (136). After administering three to five intralesional injections of bleomycin within a 1-month period, the authors observed complete regression in 69.4% of the keloids. Subsequent studies revealed similar results, with significant improvement in hypertrophic scar and keloid height and pliability as well as reduction in erythema, pruritus and pain (135,137,138). Occasionally, development of hyperpigmentation and dermal atrophy may occur with bleomycin treatment. Because of bleomycin's toxic-

ity, clinicians are encouraged to be aware of associated potential problems. However, systemic toxic effects of intralesionally administered bleomycin seem to be uncommon (15). Bleomycin may thus be a promising agent for the therapy of keloids and hypertrophic scars; however, further investigation and efficacy trials are needed before this agent is included in future treatment protocols.

5-Fluorouracil (5-FU). 5-FU is a pyrimidine analog that is used as an antimetabolite in cancer chemotherapy (109). 5-FU is converted intracellularly to its active version, which was suggested to directly increase fibroblast apoptosis via inhibiting DNA synthesis preferentially in rapidly proliferating and metabolizing cells (58,139). In 1999, Fitzpatrick (140) was the first to report the use of 5-FU to effectively reduce scars during his 9-year experience, in which he administered more than 5000 injections to more than 1000 patients. Ever since, the use of intralesional 5-FU in combination or as a sole agent for treatment of keloids has been shown to be effective. In a prospective, randomized trial including 28 consecutive patients with keloids of varying size and duration, weekly intralesional 5-FU injections (50 mg/mL) for 12 weeks resulted in reduction in scar size of at least 50% in the majority of the patients, with no patient showing failure to respond to therapy or recurrence of symptoms within the follow-up period of 24 months (141). Adverse side effects included pain, ulceration and burning sensations. Intralesional 5-FU treatment has also been used for the treatment of inflamed hypertrophic scars and seems to be both effective and safe (140).

CONCLUSIONS

Scarring following surgery or injury is difficult to predict, and both physicians and their patients are highly concerned with minimizing scar appearance and value as clinically meaningful even small improvements in scarring. Despite a plethora of various *in vivo* and *in vitro*

studies, to date only limited information is available on the exact cause of hypertrophic scar and keloid formation. Knowledge of the cellular and molecular mechanisms implicated in the development of these fibroproliferative disorders remains relatively poor because of the lack of representative and well-recognized animal models of human hypertrophic scar formation. Instead, scar tissue for study is usually obtained from humans undergoing scar revision—usually months after the scar first developed. Therefore, early alterations in wound repair mechanisms that likely determine the development of hypertrophic scars may be missed.

Existing prophylactic and therapeutic strategies include pressure therapy, silicone gel sheeting, intralesional TAC, cryosurgery, radiation, laser therapy, INF, 5-FU and surgical excision as well as a multitude of extracts and topical agents. Many of these treatments have been proven to be effective through extensive use, but few have been supported by well-designed prospective studies with adequate control groups.

Emerging therapies for patients prone to excessive scars support earlier interventions aimed at modulating single cell types, inflammatory metabolites, cytokines or signaling receptors. Encouraging results obtained with the use of recombinant human TGF- β 3 and anti-TGF- β 1 and - β 2 support substantial optimism regarding the future discovery of new solutions to difficult fibrotic disorders.

DISCLOSURE

The authors declare that they have no competing interests as defined by *Molecular Medicine*, or other interests that might be perceived to influence the results and discussion reported in this paper.

REFERENCES

- Sund B. (2000) *New Developments in Wound Care*. PJB Publications, London, pp. 1–255.
- Berman B, Bielely HC. (1995) Keloids. *J. Am. Acad. Dermatol.* 33:117–23.
- Peacock EE Jr, Madden JW, Trier WC. (1970) Biologic basis for the treatment of keloids and hypertrophic scars. *South. Med. J.* 63:755–60.
- Mancini RE, Quaipe JV. (1962) Histogenesis of experimentally produced keloids. *J. Invest. Dermatol.* 38:143–81.
- Atiyeh BS. (2007) Nonsurgical management of hypertrophic scars: evidence-based therapies, standard practices, and emerging methods. *Aesthetic. Plast. Surg.* 31:468–94.
- Slemp AE, Kirschner RE. (2006) Keloids and scars: a review of keloids and scars, their pathogenesis, risk factors, and management. *Curr. Opin. Pediatr.* 18:396–402.
- Wheeland RG. (1996) Keloids and hypertrophic scars. In: *Cutaneous Medicine and Surgery*. Arndt KA, Robinson JK, Leboit PE, Wintroub BU (eds.). Saunders Elsevier, Philadelphia, pp. 900–5.
- Alster TS, West TB. (1997) Treatment of scars: a review. *Ann. Plast. Surg.* 39:418–32.
- Hawkins HK. (2007) Pathophysiology of the burn scar. In: *Total Burn Care*. Herndon DN (ed.). Saunders Elsevier, Philadelphia, pp. 608–19.
- Murray JC. (1994) Keloids and hypertrophic scars. *Clin. Dermatol.* 12:27–37.
- Al-Attar A, et al. (2006) Keloid pathogenesis and treatment. *Plast. Reconstr. Surg.* 117:286–300.
- From L, Assad D. (1993) Neoplasms, pseudoneoplasms, and hyperplasia of supporting tissue origin. In: *Dermatology in General Medicine*. Jeffers JD, Englis MR (eds.). McGraw-Hill, New York, pp. 1198–99.
- Muir IF. (1990) On the nature of keloid and hypertrophic scars. *Br. J. Plast. Surg.* 43:61–9.
- Niessen FB, Spauwen PH, Schalkwijk J, Kon M. (1999) On the nature of hypertrophic scars and keloids: a review. *Plast. Reconstr. Surg.* 104:1435–58.
- Leventhal D, Furr M, Reiter D. (2006) Treatment of keloids and hypertrophic scars: a meta-analysis and review of the literature. *Arch. Facial. Plast. Surg.* 8:362–8.
- Sephel GC, Woodward SC. (2001) Repair, regeneration, and fibrosis. In: *Rubin's Pathology*. Rubin E (ed.). Lippincott, Williams & Wilkins, Baltimore, pp. 84–117.
- Oluwasanmi JO. (1974) Keloids in the African. *Clin. Plast. Surg.* 1:179–95.
- Moustafa MF, Abdel-Fattah MA, Abdel-Fattah DC. (1975) Presumptive evidence of the effect of pregnancy estrogens on keloid growth: case report. *Plast. Reconstr. Surg.* 56:450–3.
- Deitch EA, et al. (1983) Hypertrophic burn scars: analysis of variables. *J. Trauma.* 23:895–8.
- Lewis WH, Sun KK. (1990) Hypertrophic scar: a genetic hypothesis. *Burns.* 16:176–8.
- Murray CJ, Pinnel SR. (1992) Keloids and excessive dermal scarring. In: *Woundhealing, Biochemical and Clinical Aspects*. Cohen IK, Diegelmann RF, Lindblad WJ (eds.). Saunders Elsevier, Philadelphia, pp. 500–9.
- Bayat A, et al. (2005) Keloid disease: clinical relevance of single versus multiple site scars. *Br. J. Plast. Surg.* 58:28–37.
- Marneros AG, et al. (2004) Genome scans provide evidence for keloid susceptibility loci on chromosomes 2q23 and 7p11. *J. Invest. Dermatol.* 122:1126–32.
- Brown JJ, Ollier WE, Thomson W, Bayat A. (2008) Positive association of HLA-DRB1*15 with keloid disease in Caucasians. *Int. J. Immunogenet.* 35:303–7.
- Ford LC, King DF, Lagasse LD, Newcomer V. (1983) Increased androgen binding in keloids: a preliminary communication. *J. Dermatol. Surg. Oncol.* 9:545–7.
- Schierle HP, Scholz D, Lemperle G. (1997) Elevated levels of testosterone receptors in keloid tissue: an experimental investigation. *Plast. Reconstr. Surg.* 100:390–6.
- Placik OJ, Lewis VL Jr. (1992) Immunologic associations of keloids. *Surg. Gynecol. Obstet.* 175:185–93.
- Smith CJ, Smith JC, Finn MC. (1987) The possible role of mast cells (allergy) in the production of keloid and hypertrophic scarring. *J. Burn Care Rehabil.* 8:126–31.
- Ramakrishnan KM, Thomas KP, Sundararajan CR. (1974) Study of 1,000 patients with keloids in South India. *Plast. Reconstr. Surg.* 53:276–80.
- Tredget EE, Nedelec B, Scott PG, Ghahary A. (1997) Hypertrophic scars, keloids, and contractures: the cellular and molecular basis for therapy. *Surg. Clin. North Am.* 77:701–30.
- Brown JJ, Bayat A. (2009) Genetic susceptibility to raised dermal scarring. *Br. J. Dermatol.* 161:8–18.
- Armour A, Scott PG, Tredget EE. (2007) Cellular and molecular pathology of HTS: basis for treatment. *Wound Repair Regen.* 15 Suppl 1:S6–17.
- Wynn TA. (2004) Fibrotic disease and the T(H)1/T(H)2 paradigm. *Nat. Rev. Immunol.* 4:583–94.
- Doucet C, et al. (1998) Interleukin (IL) 4 and IL-13 act on human lung fibroblasts. Implication in asthma. *J. Clin. Invest.* 101:2129–39.
- Kamp DW. (2003) Idiopathic pulmonary fibrosis: the inflammation hypothesis revisited. *Chest.* 124:1187–90.
- Ladak A, Tredget EE. (2009) Pathophysiology and management of the burn scar. *Clin. Plast. Surg.* 36:661–74.
- Butler PD, Longaker MT, Yang GP. (2008) Current progress in keloid research and treatment. *J. Am. Coll. Surg.* 206:731–41.
- Ishihara H, et al. (2000) Keloid fibroblasts resist ceramide-induced apoptosis by overexpression of insulin-like growth factor I receptor. *J. Invest. Dermatol.* 115:1065–71.
- Tuan TL, Nichter LS. (1998) The molecular basis of keloid and hypertrophic scar formation. *Mol. Med. Today.* 4:19–24.
- Smith JC, et al. (2008) Gene profiling of keloid fibroblasts shows altered expression in multiple fibrosis-associated pathways. *J. Invest. Dermatol.* 128:1298–310.
- Bullard KM, Longaker MT, Lorenz HP. (2003) Fetal wound healing: current biology. *World J. Surg.* 27:54–61.
- Szulgit G, et al. (2002) Alterations in fibroblast α 1 β 1 integrin collagen receptor expression in keloids and hypertrophic scars. *J. Invest. Dermatol.* 118:409–15.

43. Kose O, Waseem A. (2008) Keloids and hypertrophic scars: are they two different sides of the same coin? *Dermatol. Surg.* 34:336–46.
44. Bock O, et al. (2005) Studies of transforming growth factors beta 1–3 and their receptors I and II in fibroblast of keloids and hypertrophic scars. *Acta. Derm. Venereol.* 85:216–20.
45. Schmid P, et al. (1998) Enhanced expression of transforming growth factor-beta type I and type II receptors in wound granulation tissue and hypertrophic scar. *Am. J. Pathol.* 152:485–93.
46. Lee TY, et al. (1999) Expression of transforming growth factor beta 1, 2, and 3 proteins in keloids. *Ann. Plast. Surg.* 43:179–84.
47. Xia W, et al. (2004) Complex epithelial-mesenchymal interactions modulate transforming growth factor-beta expression in keloid-derived cells. *Wound Repair Regen.* 12:546–56.
48. Lu L, et al. (2005) The temporal effects of anti-TGF-beta1, 2, and 3 monoclonal antibody on wound healing and hypertrophic scar formation. *J. Am. Coll. Surg.* 201:391–7.
49. Cordeiro MF, et al. (2003) Novel antisense oligonucleotides targeting TGF-beta inhibit in vivo scarring and improve surgical outcome. *Gene Ther.* 10:59–71.
50. Shah M, Foreman DM, Ferguson MW. (1992) Control of scarring in adult wounds by neutralising antibody to transforming growth factor beta. *Lancet.* 339:213–4.
51. Shah M, Foreman DM, Ferguson MW. (1995) Neutralisation of TGF-beta 1 and TGF-beta 2 or exogenous addition of TGF-beta 3 to cutaneous rat wounds reduces scarring. *J. Cell. Sci.* 108(Pt 3):985–1002.
52. Cutroneo KR. (2007) TGF-beta-induced fibrosis and SMAD signaling: oligo decoys as natural therapeutics for inhibition of tissue fibrosis and scarring. *Wound Repair Regen.* 15 Suppl 1: S54–60.
53. ten Dijke P, Hill CS. (2004) New insights into TGF-beta-Smad signalling. *Trends Biochem. Sci.* 29:265–73.
54. Kopp J, et al. (2005) Abrogation of transforming growth factor-beta signaling by SMAD7 inhibits collagen gel contraction of human dermal fibroblasts. *J. Biol. Chem.* 280:21570–6.
55. Wang Z, et al. (2007) Inhibition of Smad3 expression decreases collagen synthesis in keloid disease fibroblasts. *J. Plast. Reconstr. Aesthet. Surg.* 60:1193–9.
56. Nakao A, et al. (1997) Identification of Smad7, a TGFbeta-inducible antagonist of TGF-beta signalling. *Nature.* 389:631–5.
57. Dooley S, et al. (2003) Smad7 prevents activation of hepatic stellate cells and liver fibrosis in rats. *Gastroenterology.* 125:178–91.
58. Chen MA, Davidson TM. (2005) Scar management: prevention and treatment strategies. *Curr. Opin. Otolaryngol. Head Neck Surg.* 13:242–7.
59. Terada Y, et al. (2002) Gene transfer of Smad7 using electroporation of adenovirus prevents renal fibrosis in post-obstructed kidney. *Kidney Int.* 61: S94–8.
60. Niessen FB, Schalkwijk J, Vos H, Timens W. (2004) Hypertrophic scar formation is associated with an increased number of epidermal Langerhans cells. *J. Pathol.* 202:121–9.
61. Andriessen MP, Niessen FB, Van de Kerkhof PC, Schalkwijk J. (1998) Hypertrophic scarring is associated with epidermal abnormalities: an immunohistochemical study. *J. Pathol.* 186:192–200.
62. Lim IJ, et al. (2001) Investigation of the influence of keloid-derived keratinocytes on fibroblast growth and proliferation in vitro. *Plast. Reconstr. Surg.* 107:797–808.
63. Eming SA, Krieg T, Davidson JM. (2007) Inflammation in wound repair: molecular and cellular mechanisms. *J. Invest. Dermatol.* 127:514–25.
64. Moyer KE, Sagers GC, Ehrlich HP. (2004) Mast cells promote fibroblast populated collagen lattice contraction through gap junction intercellular communication. *Wound Repair. Regen.* 12:269–75.
65. Noli C, Miolo A. (2001) The mast cell in wound healing. *Vet. Dermatol.* 12:303–13.
66. Ghahary A, Ghaffari A. (2007) Role of keratinocyte-fibroblast cross-talk in development of hypertrophic scar. *Wound Repair Regen.* 15 Suppl 1: S46–53.
67. Ghahary A, et al. (1996) Collagenase production is lower in post-burn hypertrophic scar fibroblasts than in normal fibroblasts and is reduced by insulin-like growth factor-1. *J. Invest. Dermatol.* 106:476–81.
68. Birkedal-Hansen H, et al. (1993) Matrix metalloproteinases: a review. *Crit. Rev. Oral. Biol. Med.* 4:197–250.
69. Johnson-Wint B. (1988) Do keratinocytes regulate fibroblast collagenase activities during morphogenesis? *Ann. N. Y. Acad. Sci.* 548:167–73.
70. Fujiwara M, Muragaki Y, Ooshima A. (2005) Keloid-derived fibroblasts show increased secretion of factors involved in collagen turnover and depend on matrix metalloproteinase for migration. *Br. J. Dermatol.* 153:295–300.
71. Neely AN, et al. (1999) Gelatinase activity in keloids and hypertrophic scars. *Wound Repair Regen.* 7:166–71.
72. Mauviel A. (1993) Cytokine regulation of metalloproteinase gene expression. *J. Cell. Biochem.* 53:288–95.
73. Zhang Y, McCluskey K, Fujii K, Wahl LM. (1998) Differential regulation of monocyte matrix metalloproteinase and TIMP-1 production by TNF-alpha, granulocyte-macrophage CSF, and IL-1 beta through prostaglandin-dependent and -independent mechanisms. *J. Immunol.* 161:3071–6.
74. McQuibban GA, et al. (2002) Matrix metalloproteinase processing of monocyte chemoattractant proteins generates CC chemokine receptor antagonists with anti-inflammatory properties in vivo. *Blood.* 100:1160–7.
75. McQuibban GA, et al. (2000) Inflammation dampened by gelatinase A cleavage of monocyte chemoattractant protein-3. *Science.* 289:1202–6.
76. Scott PG, et al. (1996) Chemical characterization and quantification of proteoglycans in human post-burn hypertrophic and mature scars. *Clin. Sci. (Lond).* 90:417–25.
77. Sayani K, et al. (2000) Delayed appearance of decorin in healing burn scars. *Histopathology.* 36:262–72.
78. Zhang Z, et al. (2009) Recombinant human decorin inhibits TGF-beta1-induced contraction of collagen lattice by hypertrophic scar fibroblasts. *Burns.* 35:527–37.
79. Mukhopadhyay A, et al. (2010) Syndecan-2 and decorin: proteoglycans with a difference—implications in keloid pathogenesis. *J. Trauma.* 68:999–1008.
80. Nedelec B, et al. (2001) Myofibroblasts and apoptosis in human hypertrophic scars: the effect of interferon-alpha2b. *Surgery.* 130:798–808.
81. Bond JS, et al. (2008) Maturation of the human scar: an observational study. *Plast. Reconstr. Surg.* 121:1650–8.
82. Bond JS, et al. (2008) Scar redness in humans: how long does it persist after incisional and excisional wounding? *Plast. Reconstr. Surg.* 121:487–96.
83. Mustoe TA, et al. (2002) International clinical recommendations on scar management. *Plast. Reconstr. Surg.* 110:560–71.
84. Durani P, Bayat A. (2008) Levels of evidence for the treatment of keloid disease. *J. Plast. Reconstr. Aesthet. Surg.* 61:4–17.
85. Mutalik S. (2005) Treatment of keloids and hypertrophic scars. *Indian J. Dermatol. Venereol. Leprol.* 71:3–8.
86. Baur PS, et al. (1976) Ultrastructural analysis of pressure-treated human hypertrophic scars. *J. Trauma.* 16:958–67.
87. Macintyre L, Baird M. (2006) Pressure garments for use in the treatment of hypertrophic scars—a review of the problems associated with their use. *Burns.* 32:10–5.
88. Kelly AP. (2004) Medical and surgical therapies for keloids. *Dermatol. Ther.* 17:212–8.
89. Reno F, et al. (2003) In vitro mechanical compression induces apoptosis and regulates cytokines release in hypertrophic scars. *Wound Repair Regen.* 11:331–6.
90. Van den Kerckhove E, et al. (2005) The assessment of erythema and thickness on burn related scars during pressure garment therapy as a preventive measure for hypertrophic scarring. *Burns.* 31:696–702.
91. Sawada Y, Sone K. (1992) Hydration and occlusion treatment for hypertrophic scars and keloids. *Br. J. Plast. Surg.* 45:599–603.
92. Fulton JE, Jr. (1995) Silicone gel sheeting for the prevention and management of evolving hypertrophic and keloid scars. *Dermatol. Surg.* 21:947–51.
93. Reish RG, Eriksson E. (2008) Scar treatments: preclinical and clinical studies. *J. Am. Coll. Surg.* 206:719–30.
94. Phan TT, et al. (2003) Quercetin inhibits fibronectin production by keloid-derived fibroblasts. Implication for the treatment of excessive scars. *J. Dermatol. Sci.* 33:192–4.

95. Jackson BA, Shelton AJ. (1999) Pilot study evaluating topical onion extract as treatment for postsurgical scars. *Dermatol. Surg.* 25:267-9.
96. Chung VQ, Kelley L, Marra D, Jiang SB. (2006) Onion extract gel versus petrolatum emollient on new surgical scars: prospective double-blinded study. *Dermatol. Surg.* 32:193-7.
97. Beuth J, et al. (2006) Safety and efficacy of local administration of contractubex to hypertrophic scars in comparison to corticosteroid treatment. Results of a multicenter, comparative epidemiological cohort study in Germany. *In Vivo.* 20:277-83.
98. Ho WS, Ying SY, Chan PC, Chan HH. (2006) Use of onion extract, heparin, allantoin gel in prevention of scarring in Chinese patients having laser removal of tattoos: a prospective randomized controlled trial. *Dermatol. Surg.* 32:891-6.
99. Asilian A, Darougheh A, Shariati F. (2006) New combination of triamcinolone, 5-fluorouracil, and pulsed-dye laser for treatment of keloid and hypertrophic scars. *Dermatol. Surg.* 32:907-15.
100. Zurada JM, Krieger D, Davis IC. (2006) Topical treatments for hypertrophic scars. *J. Am. Acad. Dermatol.* 55:1024-31.
101. Berman B, Kaufman J. (2002) Pilot study of the effect of postoperative imiquimod 5% cream on the recurrence rate of excised keloids. *J. Am. Acad. Dermatol.* 47:S209-11.
102. Berman B, et al. (2009) Treatment of keloid scars post-shave excision with imiquimod 5% cream: A prospective, double-blind, placebo-controlled pilot study. *J. Drugs Dermatol.* 8:455-8.
103. Prado A, Andrades P, Benitez S, Umana M. (2005) Scar management after breast surgery: preliminary results of a prospective, randomized, and double-blind clinical study with al-dara cream 5% (imiquimod). *Plast. Reconstr. Surg.* 115:966-72.
104. Ferguson MW, et al. (2009) Prophylactic administration of avotermin for improvement of skin scarring: three double-blind, placebo-controlled, phase I/II studies. *Lancet.* 373:1264-74.
105. Bush J, et al. (2010) Therapies with emerging evidence of efficacy: avotermin for the improvement of scarring. *Dermatol Res Pract* 2010:690613.
106. Jalali M, Bayat A. (2007) Current use of steroids in management of abnormal raised skin scars. *Surgeon.* 5:175-80.
107. Cruz NI, Korchin L. (1994) Inhibition of human keloid fibroblast growth by isotretinoin and triamcinolone acetonide in vitro. *Ann. Plast. Surg.* 33:401-5.
108. Boyadjiev C, Popchristova E, Mazgalova J. (1995) Histomorphologic changes in keloids treated with Kenacort. *J. Trauma.* 38:299-302.
109. Robles DT, Berg D. (2007) Abnormal wound healing: keloids. *Clin. Dermatol.* 25:26-32.
110. Lawrence WT. (1991) In search of the optimal treatment of keloids: report of a series and a review of the literature. *Ann. Plast. Surg.* 27:164-78.
111. Boutli-Kasapidou F, Tsakiri A, Anagnostou E, Mourellou O. (2005) Hypertrophic and keloidal scars: an approach to polytherapy. *Int. J. Dermatol.* 44:324-7.
112. Jaros E, Priborsky J, Klein L. (1999) Treatment of keloids and hypertrophic scars with cryotherapy [in Czech]. *Acta Medica (Hradec Kralove). Suppl.* 42:61-3.
113. Yosipovitch G, et al. (2001) A comparison of the combined effect of cryotherapy and corticosteroid injections versus corticosteroids and cryotherapy alone on keloids: a controlled study. *J. Dermatolog. Treat.* 12:87-90.
114. Sharpe D. (1997) Of apples and oranges, file drawers and garbage: why validity issues in meta-analysis will not go away. *Clin. Psychol. Rev.* 17:881-901.
115. Rusciani L, Rossi G, Bono R. (1993) Use of cryotherapy in the treatment of keloids. *J. Dermatol. Surg. Oncol.* 19:529-34.
116. Zouboulis CC, Blume U, Buttner P, Orfanos CE. (1993) Outcomes of cryosurgery in keloids and hypertrophic scars: a prospective consecutive trial of case series. *Arch. Dermatol.* 129:1146-51.
117. Har-Shai Y, Amar M, Sabo E. (2003) Intralesional cryotherapy for enhancing the involution of hypertrophic scars and keloids. *Plast. Reconstr. Surg.* 111:1841-52.
118. Poochareon VN, Berman B. (2003) New therapies for the management of keloids. *J. Craniofac. Surg.* 14:654-7.
119. Zuber TJ, DeWitt DE. (1994) Earlobe keloids. *Am. Fam. Physician.* 49:1835-41.
120. Guix B, et al. (2001) Treatment of keloids by high-dose-rate brachytherapy: a seven-year study. *Int. J. Radiat. Oncol. Biol. Phys.* 50:167-72.
121. Ogawa R, Mitsuhashi K, Hyakusoku H, Miyashita T. (2003) Postoperative electron-beam irradiation therapy for keloids and hypertrophic scars: retrospective study of 147 cases followed for more than 18 months. *Plast. Reconstr. Surg.* 111:547-55.
122. Apfelberg DB, et al. (1984) Preliminary results of argon and carbon dioxide laser treatment of keloid scars. *Lasers Surg. Med.* 4:283-90.
123. Alster TS, Handrick C. (2000) Laser treatment of hypertrophic scars, keloids, and striae. *Semin. Cutan. Med. Surg.* 19:287-92.
124. Tanzi EL, Alster TS. (2004) Laser treatment of scars. *Skin Therapy Lett.* 9:4-7.
125. Alster T. (2003) Laser scar revision: comparison study of 585-nm pulsed dye laser with and without intralesional corticosteroids. *Dermatol. Surg.* 29:25-9.
126. Alster TS, Williams CM. (1995) Treatment of keloid sternotomy scars with 585 nm flashlamp-pumped pulsed-dye laser. *Lancet.* 345:1198-200.
127. Dierickx C, Goldman MP, Fitzpatrick RE. (1995) Laser treatment of erythematous/hypertrophic and pigmented scars in 26 patients. *Plast. Reconstr. Surg.* 95:84-92.
128. Chan HH, et al. (2004) The use of pulsed dye laser for the prevention and treatment of hypertrophic scars in Chinese persons. *Dermatol. Surg.* 30:987-94.
129. Fiskerstrand EJ, Svaasand LO, Volden G. (1998) Pigmentary changes after pulsed dye laser treatment in 125 northern European patients with port wine stains. *Br. J. Dermatol.* 138:477-9.
130. Hermanns JF, Petit L, Hermanns-Le T, Pierard GE. (2001) Analytic quantification of phototype-related regional skin complexion. *Skin. Res. Technol.* 7:168-71.
131. Jimenez SA, Freundlich B, Rosenbloom J. (1984) Selective inhibition of human diploid fibroblast collagen synthesis by interferons. *J. Clin. Invest.* 74:1112-6.
132. Berman B, Duncan MR. (1989) Short-term keloid treatment in vivo with human interferon alfa-2b results in a selective and persistent normalization of keloidal fibroblast collagen, glycosaminoglycan, and collagenase production in vitro. *J. Am. Acad. Dermatol.* 21:694-702.
133. Tredget EE, et al. (1998) Transforming growth factor-beta in thermally injured patients with hypertrophic scars: effects of interferon alpha-2b. *Plast. Reconstr. Surg.* 102:1317-28; discussion 1329-30.
134. Tredget EE, et al. (1998) Transforming growth factor-beta in thermally injured patients with hypertrophic scars: effects of interferon alpha-2b. *Plast. Reconstr. Surg.* 102:1317-30.
135. Espana A, Solano T, Quintanilla E. (2001) Bleomycin in the treatment of keloids and hypertrophic scars by multiple needle punctures. *Dermatol. Surg.* 27:23-7.
136. Bodokh I, Brun P. (1996) Treatment of keloid with intralesional bleomycin [in French]. *Ann. Dermatol. Venereol.* 123:791-4.
137. Naeini FF, Najafian J, Ahmadvour K. (2006) Bleomycin tattooing as a promising therapeutic modality in large keloids and hypertrophic scars. *Dermatol. Surg.* 32:1023-30.
138. Saray Y, Gulec AT. (2005) Treatment of keloids and hypertrophic scars with dermojet injections of bleomycin: a preliminary study. *Int. J. Dermatol.* 44:777-84.
139. Apikian M, Goodman G. (2004) Intralesional 5-fluorouracil in the treatment of keloid scars. *Australas. J. Dermatol.* 45:140-3.
140. Fitzpatrick RE. (1999) Treatment of inflamed hypertrophic scars using intralesional 5-FU. *Dermatol. Surg.* 25:224-32.
141. Nanda S, Reddy BS. (2004) Intralesional 5-fluorouracil as a treatment modality of keloids. *Dermatol. Surg.* 30:54-7.