

Androgen receptors in Dupuytren's contracture

A. Pagnotta *, N. Specchia, F. Greco

Institute of Orthopedics, University of Ancona, Largo Cappelli 1, 60100 Ancona, Italy

Received 12 September 2000; accepted 30 April 2001

Abstract

Palmar fascia tissue and cultured cells from patients with Dupuytren's contracture and from normal subjects were characterized and analyzed for androgen receptor expression. Androgen receptors have never been studied in Dupuytren's myofibroblasts and may have a role in its high male predominance. Surgical samples were collected from eight patients undergoing surgery for Dupuytren's contracture and from four patients with carpal tunnel syndrome, used as control tissue. Immunohistochemical analysis was performed on tissue samples and on cell cultures with anti-androgen receptor, anti- α -smooth muscle actin, anti-fibronectin, and anti-type I and III collagen antibodies using the biotin-avidin peroxidase method as revelatory system. Immunostaining for androgen receptors in tissue samples and cultured cells revealed nuclear reaction in many Dupuytren's myofibroblasts, but in few fibroblasts of the normal palmar fascia. In a double-labeling study, androgen receptors were seen to co-localize with α -actin in both cell cultures and tissue samples.

We present the first evidence that the palmar fascia is a target tissue for androgen action and that the expression of androgen receptors in Dupuytren's contracture is considerably higher than in the normal palmar fascia. Further studies will need to evaluate whether the androgen-responsive state of the tissue is related to the high incidence of Dupuytren's contracture in the male sex. © 2002 Orthopaedic Research Society. Published by Elsevier Science Ltd. All rights reserved.

Introduction

Dupuytren's contracture is a fibro-proliferative disease characterized by shortening of the palmar fascia leading to progressive digital flexion deformity. The pathogenesis of the disease remains unclear. It is sometimes familial [13], and autosomal dominance with variable penetrance is considered the most likely mode of inheritance [29].

Gabbiani [7] was the first to hypothesize that myofibroblasts, specialized cells with phenotypical characteristics between fibroblasts and smooth muscle cells, could be responsible for the contracture. The myofibroblasts of Dupuytren's contracture express the α -smooth muscle actin isoform [25], the ED-A and ED-B fibronectin isoforms [10], the filament protein desmin [25] and several growth factors [3,9].

Higher prevalence of this disease has been reported in several conditions including manual labor [17], cirrhosis [20], diabetes mellitus [2], congenital epilepsy [1], ciga-

rette smoking [5], raised serum lipid levels [22] and HIV infection [4]. Clinical investigations have evidenced a strong, unexplained male predominance, with a male-female ratio of about 6:1 [28]. The hypothesis underlying the present work was that myofibroblast metabolism may be regulated by androgens.

Testosterone is converted at the cellular level to dihydrotestosterone by the enzyme 5 α -reductase which subsequently binds to androgen receptors within the cytosol and subsequently to nuclear DNA in a two-step mechanism; the binding of the nuclear hormone receptor complex to nuclear chromatin promotes gene expression as a direct response to hormone stimuli [24]. The myotropic activity of androgens is well known. They bind to nuclear receptors, stimulating skeletal [18] and smooth muscle cell proliferation [8]. The gene encoding the androgen receptor, alternatively known as the dihydrotestosterone receptor, is located on the X chromosome in the region between the centromer and Xq13 [14]. The expression of androgen receptor in target cells is a prerequisite for testosterone action [11,6]. Androgen receptors have never been studied in Dupuytren's myofibroblasts and may have a role in the high male predominance of this disease. The aim of the

* Corresponding author. Tel.: +39-071-5963346; fax: +39-071-204282.

E-mail address: pagal@katamail.com (A. Pagnotta).

present study was to investigate the possible expression of androgen receptors in Dupuytren's contracture and in normal palmar fascia tissue.

Materials and methods

Samples

Surgical samples were collected from eight patients (six male and two female; mean age = 68.4 years) undergoing surgery for Dupuytren's contracture. They consisted of single or multiple nodules of variable size, localized in the palmodigital and digital areas. Disease stage was between 1 and 4, according with Tubiana's scoring method [27]. In particular, three patients were coded at stage 1, two at stage 2, two at stage 3, and one at the stage 4. Samples of palmar fascia from four patients with carpal tunnel syndrome (two male and two female; mean age = 64.7 years) were used as control tissues. Each sample was divided into two sections: one was included in paraffin, cut in 5 μ m-thick serial sections and stained with hematoxylin–eosin, and the other was used for cell cultures.

Cell cultures

Dupuytren's nodular tissue was minced with microdissection scissors under aseptic conditions and washed extensively with serumless nutrient medium (DMEM; GIBCO, Italy) to remove the blood component. The chips were placed in 35 mm Petri dishes in DMEM supplemented with 10% heat-inactivated fetal calf serum (FCS) and 1% penicillin–streptomycin solution (both from GIBCO). Cultures were incubated at 37°C in a humidified atmosphere, 95% air, 5% CO₂. The medium was changed at 2-day intervals. After one week, cells began to migrate from the chips and formed a monolayer. They were harvested using trypsin–EDTA (GIBCO) and subcultured until the third passage.

The control cultures were grown in parallel under the same conditions.

Immunohistochemistry of tissue samples and cell cultures

Primary cells were replated in 4-well chamber slides (Nunc, IL, USA) and maintained in DMEM–10% FCS. After 7 days, cells were fixed with 2% phosphate-buffered formalin with 0.5% glutaraldehyde for 10 min at room temperature (RT).

Fixed cells and tissue samples were processed by the standard avidin–biotin peroxidase complex procedure (Vector, CA, USA). Non-specific binding was blocked with 3% normal goat serum in a phosphate-buffered saline solution (PBS), pH 7.4, for 30 min at RT, then cells and tissue samples were incubated with the primary antibodies overnight at 4°C. The following antibodies were used: polyclonal anti-type I collagen (1:100) (Monosan, The Netherlands), polyclonal anti-type III collagen (1:20) (DBA, Italy), polyclonal anti-fibronectin (1:600) (Sigma, Italy), monoclonal anti- α -smooth muscle actin

(Novocastra Laboratories, UK) and anti-androgen receptor (1:30) (Biogenex, CA, USA). The androgen receptor antibody binds to the peptide SP-61 (301–320) of the human androgen receptor and does not cross-react with human estrogen, progesterone or glucocorticoid receptors [30]. Rabbit and mouse immunoglobulins at the same dilutions as the primary antibodies were used as controls. Peroxidase activity was revealed by incubation with 0.05% 3,3'-diaminobenzidine tetrahydrochloride (DAB; Sigma) in PBS containing 0.03% peroxide for 5 min at RT; slides were then washed, dehydrated and mounted with Eukitt (O. Kindler GmbH, Germany). For the double-labeling procedure, the α -smooth muscle actin antibody was added first and the peroxidase activity was visualized by incubation with DAB, then androgen receptor antibody was added and revealed by 3-amino-9-ethylcarbazole (1 ml of a 4% solution of 3-amino-9-ethylcarbazole in dimethylformamide, 9 ml of 50 mM Na acetate, pH 5, and 0.01 ml of 30% H₂O₂). Sections were then mounted with Gel/mount (Biomedica, CA, USA).

Slides were examined under a Zeiss Axiophot (Germany) light microscope.

Histomorphometric analysis

Histomorphometric measurements were performed to compare the number of immunoreactive cells/area and the percentage of the area covered by labeling (area %) in Dupuytren's and normal palmar fascia using the Leitz, Quantimet 500 QWIN plus morphometric program (Leica, Cambridge, UK). Immunostaining was evaluated by examining for each reaction positive cells and areas in 10 random fields from slides of each patient. Data were analyzed using one-way analysis of variance (ANOVA).

Results

Histology and immunohistochemistry of tissue samples

Three histological phases were recognized in Dupuytren's nodules stained with hematoxylin–eosin: proliferative, involutinal, and residual [15]. The proliferative phase was characterized by high cellular density and dense vascularity; in the involutinal phase fibroblasts tended to be oriented in the same direction and collagen fibers increased in number; the residual phase was hypocellular and rich in collagen fibers. Around the nodules we also observed impurities like sweat glands, nerve fibers and, in one sample, a pacinian corpuscle.

The immunohistochemical results are summarized in Table 1.

Table 1

	Dupuytren area (%)	Normal fascia area (%)	Significant	Dupuytren cultures cells/area	Normal fascia cultures cells/area	Significant
Collagen type I	7.8 (\pm 4.6)	15.4 (\pm 10.6)	$P < 0.001$	13.8 (\pm 4.1)	15.6 (\pm 5.2)	NS
Collagen type III	5.7 (\pm 3.8)	1.5 (\pm 0.9)	$P < 0.001$	9.9 (\pm 1.9)	0	$P < 0.001$
Fibronectin	4.8 (\pm 1.4)	0	$P < 0.001$	16.5 (\pm 4.7)	0	$P < 0.001$
α -smooth muscle actin	7.7 (\pm 3.4)	0	$P < 0.001$	5.3 (\pm 2.6)	1.25 (\pm 0.9)	$P < 0.001$
Androgen receptor	1.7 (0.7)	0.09 (\pm 0.05)	$P < 0.001$	8.6 (\pm 2.9)	0.16 (\pm 0.3)	$P < 0.001$
Androgen + α -actin	0.8 (\pm 0.4)	0	$P < 0.001$	3.2 (\pm 1.1)	0.08 (\pm 0.2)	$P < 0.001$

Immunostaining for collagens, fibronectin, α -smooth muscle actin and androgen receptors was evaluated on the number of labeled cells/area and the area covered by labeling (area %) in 10 random fields for eight slides, one for each patient. Data were analyzed by one-way analysis of variance (ANOVA). Differences between Dupuytren's and normal palmar fascia for androgen receptors are highly significant in tissues ($F_{1,72} = 249.8$; $P < 0.001$) and cell cultures ($F_{1,96} = 409.8$; $P < 0.001$).

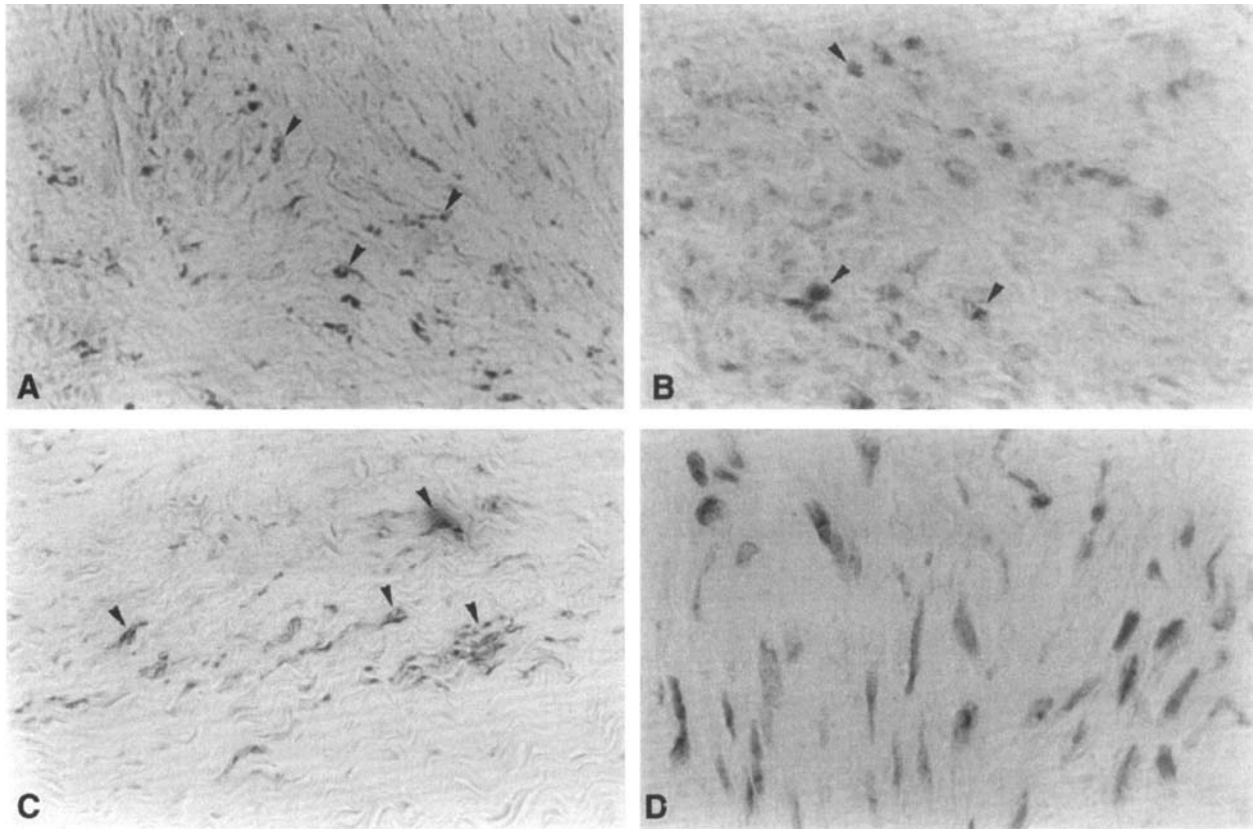


Fig. 1. (A) Tissue sections of Dupuytren's contracture were immunoreactive (arrows) for type III collagen in the proliferative nodules (400 \times). (B) Fibronectin staining was observed in the proliferative phase of Dupuytren's tissue (400 \times). (C) Myofibroblasts of proliferative areas stained for α -smooth muscle actin (400 \times). (D) Several myofibroblasts of Dupuytren's tissue stained for androgen receptors (1000 \times).

Type I collagen immunoreaction was scarce in Dupuytren's nodules but diffuse in normal palmar fascia, with highly significant differences ($F_{1,80} = 18.6$; $P < 0.001$). Staining for type III collagen was mainly observed in Dupuytren's nodules (Fig. 1(A)).

The anti-fibronectin antibody was localized intracellularly in the proliferative areas of the nodules (Fig. 1(B)). Staining for fibronectin was not observed in normal palmar fascia.

Labeling for α -smooth muscle actin was detected in the cytoplasm of the fibroblasts present in the highly cellular areas of the proliferative and involutinal phases (Fig. 1(C)), which were therefore identified as myofibroblasts. Control cells did not stain for this antibody and were thus identified as fibroblasts. The reaction was also detected in smooth muscle cells of small vessels and in myo-epithelial cells surrounding the cylindrical epithelium of sweat glands, serving as internal control.

Immunostaining for androgen receptors revealed a nuclear reaction in Dupuytren's myofibroblasts (Fig. 1(D)): the mean labeled area was $1.7\% \pm 0.7$ S.D., whereas in fibroblasts of the normal palmar fascia it was $0.09\% \pm 0.05$ S.D. (Fig. 2). The difference between Dupuytren and normal fascia was highly significant ($F_{1,72} = 249.8$; $P < 0.001$). Labeling was also detected in

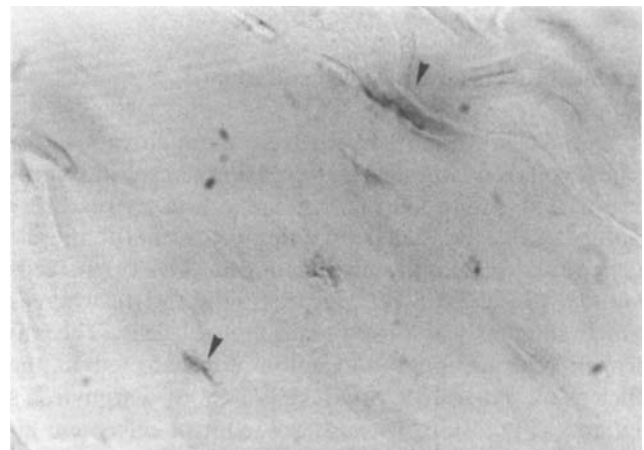


Fig. 2. Few cells of the normal palmar fascia were labeled for androgen receptors (1000 \times).

the cylindrical epithelium of sweat glands – which are known to express the androgen receptor protein – serving as internal control.

In the double-labeling study, androgen receptors co-localized with α -smooth muscle actin in Dupuytren's nodules, with highly significant differences from normal fascia.

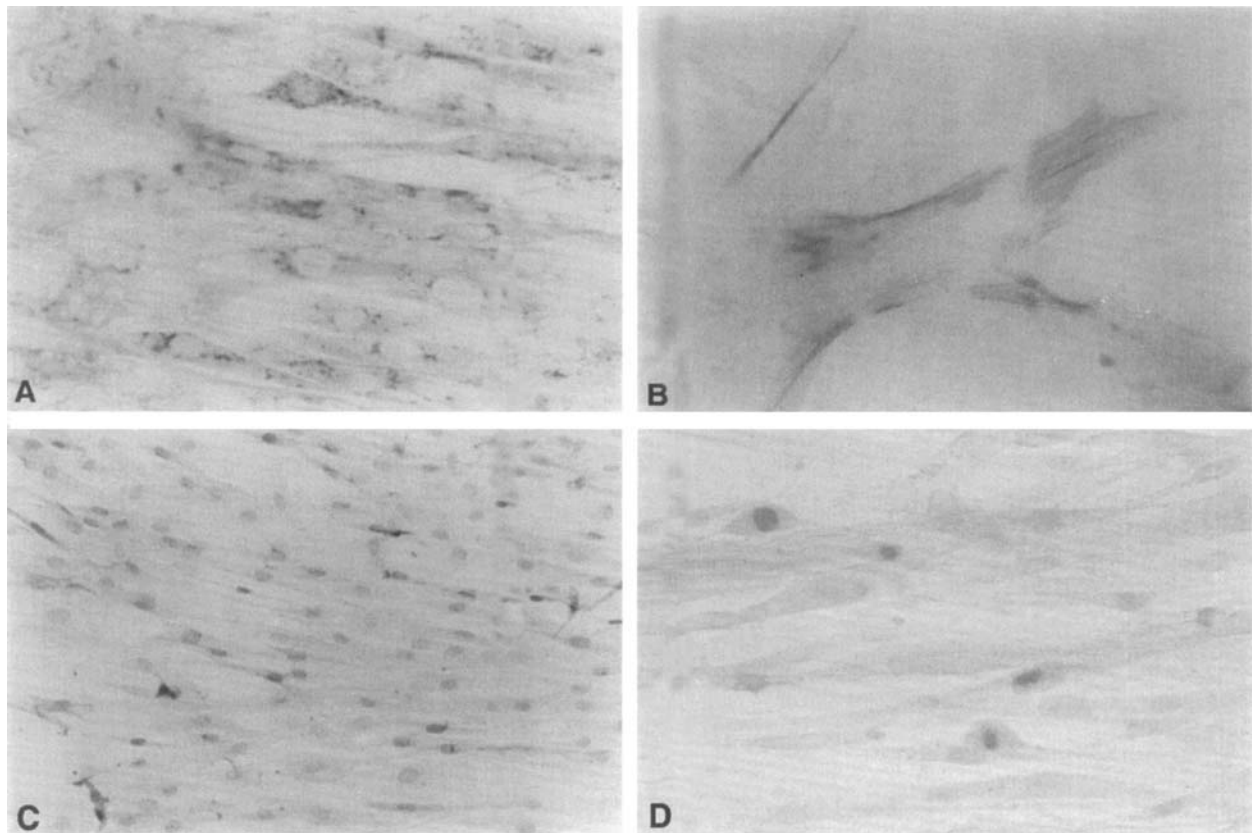


Fig. 3. (A) Cell cultures of Dupuytren specimens diffusely stained for anti-type I collagen antibody. (400 \times). (B) Expression of α -smooth muscle actin in myofibroblasts in vitro (400 \times). (C) Staining for androgen receptors antibody was localized in the nucleus of Dupuytren's myofibroblasts (200 \times). (D) Double immunostaining for α -smooth muscle actin (brown) and androgen receptors (red) was observed in the cytoplasm and in the nucleus, respectively, of the Dupuytren's myofibroblasts cultures (400 \times).

Immunohistochemistry of cell cultures

Dupuytren's cultured cells were immunoreactive for type I collagen (Fig. 3(A)), type III collagen and fibronectin and showed an intracellular and extracellular pattern (Table 1). Immunostaining for α -smooth muscle actin revealed cytoplasmic labeling in 28% of the cells counted (5.3 ± 2.6 S.D. cells/area) (Fig. 3(B)), whereas scarce staining was observed in control cells. The androgen receptor immunoreaction was detected in the nucleus of $8.6 (\pm 2.9$ S.D.) cells/area of Dupuytren's patients (Fig. 3(C)), whereas few control cells were labeled. Double-labeling for androgen receptors and α -smooth muscle actin was detected in Dupuytren's cells (3.2 ± 1.1 S.D. cells/area) (Fig. 3(D)), with highly significant differences from control cells.

Discussion

In this study, palmar fascia tissue and cultured cells from patients with Dupuytren's contracture and normal subjects were characterized and analyzed for androgen

receptor expression. In line with previous studies [16], myofibroblasts were the principal cellular component of Dupuytren's nodules. We identified the myofibroblastic phenotype with α -smooth muscle actin antibodies, which are highly reliable markers of these cells. The meaning of α -actin isoform expression is unknown, but may be related to the ability of fibroblasts to generate contractile force [26]. No reaction for α -smooth muscle actin was observed in normal palmar fascia, and although some normal cultured cells were labeled, serum supplementation may have induced the myofibroblast phenotype [19].

The working hypothesis underlying our interest in Dupuytren's contracture was that sex hormone receptors might have a role in myofibroblast metabolism. To preliminary test this hypothesis, we first studied and demonstrated by immunohistochemistry the presence of androgen receptors in the palmar fascia in tissue sections and cell cultures. Dupuytren's tissue showed a diffuse labeling for androgen receptors in the proliferative areas that was significantly higher than in the normal palmar fascia. In vitro, myofibroblasts strongly expressed androgen receptors, whereas few normal fascia cells were

immunoreactive. Moreover, the co-localization of α -smooth muscle actin and androgen receptors in tissues and in cultured cells of Dupuytren's nodules demonstrated that myofibroblasts are target cells for androgens.

The role of androgen receptors in skin is well known: acne and hirsutism are androgen-dependent diseases of sebaceous glands and hair follicles, respectively [24]. The prostate gland is also considered a highly androgen-dependent and -sensitive tissue: prostate cancer [12] and benign prostatic hyperplasia [21] might be receptor-regulated. In many tissues, the enzyme 5 α -reductase catalyzes the conversion of testosterone to the more active metabolite dihydrotestosterone (DHT). DHT then binds to the androgen receptor to regulate specific gene expression [12].

The role of androgens in Dupuytren's diseased fascia might be the induction of myofibroblast differentiation from fibroblasts and/or myofibroblast proliferation. Indeed, it is well established that testosterone can increase α -actin synthesis [23] and stimulate smooth muscle cell proliferation [8]. The localization of the androgen receptor protein in the normal fascia also suggests a possible physiological modulation of fascia growth and development.

In conclusion, we present data demonstrating that the palmar fascia is a target tissue for androgen action and that the expression of androgen receptors in Dupuytren's contracture is considerably higher than in the normal palmar fascia. We have thus established the basis for future in vitro investigations of the physiological and pathological mechanisms of androgen action in this tissue. Further studies will need to determine the role of androgens in the male predominance of Dupuytren's contracture.

Acknowledgements

We are very grateful to Sandra Manzotti for her technical assistance.

References

- [1] Arafa M, Noble J, Royle SG, Trail IA, Allen J. Dupuytren's and epilepsy revisited. *J Hand Surg* 1992;17:221–4.
- [2] Arkkila PE, Kantola IM, Viikari JSA, Ronnema T, Vahat MA. Dupuytren's disease in type I diabetic patients: a 5-year prospective study. *Clin Exp Rheumatol* 1996;14:59–65.
- [3] Baird KS, Crossan JF, Ralston SH. Abnormal growth factor and cytokine expression in Dupuytren's contracture. *J Clin Pathol* 1993;46:425–8.
- [4] Bower M, Nelson M, Gazzard BG. Dupuytren's contracture in patients infected with HIV. *Br Med J* 1990;300:165.
- [5] Burge P, Hoy G, Regan P, Milne R. Smoking, alcohol, and the risk of Dupuytren's contracture. *J Bone Joint Surg [Br]* 1997;79:206–10.
- [6] Doumit ME, Cook DR, Merkel RA. Testosterone up-regulates androgen receptors and decreases differentiation of porcine myogenic satellite cells in vitro. *J Endocrinol* 1996;137:1385–94.
- [7] Gabbiani G, Maino G. Dupuytren's contracture fibroblast contraction? *Am J Pathol* 1972;66:131–46.
- [8] Gerdes MJ, Dang TD, Lu B, Larsen M, McBride L, Rowley DR. Androgen-regulated proliferation and gene transcription in a prostate smooth muscle cell line (PS-1). *Endocrinology* 1996;137:864–72.
- [9] Gonzales AM, Buscaglia M, Fox R, Isacchi A, Sarmientos P, Farris J, et al. Basic fibroblast growth factor in Dupuytren's contracture. *Am J Pathol* 1992;141:661–71.
- [10] Halliday NL, Rayan GM, Zardi L, Tomasek JJ. Distribution of ED-A and ED-B fibronectin isoforms in Dupuytren's disease. *J Hand Surg* 1994;19A:428–34.
- [11] Hamlet WP, Liu SH, Panossian V, Finerman GAM. Primary immunolocalization of androgen target cells in the human anterior cruciate ligament. *J Orthop Res* 1997;15:657–63.
- [12] Liao S. Androgen action: molecular mechanism and medical application. *J Formosan Med Assoc* 1994;93(9):741–51.
- [13] Ling RSM. The genetic factor in Dupuytren's disease. *J Bone Joint Surg* 1963;45B:709–18.
- [14] Lubahn DB, Joseph DR, Sullivan PM, Willard HF, French FS, Wilson EM. Cloning of human androgen receptor complementary DNA and location to the X chromosome. *Science* 1988;240:327–30.
- [15] Luck J. Dupuytren's contracture. A new concept of the pathogenesis correlated with surgical management. *J Bone Joint Surg* 1959;41:635.
- [16] Magro G, Lantieri E, Micali G, Paravizzini G, Travali S, Lanzafame S. Myofibroblasts of palmar fibromatosis co-express transforming growth factor- α and epidermal growth factor receptor. *J Pathol* 1997;181:213–7.
- [17] McFarlane RM. Dupuytren's disease: relation to work and injury. *J Hand Surg [Am]* 1991;16:775–9.
- [18] Michel G, Baulieu EE. Androgen receptor in rat skeletal muscle: characterization and physiological variations. *Endocrinology* 1980;107(6):2088–98.
- [19] Moulin V, Garrel D, Auger FA, O'Connor-McCourt M, Castilhoux G, Germain L. What's new in human wound-healing myofibroblasts? *Curr Top Pathol* 1999;93:123–33.
- [20] Noble J, Arafa M, Royle SG, McGeorge G, Crank S. The association between alcohol, hepatic pathology and Dupuytren's disease. *J Hand Surg [Br]* 1992;17:71–4.
- [21] Ricciardelli C, Horsfall DJ, Sykes PJ, Marshall VR, Tilley WD. Effect of oestradiol-17 β and 5 α -dihydrotestosterone on guinea-pig prostate smooth muscle cell proliferation and steroid receptor expression in vitro. *J Endocrinol* 1994;140:373–83.
- [22] Sanderson PL, Morris MA, Stanley JK, Fahmy NR. Lipids and Dupuytren's disease. *J Bone Joint Surg [Br]* 1992;74:923–7.
- [23] Schlatt S, Weinbauer GF, Arslan M, Nieschlag E. Appearance of alpha-smooth muscle actin in peritubular cells of monkey testes is induced by androgens, modulated by follicle-stimulating hormone, and maintained after hormonal withdrawal. *J Androl* 1993;14(5):340–50.
- [24] Schmidt JB, Spona J, Huber J. Androgen receptor in hirsutism and acne. *Gynaecol Obstet Invest* 1986;22(4):206–11.
- [25] Shum DT, McFarlane RM. Histogenesis of Dupuytren's disease: an immunohistochemical study of 30 cases. *J Hand Surg* 1988;13A:61–6.
- [26] Tomasek J, Rayan GM. Correlation of α -smooth muscle actin expression and contraction in Dupuytren's disease fibroblasts. *J Hand Surg* 1995;20A:450–5.
- [27] Tubiana R. Dupuytren's disease of the radial side of the hand. *Hand Clinics* 1999;15 (1):149–59.

- [28] Wilbrand S, Ekbom A, Gerdin B. The sex ratio and rate of reoperation for Dupuytren's contracture in men and women. *J Hand Surg* 1999;24B:456–9.
- [29] Wurster-Hill DH, Brown F, Park JP, Gibson SH. Cytogenetic studies in Dupuytren contracture. *Am J Hum Genet* 1988;43:285–92.
- [30] Zegers ND, Claassen E, Neelen C, Mulder E, van Laar J, Voorhorst MM, et al. Epitope prediction and confirmation of the human androgen receptors: generation of monoclonal antibodies for multi-assay performance following the synthetic peptide strategy. *Biochim Biophys Acta* 1991;1073:23–32.