

THE PROXIMAL INTERPHALANGEAL JOINT

Anatomy and Causes of Stiffness in the Fingers

K. KUCZYNSKI, EDINBURGH, SCOTLAND

From the Departments of Anatomy and Orthopaedic Surgery, University of Edinburgh

One of the commonest and most serious problems of the injured finger is stiffness of the proximal interphalangeal joint either in flexion or, more rarely, in extension. This is reflected in the considerable number of references (Moberg and Stener 1953, Curtis 1954, 1964, James 1962, Peacock 1963, McCormack 1964). In contrast the problem in the metacarpo-phalangeal joint is one of stiffness in extension; when immobilised in flexion the joint seldom becomes stiff because of the sagittal cam effect which keeps the collateral ligaments stretched.

From dissection of fresh and fixed hand specimens some differences between the joints are immediately obvious. Firstly, the metacarpo-phalangeal joint is a ball-and-socket joint whereas the proximal interphalangeal joint is a hinge joint. Secondly, the configuration of the articular surfaces is different (Fig. 1). In consequence, the metacarpo-phalangeal joint allows abduction, adduction, circumduction and rotation in addition to flexion and extension. In contrast, at the proximal interphalangeal joint little movement is possible other than flexion and extension. Thirdly, hyperextension, particularly passive, is possible at the metacarpo-phalangeal joint but not at the interphalangeal joint. Fourthly, in the metacarpo-phalangeal joint the collateral ligaments are tight in flexion and slack in extension (Fig. 2) whereas in the

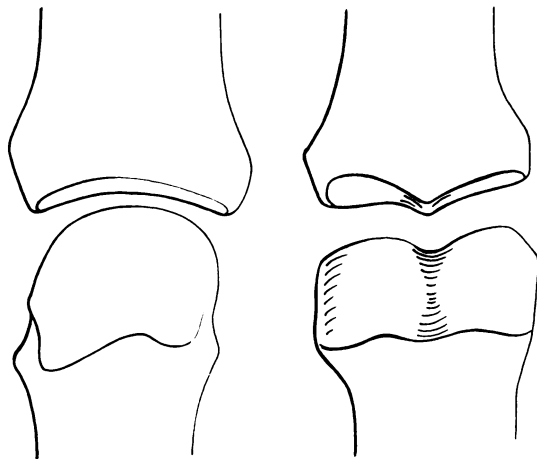


FIG. 1

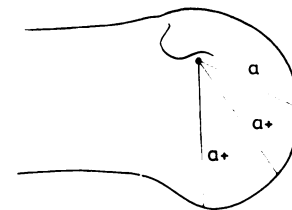


FIG. 2

FIGS. 1 AND 2

Figure 1—The fit of the articular surfaces in the metacarpo-phalangeal (*left*) and proximal interphalangeal joints (*right*).
Figure 2—The sagittal cam effect of the metacarpal head.

interphalangeal joint very little is known of tension in the collateral ligaments. Fifthly, in the metacarpo-phalangeal joint the palmar plate is connected to many mobile structures through its attachments to: 1) the deep transverse ligaments (and through them to the extensor expansion hood); 2) the tendons and some fibres of the interossei; and 3) the palmar aponeurosis. In the proximal interphalangeal joint the palmar plate is less mobile. It is attached firmly to the base of the middle phalanx, although its attachment to the neck of the proximal phalanx is loose. It is mobile in only one plane because of the rigid fibrous flexor sheath. Sixthly, there is much loose connective tissue anterior to the metacarpo-phalangeal joint, whereas there is much less loose connective tissue in front of the interphalangeal joint. Lastly, there is a structural and

functional link between the metacarpo-phalangeal joints, whereas the proximal interphalangeal joints are quite separate.

The present study was undertaken to find out more about the anatomy of the proximal interphalangeal joint and about its liability to stiffness, and to determine whether any particular position for immobilisation might prevent this complication. The observations were made mainly from dissection. Eleven anatomical specimens and ten amputated digits were examined.

ANATOMY

THE JOINT SURFACES

Head of proximal phalanx—There are a number of important features on the head of the proximal phalanx. Firstly, its profile in the transverse plane shows angulation of the line of

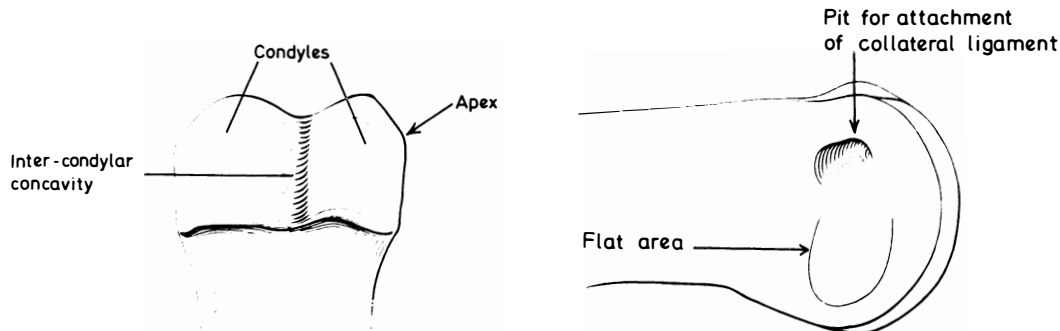


FIG. 3

FIG. 4

The head of the proximal phalanx. Figure 3—Antero-inferior aspect. Note the angulation on the lateral side forming transversely directed apex. Figure 4—Lateral aspect.

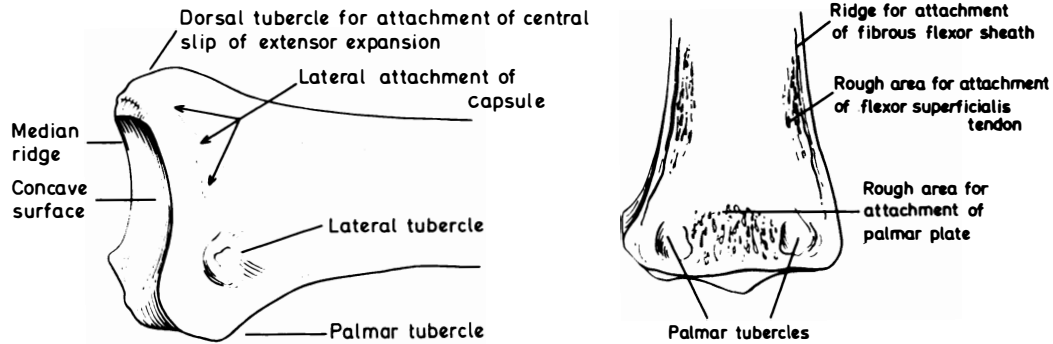


FIG. 5

FIG. 6

The base of the middle phalanx. Figure 5—Lateral aspect. Figure 6—Palmar aspect.

junction of the dorso-lateral and lateral surfaces of the articular cartilage where the dorsal slope changes to a more vertical plane at the lower part of the side of the head, forming a transversely directed apex (Fig. 3). Secondly, the pit for the attachment of the collateral ligament should be noted. Thirdly, there is a flat area, palmar to the pit, extending to the edge of the palmar surface of the head (Fig. 4). The two condyles are separated by the intercondylar concavity.

Base of middle phalanx—The base presents two concavities separated by a saddle-shaped median ridge (Fig. 1). On the dorsum of the base there is a tubercle formed by the dorsal part of the median ridge. To this tubercle is attached the central slip of the extensor expansion. The dorso-lateral and dorso-medial surfaces slope in a palmar direction towards the lateral tubercles. These surfaces accommodate the lateral tendons of the extensor expansion. On

the palmar aspect of the base, close to the articular surface, there is a rough flat area for the distal attachment of the palmar plate, and a small palmar tubercle on each side to which are attached some fibres of the lateral aspect of the capsule and some dorsal fibres of the flexor sheath (Figs. 5 to 7).

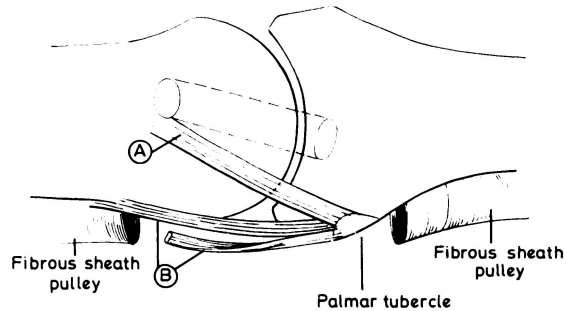


FIG. 7
Attachments of some of the lower fibres of the lateral capsule (A) and some of the fibres of the cruciate part of the flexor sheath (B).

THE CAPSULE

On the dorsum the capsule is replaced by the extensor expansion which overlies the synovial membrane. On the palmar aspect the capsule consists of the palmar plate. Proximally the plate is continuous with a pliable, much softer and bulkier band of connective tissue extending to the neck of the proximal phalanx. On the medial and the lateral aspects of the

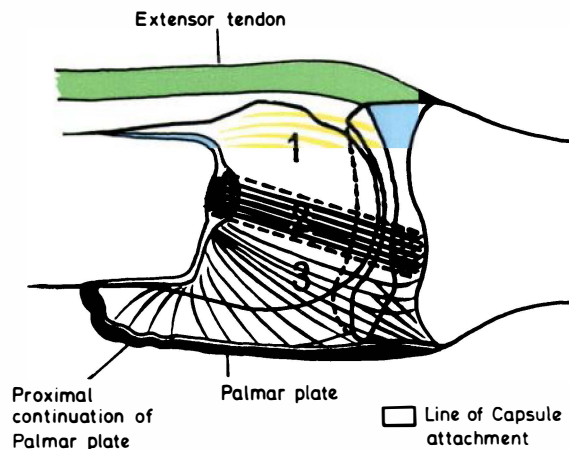


FIG. 8
The components of the lateral capsule of the proximal interphalangeal joint: 1) the upper area; 2) the collateral ligament; and 3) the lower area.

joint the capsule can be divided into three areas: the band of the collateral ligament (area 2), a triangular area above it (area 1) and a triangular fan-shaped area below it (area 3) (Fig. 8). Some of the dorsal fibres of area 3 are attached to the lower part of the lateral tubercle, some of them continue towards the small tubercle on the palmar aspect of the base of the phalanx where they meet the most dorsal fibres of the flexor sheath as they cross over the joint (Fig. 7).

SYNOVIAL ARRANGEMENTS

As in every synovial joint the synovial membrane lines the deep aspect of the capsule and the intracapsular bone not covered by articular cartilage. There are two extensive synovial pouches extending proximally, one dorsal and one palmar (Fig. 9).

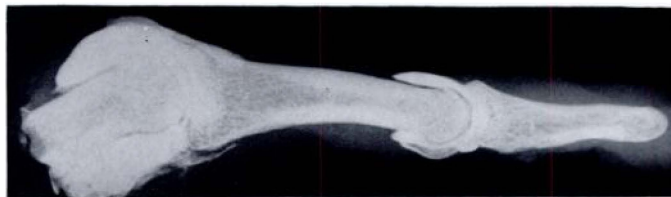

FIG. 9

Radiograph of the interphalangeal joints of the fresh amputation specimen after injection with contrast medium. Note the extensive synovial pouches.

RELATIONS OF PROXIMAL INTERPHALANGEAL JOINT

Dorsally there is a central tendon composed of three converging bands: a middle band from the extensor tendon and one on each side from the wings of the intrinsic tendons (Fig. 10).

Dorso-laterally and dorso-medially, when the joint is fully extended, the lateral tendons composed of two elements, one from the extrinsic tendon and one from the intrinsic tendon, lie on the slope of each condyle. They slide palmarwards along the slope during flexion.

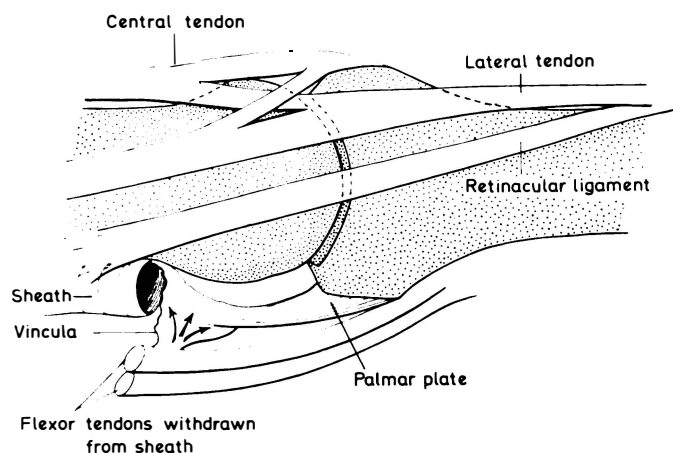


FIG. 10

The relations of the proximal interphalangeal joint.

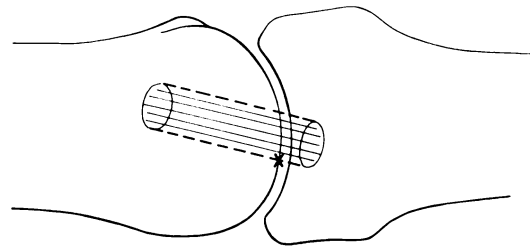
Laterally, the retinacular ligament lies anterior to the lateral tendon. In addition there are the digital cutaneous ligaments which extend from the periosteum to the skin and contain the neurovascular bundles.

Anterior to the palmar plate there is the flexor tendon sheath. The vinculum breve of the superficialis tendon and the vinculum longum of the profundus tendon are attached to the fibrous tissue proximal to the palmar plate.

FUNCTIONAL ANATOMY

The superficial fibres of the collateral ligament are attached to the lateral tubercle at the base of the middle phalanx. The central fibres pass to the palmar aspect of the tubercle, fusing with fibres of the flexor sheath just distal to the attachment of the palmar plate. The

deepest fibres of the ligament have the same attachment as the superficial fibres. Anterior to the collateral ligament the capsular fibres are thin and less directionally defined but eventually attach to the edge of the palmar plate and flexor sheath. The proximal attachment of the collateral ligament is to the pit on the side of head of proximal phalanx (Fig. 4). In full extension the collateral ligaments lie just dorsal to the apex of angulation on the phalangeal head (Fig. 11).



Collateral ligament

X = apex of side margin of head of proximal phalanx.

FIG. 11

The relationship of the collateral ligament to the apex of angulation of the lateral aspect of the head of the proximal phalanx.

The capsule of the proximal interphalangeal joint was exposed and fibres A and B (Fig. 7) were divided. This allowed hyperextension of 20 to 25 degrees. In this position the palmar plate became tense. In another joint fibres A and B and the palmar plate were divided in order to see whether the collateral ligaments could by their obliquity prevent hyperextension. Even with the ligaments intact the joint could be grossly hyperextended.

PATHOLOGICAL ANATOMY

Two joints were stiff in extension and six were stiff in flexion.

Stiffness in extension—In the first case there had been a transverse fracture through the neck of the middle phalanx with division of the extensor expansion at the level of the proximal interphalangeal joint one year previously (Fig. 12). The radial retinacular ligament was adherent to the bone as far as its junction with the lateral tendon which itself was adherent by its deep surface to the fracture line where it was pierced by a spicule of bone. The extensor apparatus was adherent to the bone on either side of the proximal interphalangeal joint and at the suture site. After the extensor expansion had been freed of its adhesions, full flexion of the proximal interphalangeal joint was easily obtained.

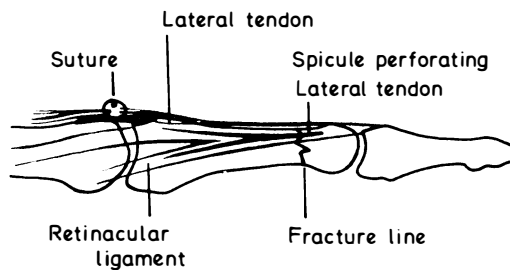


FIG. 12

Extension contracture of the proximal interphalangeal joint one year after fracture through the neck of the middle phalanx and division of the extensor apparatus at the level of the proximal interphalangeal joint.

from the middle phalanx, slight flexion only was possible. Full release of the contracture was obtained after division of the upper part of the collateral portion of the capsule on each side (area 1) and of both collateral ligaments.

In the second case there had been an injury many years previously and the distal phalanx had been amputated (Fig. 13). After the extensor and flexor tendons had been freed

This suggests that the primary cause of the extension contracture in these cases was at first adhesion of the extensor apparatus followed in the long-standing case by a secondary contracture of the upper part of the collateral portions of the capsule, with the collateral ligaments lying dorsally to the apex of angulation of the phalangeal head and not being subjected to the effect of the transverse cam.

Stiffness in flexion—In one case of contracture persisting long after injury the palmar plate and its soft proximal continuation were normal. The lower part of the collateral portions of the capsule (A) and most dorsal fibres of the flexor sheath (B) were extremely tight (Fig. 14). Division of these fibres released the contracture. Snapping occurred after division of the fibres of the flexor sheath because of the still undivided capsular fibres moving from the protruding

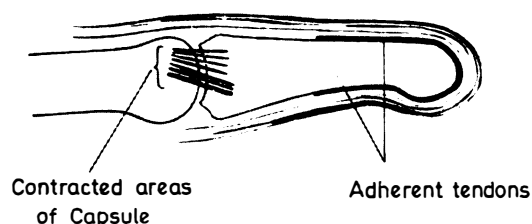


FIG. 13

Diagram showing a long-standing extension contracture of the proximal interphalangeal joint.

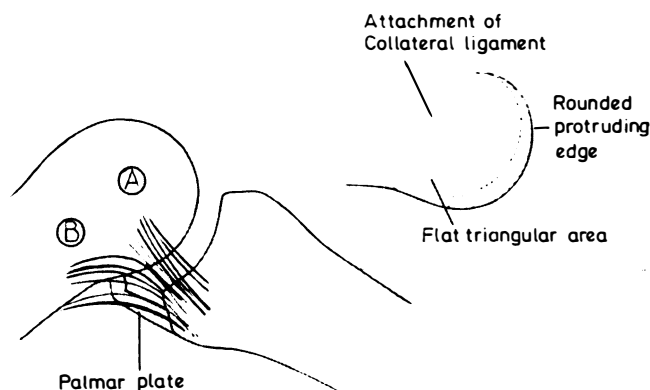


FIG. 14

Long-standing flexion contracture of the proximal interphalangeal joint many years after injury. The insert shows the shape of the head of the proximal phalanx.

margin of the side of the head back to the flat area. This snapping disappeared after division of the capsular fibres.

In four cases flexion contracture of the proximal interphalangeal joint was caused by Dupuytren's affection. In the first case the palmar plate was found to have degenerated into a small mass of fibrous tissue surrounded by much fatty areolar material. The capsular and flexor sheath fibres were tight, the latter being incorporated in affected tissue. Division of both sets of fibres allowed full extension. Snapping occurred after division of the flexor sheath fibres only (Fig. 15).

In the second case capsular and flexor sheath fibres were tight, and the proximal attachment of the palmar plate was folded on itself and adherent to the bone. It had to be freed after division of both sets of fibres before the contracture could be released (Fig. 16).

In the third case the palmar plate and its proximal continuation were normal and extension was restored by division of the capsular and flexor sheath fibres (Fig. 17).

In the fourth case the palmar aspect of the joint was infiltrated with a large mass of Dupuytren's tissue, so that identification of the palmar structures was impossible. Extension was not achieved even after complete division of the capsule on both sides of the joint.

It seems that the capsular and flexor sheath fibres are involved in flexion contracture of the proximal interphalangeal joint following trauma and in Dupuytren's disease. As the

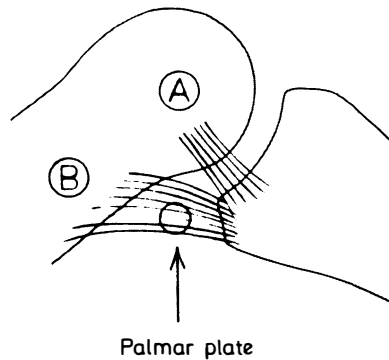


FIG. 15

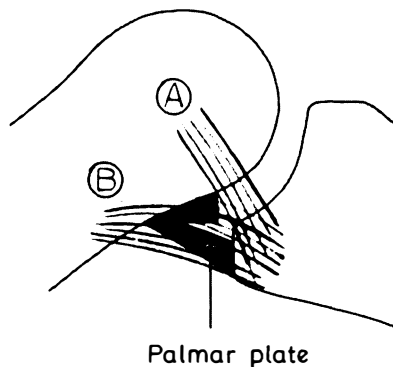


FIG. 16

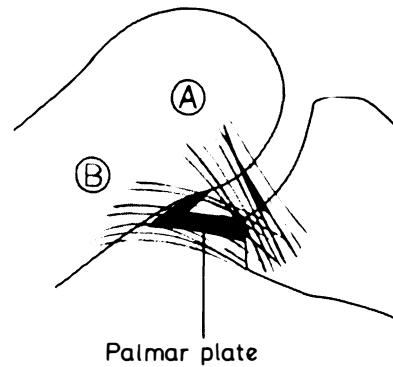


FIG. 17

Contractures of the proximal interphalangeal joint caused by Dupuytren's affection.

contracture increases the collateral ligaments and capsular fibres slide over the protruding rounded articular margin on to the flat area (Fig. 4). The palmar plate and its proximal continuation become involved in some cases.

CONCLUSIONS

During flexion of the joint from the fully extended position the collateral ligaments soon become tight as they pass over the apex of angulation of the side margin of the head and remain tight as they move over more vertical plane of the side of the head.

From measurements on the dissected fingers, from measurements on radiographs and from tracings of photographs of the proximal phalanx it was not possible to draw any definite conclusions about the sagittal cam effect comparable to those relating to the metacarpophalangeal joint. A few specimens exhibited some degree of this cam but most did not. This may be related to functional variations of individual fingers and requires more detailed study.

If the joint is immobilised for some time in flexion with the collateral ligaments well below the apex of angulation, the slack volar part of the collateral aspects of the capsule with

fibres running to the lateral and palmar tubercles of the middle phalanx and the dorsal fibres of the flexor sheath may become contracted. Shortening of the fibres of the lower part of the collateral portions of the capsule (A) and of the most dorsal fibres of the flexor sheath (B) was a constant finding. Curtis (1964) advocated excision of a portion of flexor sheath over the joint in dealing with flexion contracture.

Dissection of two fingers affected by extension contracture suggests that it takes a long time to produce shortening of the soft and pliable more dorsal part of the capsule.

It appears therefore that if immobilisation of the proximal interphalangeal joint cannot be avoided, it should be for as short a period as possible, with the collateral ligaments just riding over the apex of the side margin on the head when fibres A and B are only slightly slack. The results of immobilising the injured finger with the proximal interphalangeal joint flexed not more than 15 degrees might be compared with those after immobilisation with the joint more flexed. Splintage of the joint in extension was advised by Stewart (1962) on functional and clinical grounds. He noted the importance of flexion of the metacarpo-phalangeal joint and used the position of extension in all cases except those of: 1) gross damage leading inevitably to stiffness; and 2) division of flexor tendons or infection in the tendon sheath.

It is suggested that in correction of contracture of the proximal interphalangeal joint caused by Dupuytren's affection it may be advisable to excise fibres A and B.

I am grateful to Professor G. J. Romanes and Professor J. I. P. James for their interest and advice and permitting me to use departmental facilities; to Dr Thomas A. Wright for the help with dissection; to Mr Alan Dodds of the Photographic Department of the Princess Margaret Rose Orthopaedic Hospital in Edinburgh and to Mrs Ann McNeill (Ann Brown) of the Department of Medical Illustration of the University of Edinburgh for technical assistance with the photographs and diagrams.

REFERENCES

- CURTIS, R. M. (1954): Capsulectomy of the Interphalangeal Joints of the Fingers. *Journal of Bone and Joint Surgery*, **36-A**, 1219.
- CURTIS, R. M. (1964): Treatment of Injuries of Proximal Interphalangeal Joints of Fingers. *Current Practice in Orthopaedic Surgery*, **2**, 125.
- JAMES, J. I. P. (1962): Fractures of the Proximal and Middle Phalanges of the Fingers. *Acta Orthopaedica Scandinavica*, **32**, 401.
- MCCORMACK, R. M. (1964): Stiffness of the Injured Hand. *Journal of Trauma*, **4**, 581.
- MOBERG, E., and STENER, B. (1953): Injuries to the Ligaments of the Thumb and Fingers. *Acta Chirurgica Scandinavica*, **106**, 166.
- PEACOCK, E. E., Jun. (1963): Preservation of Interphalangeal Joint Function. *Southern Medical Journal*, **56**, 56.
- STEWART, I. M. (1962): Boutonnière Finger. *Clinical Orthopaedics*, **23**, 220.