

Dermofasciectomy in the management of Dupuytren's disease

J. R. Armstrong, J. S. Hurren, A. M. Logan

From West Norwich Hospital, Norwich, England

Dupuytren's disease may present with well-defined subcutaneous cords or as more diffuse disease with involvement of the skin. Fasciectomy is the procedure commonly carried out for the full range of disease, but is associated with rates of recurrence of up to 66%. We reviewed 143 rays in 103 patients undergoing dermofasciectomy for diffuse disease with involvement of the skin. We found recurrence in 12 rays (8.4% of rays; 11.6% of patients) during a mean follow-up of 5.8 years, eight as cords and four as nodules. We suggest that dermofasciectomy is a better method of disease control than fasciectomy for the more diffuse type of disease with involvement of the skin.

J Bone Joint Surg [Br] 2000;82-B:90-4.

Received 15 January 1999; Accepted after revision 21 April 1999

Dupuytren's disease on the ulnar side of the hand varies from a relatively benign, slowly contracting, well-localised pretendinous cord of the ray of the ring finger, with slowly progressive flexion contracture of the metacarpophalangeal joint, to a much more aggressive, relatively diffuse disease with involvement of the skin of the little finger ray and flexion contracture of the metacarpophalangeal and proximal interphalangeal joints.

Many surgeons perform fasciectomy for the whole spectrum of Dupuytren's disease. The outcome is clearly unsatisfactory with rates of recurrence ranging from 27% to 66%.¹⁻⁸ Hueston⁷ recorded recurrence in 28% after fasciectomy, but called the appearance of an abductor band in the little finger⁹ after excision of a pretendinous cord

extension rather than recurrence; he also noted that most recurrences after fasciectomy were in the little finger ray. About half of the recorded recurrences required further operation which we consider to be a reflection, in part, of a reluctance towards surgery by both surgeon and patient.

Segmental aponeurectomy has been promoted as a procedure with a much lower rate of complications than fasciectomy, but recurrence was 36% when determined non-selectively for all cases.¹⁰ Preoperative skeletal traction to extend a flexed digit before fasciectomy is 'commonly' associated with recurrence.¹¹

It is not our practice to use a single procedure for all patients with Dupuytren's disease but to match the surgical intervention to the nature of the disease. Benign pretendinous disease of the ring finger can be treated adequately by proximal and distal palmar segmental aponeurectomy. We carry out limited fasciectomy¹² when well-localised cords have resulted in flexion contracture of the proximal interphalangeal joint. When the disease appears to be more diffuse and involvement of the skin is marked we resort to dermofasciectomy.¹³ Contrary to Hueston's view¹³ that replacement of the skin is the all-important factor in the control of the disease, we believe that dermofasciectomy should be thought of as a subtotal preaxial amputation of the digit, removing all tissue which may result in further flexion contracture.¹⁴

We have reviewed the effectiveness of dermofasciectomy for relatively diffuse Dupuytren's disease with involvement of the skin.

Patients and Methods

Between 1986 and 1995 we carried out dermofasciectomy in 135 patients.

Of these, 103 with a total of 143 dermofasciectomies were available for review; five patients had died and 27 had been lost to follow-up. There were 82 men and 21 women with a mean age at the time of operation of 69.2 years (37.3 to 87.6). Of the 143 dermofasciectomies, 110 had been performed as a primary procedure and 33 for recurrent disease. Table I gives the number of previous fasciectomies carried out on the ray undergoing dermofasciectomy for recurrent disease. Our aim was to determine whether there was recurrence of Dupuytren's disease in the operated ray

J. R. Armstrong, FRCS, Senior Registrar in Plastic Surgery
J. S. Hurren, BSc, FRCS, Locum Consultant in Plastic Surgery
A. M. Logan, FRCS, Consultant Plastic Surgeon
Department of Plastic Surgery, West Norwich Hospital, Bowthorpe Road,
Norwich NR2 3TU, UK.

Correspondence should be sent to Mr A. M. Logan.

©2000 British Editorial Society of Bone and Joint Surgery
0301-620X/00/19808 \$2.00

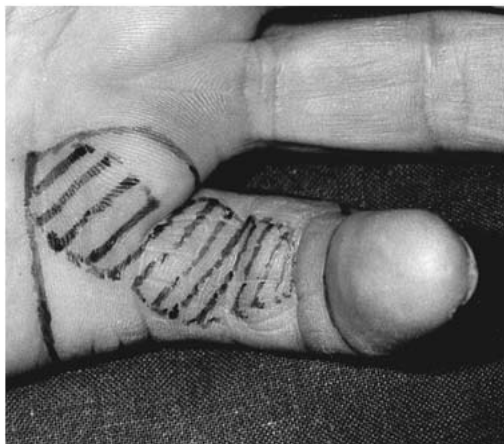


Fig. 1a

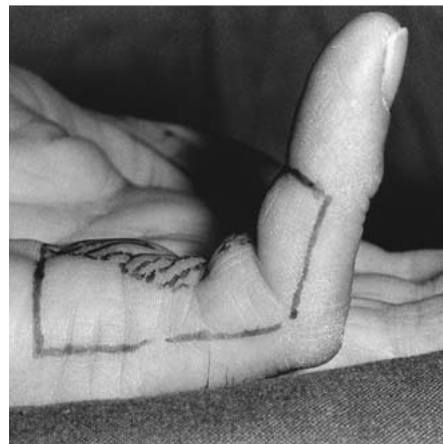


Fig. 1b

Photographs of Dupuytren's disease with involvement of the skin (shaded) causing proximal contracture of the interphalangeal joint. The area of the skin excision is marked with a continuous line. The skin excision extends to the midaxial line.

Table I. The number of rays which had undergone previous surgery; most of the previous operations were fasciectomies

Number of previous operations on same ray	Number of rays
1	26
2	5
4	2

and, if so, whether it was in the form of a nodule or a cord. The number of previous operations for Dupuytren's disease carried out on the operated ray was recorded.

Operative technique. The skin was prepared and draped in a standard fashion, with the limb elevated and an arm tourniquet inflated to 250 mmHg to prevent blood from obscuring the surgical field. Our standard dermofasciectomy involved excision of skin from the distal palmar crease to the distal flexion crease of the interphalangeal joint

carried out to the midaxial line on either side of the digit (Fig. 1). The neurovascular bundles were identified in the proximal end of the wound and exposed distally. The pretendinous and subcutaneous tissue between them was then excised. Next, the ulnar element was dealt with. In the little finger this is usually extensive when the disease has resulted in proximal interphalangeal flexion, and its excision exposes the insertion of abductor digiti minimi on to the proximal phalanx, the ulnar side of the periosteum of the proximal phalanx, the ulnar side of the capsule of the proximal interphalangeal joint and the ulnar side of the border of the extensor mechanism. The dorsal branch of the ulnar nerve must be protected (Fig. 2). The radial element was less constant and, when present, was excised (Fig. 3). In doing so the dorsal branch of the radial digital nerve should be protected. The amount of correction of the contracture was probably similar to that achieved by a limited fasciectomy. The tourniquet was then released. To

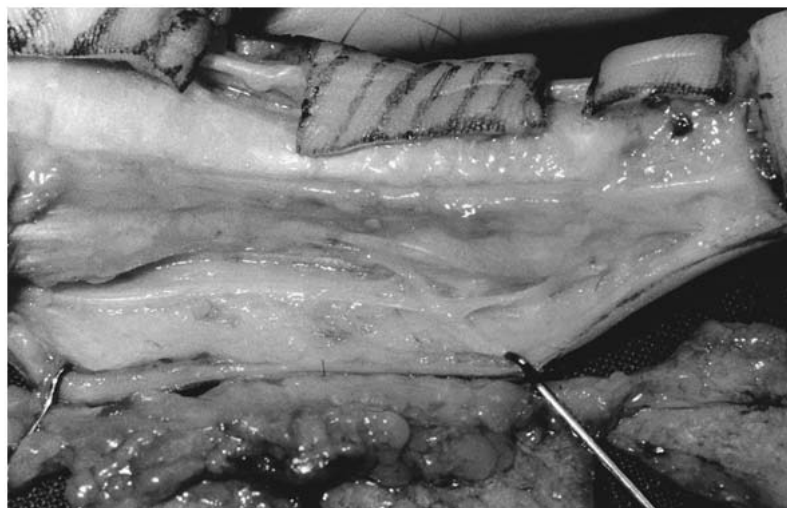


Fig. 2

The ulnar view of the surgical dissection.

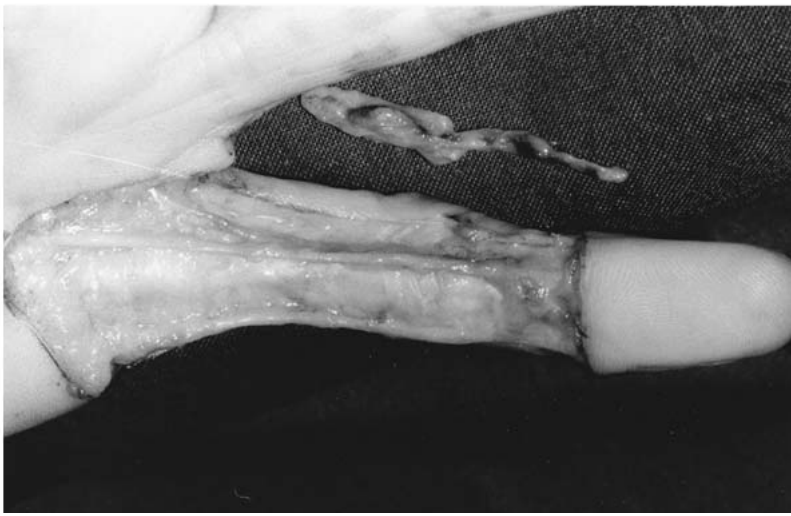


Fig. 3

Completed dermofasciectomy dissection before skin grafting. The specimen of a clinically undetected radial cord is shown adjacent to the finger.

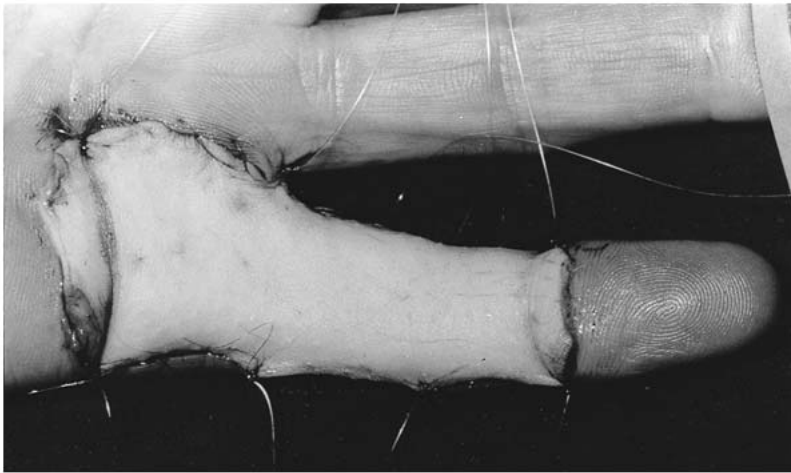


Fig. 4

The graft is sutured in position.

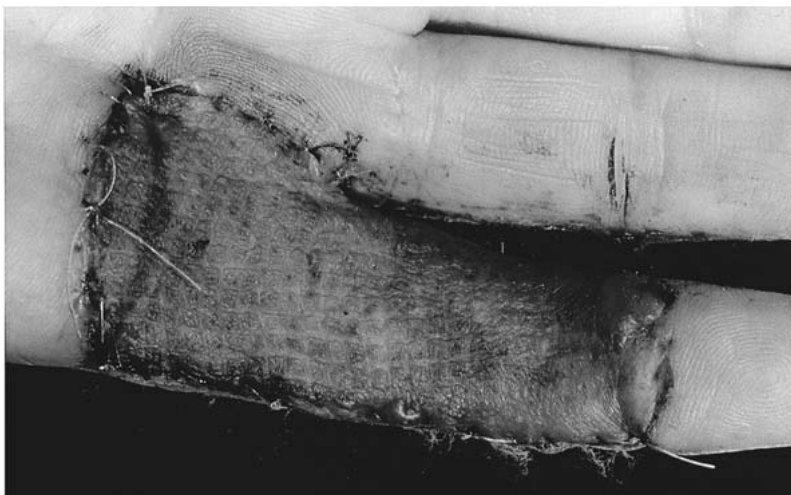


Fig. 5

After removal of the dressing at one week there is a well-vascularised full-thickness skin graft.

close the resultant defect a full-thickness skin graft was used. For a little finger, this was usually about 6 cm long, 3.5 cm wide proximally and 2.5 cm wide distally. It was taken from the hairless area of the proximal, volar forearm

or from the medial aspect of the arm as a long ellipse, and the donor site was closed by direct suture. After removal of the fat from its deep surface with scissors the graft was accurately sutured into the defect (Fig. 4). Additionally,

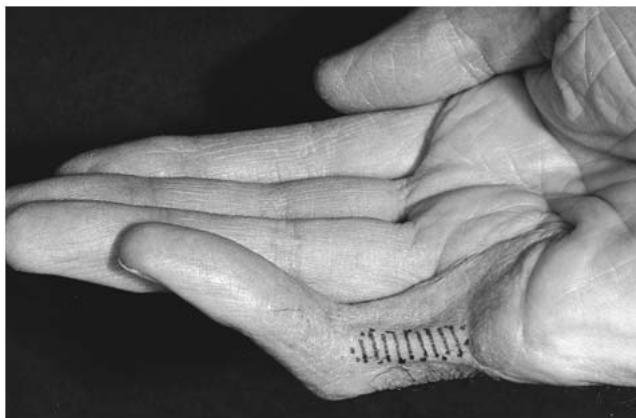

Fig. 6

Example of a recurrent cord.

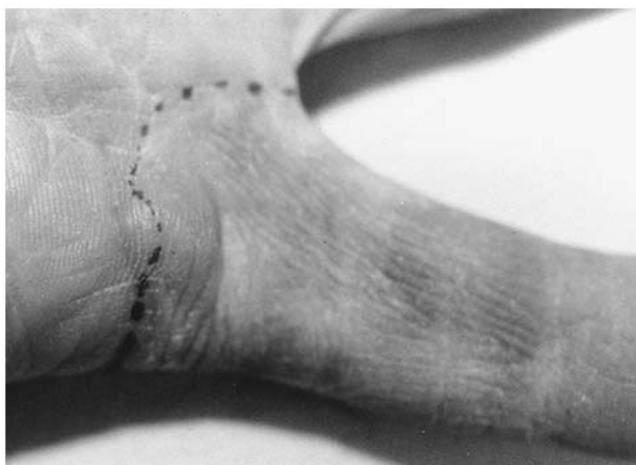

Fig. 7

Example of a recurrent nodule at the distal palmar crease.

some four sutures were placed along each side of the graft and left long to be loosely tied over a bulky gauze dressing. This stabilises the graft on the finger and helps to prevent shearing of vessel ingrowth and significant finger flexion. A full 'boxing-glove' dressing was then lightly applied in order to protect the hand for one week. The hand and forearm were elevated in a sling. After confirmation of successful adherence of the skin graft (Fig. 5) gentle mobilisation was started after removal of the dressing. More aggressive mobilisation began at two weeks as the graft stabilised.

Results

The mean follow-up was 5.8 years (2.1 to 11.5). The distribution of rays undergoing dermofasciectomy is shown in Table II. There were nine certain and three possible recurrences. The diagnosis of recurrence is clinical and often difficult; all doubtful recurrences were included. No

Table II. Number of dermofasciectomy carried out for each ray of the hand

Ray	Number
Thumb	4
Index	2
Middle	7
Ring	34
Little	96

patient had more than one recurrence, giving a rate of recurrence per ray of 8.4% and per patient of 11.6%. Eight of the recurrences were classified as cords (Fig. 6) and four as nodules (Fig. 7). Only one cord had progressed to recontracture.

Discussion

Dermofasciectomy for Dupuytren's disease, although promoted by Hueston,¹² has never been popular possibly because of over-cautious expectation of the 'take' of the skin graft on bared flexor sheaths and neurovascular bundles. It is our experience that a successful skin graft is to be expected unless both digital arteries have been damaged.¹⁵⁻¹⁷ The robustness of the harvested skin has also been questioned. We found that forearm and arm donor sites gave good digital cosmesis and that the skin was sufficiently robust for most patients; both cosmesis and robustness can be improved by the use of submalleolar skin.¹⁴

The involved skin must be excised.¹⁸ The surgical technique which we used gave an excellent view of the underlying diseased tissues, which were usually seen to be more extensive after surgical exposure than had been observed on clinical examination. Wide excision of the preaxial tissues could be carried out without concern for vascularity of the overlying flap. Full-thickness skin grafts controlled bleeding and closed the resultant defect without longitudinal palmar scars or tension. The supple graft allowed excellent recovery of flexion.¹⁷

Our results confirmed the low rates of recurrence of Dupuytren's disease after dermofasciectomy reported by others.^{13,15,19-21} While encouraging reports of new methods such as the use of injected collagenase, are beginning to emerge,²² and while others are examining profiles of growth factors in active Dupuytren's disease as therapeutic targets,²³ dermofasciectomy currently seems to be the best surgical technique for controlling diffuse Dupuytren's disease with involvement of the skin.

No benefits in any form have been received or will be received from a commercial party related directly or indirectly to the subject of this article.

References

1. Tubiana R, Leclercq C. Recurrent Dupuytren's disease. In: Hueston JT, Tubiana R, eds. *Dupuytren's disease*. 2nd ed. Edinburgh: Churchill Livingstone, 1985:200-3.

2. **Hakstian RW.** Long term results of extensive fasciectomy. *Br J Plast Surg* 1966;19:140-9.
3. **Tonkin MA, Burke FD, Varian JPW.** Dupuytren's contracture: a comparative study of fasciectomy and dermofasciectomy in one hundred patients. *J Hand Surg* 1984;90-B:156-62.
4. **Foucher G, Cornil C, Lenoble E.** Open palm technique for Dupuytren's disease: a five year follow-up. *Ann Chir Main Memb Super* 1992;11:362-6.
5. **Adam RF, Loynes RD.** Prognosis in Dupuytren's disease. *J Hand Surg Am* 1992;17:312-7.
6. **Cools H, Verstreken J.** The open palm technique in the treatment of Dupuytren's disease. *Acta Orthop Belg* 1994;60:413-20.
7. **Hueston JT.** Recurrent Dupuytren's contracture. *Plast Recon Surg* 1963;31:66-9.
8. **Makela EA, Jaroma H, Harju A, Anttila S, Vainio J.** Dupuytren's contracture: the long term results after day surgery. *J Hand Surg Br* 1991;16:272-4.
9. **Barton NJ.** Dupuytren's disease arising from the abductor digiti minimi. *J Hand Surg Br* 1984;9:265-70.
10. **Moermans JP.** Segmental aponeurectomy in Dupuytren's disease. *J Hand Surg Br* 1991;16:243-54.
11. **Citron N, Messina JC.** The use of skeletal traction in the treatment of severe primary Dupuytren's disease. *J Bone Joint Surg [Br]* 1998; 80-B:126-9.
12. **Hueston JT.** Limited fasciectomy for Dupuytren's contracture. *Plast Recon Surg* 1961;27:569-85.
13. **Hueston JT.** The control of recurrent Dupuytren's contracture by skin replacement. *Brit J Plast Surg* 1969;22:152-6.
14. **Searle AE, Logan AM.** A mid term review of the results of dermofasciectomy for Dupuytren's disease. *Ann Chir Main Memb Super* 1992;11:375-80.
15. **Brotherston TM, Balakrishan C, Milner RH, Brown HG.** Long term follow-up of dermofasciectomy for Dupuytren's contracture. *Br J Plast Surg* 1994;47:440-3.
16. **Hall PN, Fitzgerald A, Sterne GD, Logan AM.** Skin replacement in Dupuytren's disease. *J Hand Surg Br* 1997;22:193-7.
17. **Logan AM, Brown HG, Lewis-Smith P.** Radical digital dermofasciectomy in Dupuytren's disease. *J Hand Surg Br* 1985;10:353-7.
18. **McCann BG, Logan A, Belcher H, Warn A, Warn RM.** The presence of myofibroblasts in the dermis of patients with Dupuytren's contracture: a possible source for recurrence. *J Hand Surg Br* 1993; 18:656-61.
19. **Kelly C, Varian J.** Dermofasciectomy: a long term review. *Ann Chir Main Memb Super* 1992;11:381-2.
20. **Ketchum LD, Hixson FP.** Dermofasciectomy and full thickness grafts in the treatment of Dupuytren's contracture. *J Hand Surg Am* 1987;12:659-64.
21. **Ebelin M, Leviet D, Auclair E, Lemerle JP, Vilain R.** The treatment of recurrent Dupuytren's disease by scalar incision and firebreak graft. *Ann Chir Plast Esthet* 1991;36:26-30.
22. **Badalamente MA, Hurst LC.** Enzyme injection as a nonoperative treatment for Dupuytren's disease. *Procs 7th Congress of IFFSH*, 1998.
23. **Lappi DA, Martineau D, Maher PA, et al.** Basic fibroblast growth factor in cells derived from Dupuytren's contracture: synthesis, presence and implications for treatment of the disease. *J Hand Surg Am* 1992;17:324-32.