

EARLY RESULTS OF OPEN FASCIOTOMY AS A TREATMENT OF DUPUYTREN'S DISEASE IN ELDERLY PATIENTS

JERZY JABŁECKI, LESZEK KACZMARZYK, ADAM DOMANASIEWICZ,
JANUSZ KACZMARZYK

Subdepartment of Replantation of Limbs, St Hedwig's Hospital in Trzebnica
Kierownik: dr hab. *J. Jabłeczki*

The demand for treatment of Dupuytren's disease by a procedure of limited invasiveness and quick recovery is increasing in accordance with aging of the Polish population. Such a demand is fulfilled by different types of fasciotomy (open, percutaneous needle fasciotomy).

The aim of the study was to assess the early results of the open fasciotomy in elderly patients.

Material and methods. We treated 38 patients (61 fingers) whose mean age was 72 (SD 12) by open fasciotomy; 43 fingers presented stage III Tubiana contracture, 18 stage IV. The pre-operative total passive extension deficit was 123° (78° for stage III group, 111° for stage IV group). All the procedures were performed in outpatient setting. Patients used splint for 5 days, then performed finger – extension exercises and were encouraged to use their hands normally after 1 week.

Results. The evaluation of the results was performed 4 weeks post-op. The greatest improvement in both of the groups was noted in MCP joint – 80% and in PIP joint – 48%, this difference is statistically significant. The general improvement ratio was 76%, greater in stage III group – 82% whereas in stage IV group 69%, but this difference was not statistically significant. All of the wounds healed up to 3 weeks, no complications were observed.

Conclusion. The open fasciotomy is a recommendable short term treatment in patients of advanced age, suffering from stage III and stage IV of Dupuytren's disease.

Key words: Dupuytren's disease, open fasciotomy, recurrence, procedure's invasiveness

The palmar aponeurosis is a complex structure composed of three types of cords that run transversally, longitudinally, and vertically relative to the palm plane. In the finger, the components of the palmar fascia form a complex structure called the lateral digital fascia. Dupuytren's disease (DD) is a proliferative nodular fibroplasia that affects the palmar aponeurosis (1). In the affected aponeurosis, the presence of myofibroblasts, specialized cells that share features of both fibroblasts and smooth muscle cells, is characteristic. These cells are thought to play an important role in the process of pathologic tethering of the connective tissue (2, 3). However, the exact etiopathogenesis remains unclear, and the treatment of choice continues to be surgical (4, 5, 6).

The surgical management of Dupuytren's disease consists of the following approaches:

- 1) total or partial excision of the aponeurosis (radical, local, and regional fasciectomy), and
- 2) division of its diseased bands only (fasciotomy). The latter may be performed using either a closed approach (i.e. percutaneously with a dedicated lancet (7) or an injection needle (8)) or an open approach (i.e. under visual control (4, 5)). The results of surgical treatment are merely satisfactory, and recurrence rates are as high as 50% in a five-year post-operational period (1, 4, 6, 9-12). Many authors are of opinion that the recurrence depends primarily on individual conditions rather than the type and extensiveness of the surgery (1). Indisputably, the greatest therapeutic difficulties are met in advanced contractures, such as grade III and IV, in which complications occur most often (13).

In this setting, the two-step therapeutic approach proposed by Nagay in 1970 seems very

interesting (14). The first step in this approach is an open fasciotomy (OF). According to McCash's open palm technique, the OF leaves the skin incision unclosed, allows for an extension of digits, and may be considered as a "tissular test" that predicts the wound's healing potential. The second step consists of a classic partial fasciectomy that is now performed under much more favorable conditions (4, 5). Many elderly patients, satisfied with the result of the first procedure (OF), waive continuation of the treatment (5, 15).

Since studies examining this approach are scarce (4, 5, 13, 14), the aim of this paper was to present our experience with this method in a selected group of patients.

MATERIAL AND METHODS

Thirty-eight patients (32 men and 6 women; mean age 72 ± 12 years), from whom a total of 63 fingers were operated using the OF technique over a period of three years (January 2003 to December 2005), were enrolled in the study. Only elderly patients with significantly progressed Dupuytren's disease were elected for this procedure. Patients showed disease of grade III and IV, according to Tubiana grading system (13), and a total extension deficit (TED) of either $90-135^\circ$ (43 fingers) or more than 135° (18 fingers). Mean TED of the whole group was 111° (tab. 1).

Patients with more than two fingers affected underwent the operation on only the two digits with greatest contracture in order to prevent extensive wounds. In all cases, the pathologic process of aponeurosis had lasted for more than five years. At least one of the well-established conditions associated with the DD, such as diabetes, alcoholism, or epilepsy, was present in 9 (24%) patients.

The OF operation was performed according to Nagay's guidelines, and in all cases it was an out-patient procedure (4, 5, 14). Generally,

ulnar nerve block was performed (1% Lignocaine) through the carpal sulcus approach (proximally to the pisiform bone). In few cases, infiltration anesthesia was applied to lesion sites on the skin. The incision of the palpable band was made in the region of the distal palmar groove with a sharp-pointed knife (No. 14 Swann-Morton) with a simultaneous extension of the finger (fig. 1, 2). In 23 (60%) patients, an incision on the finger was made below the proximal interphalangeal joint. The wound, which rarely exceeded $0.8 \text{ cm} \times 0.5 \text{ cm}$, was managed with a sterile dressing. In 2 (5%) patients with more extensive wounds, the defect was covered with epidermal grafts.

After the operation, the hand was immobilized for five days with a palmar plaster cast, and at follow-up the immobilization was removed. Patients were encouraged at follow-up visits to practice extension exercises, such as sitting down with the hand placed flat on a chair.

Statistical analysis was performed using Student's test with a significance level of $p=0.05$.

RESULTS

Only 9 (24%) patients reported to the remote follow-up. The remainder of the patients provided following excuses for their absence from the follow-up: worsening of health 10, difficult family or economic situation 9, no response 7, or death of the patient 3. Because of this, the remote follow-up was abandoned in favor of the early postoperational evaluation. This evaluation was performed four weeks ($SD=2.4$ weeks) after the procedures and included all of the patients.

Complete healing of the wound was observed in all of the patients, including those for whom epidermal grafts were used. The course of healing was uncomplicated, and wound management was not reported by the patients as inconvenient. We used the so-called improvement ratio (IR) for evaluation of the results:

Table 1. Pre-operative extension deficit in finger joints

Stage Tubiana	Number of fingers	PED °				TPED °	
		joint MCP	SD	joint PIP	SD	MCP + PIP	SD
III	43	51°	23	30°	15	78°	17
IV	18	73°	18	55°	11	131°	9
Średni CBUW / mean TPED						111°	18°

Note: PED – passive extension deficit; TPED – total passive, extension deficit, SD – standard deviation

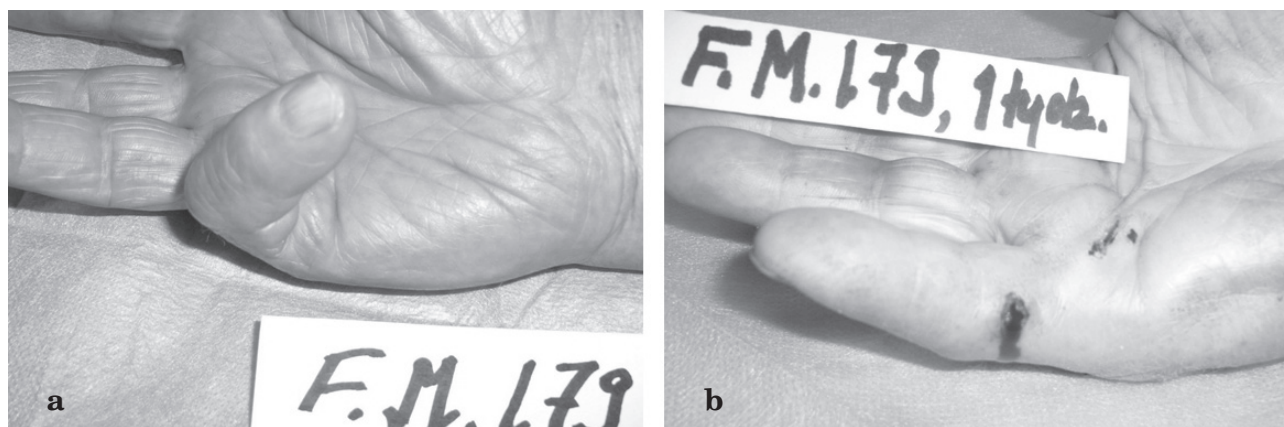


Fig. 1. Contracture of the 5th digit at stage IV in a 87 years old patient; pre-operative state (a), post-operative state (b). Note a nearly complete closure of skin incisions, achieved improvement index – 91%

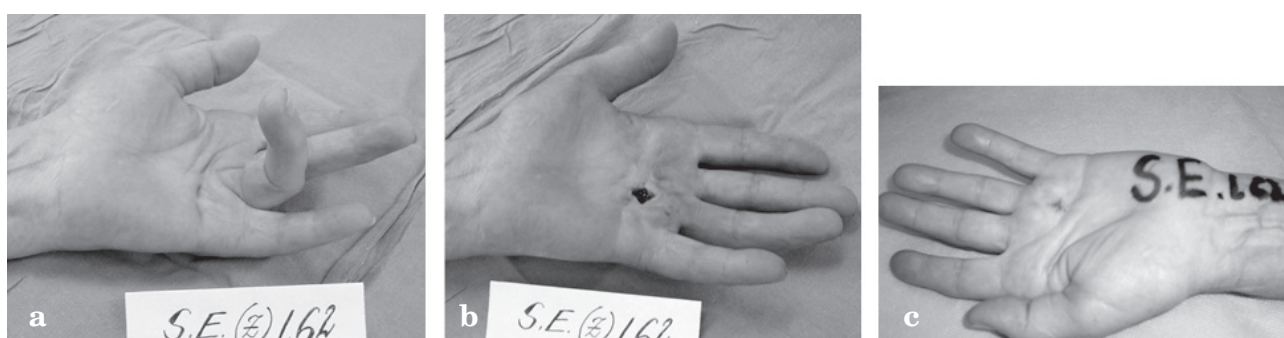


Fig. 2. Contracture of the 4th digit at stage III; depicted are the treatment stages: pre-operative state (a), immediate post-fasciotomy result (note the small size of the wound) (b), result 4 weeks after the operation (c), achieved improvement index – 79%

$$IR = \frac{IED - FED}{IED} \times 100 (\%)$$

(where IED represents the initial extension deficit and FED represents the final extension deficit).

Mean IR for the whole group was 76%. The MCP joint showed the greatest improvement (80%), whereas the mean IR for the PIP joint was only 48%. This difference is statistically significant ($p=0.0028$). Furthermore, the 43 fingers with less advanced lesions (grade III) were characterized by a mean IR 13% higher than that for the fingers with more advanced

lesions (grade IV). However, this difference was not statistically significant ($p= 0.063$) (tab. 2).

According to Bleton, an IR exceeding 50% is considered good (16). Such a result was achieved by 29 (76%) of our patients.

The touch sensibility of the operated fingers was evaluated after the operation and did not differ from that of non-affected fingers (two-point discrimination ca 7-9 mm). The flexion range, although not studied in details, did not worsen. All patients were very satisfied with

Table 2. Postoperative result achieved at mean 4 weeks

Tubian stage	Number of fingers	Improvement ratio of TPED (%)					
		general	SD	joint MCP	SD	joint PIP	SD
III	43	82%	26	84%	16	51%	21
IV	18	69%	13	71%	9	39%	12
Mean improvement		76%	19	80%	18	48%	17

Note: TPED – total passive extension deficit, SD – standard deviation

the results of surgery. They resumed their normal activity after a maximum of ten days after the operation.

DISCUSSION

The decision to perform an operation should take into account both the objective of maintaining the postoperational improvement for years and a knowledge of the acceptable risk for the patient. DD has an important genetic component and as McGrouther wittily notes, "genes do not respond to surgical treatment" (1). Recurrence is intrinsic to this disease, and Bleton suggests that it does not depend on the type of operation (16). Instead, its rate seems directly proportional to the length of follow-up (1, 17). Clinical observations support this statement: five, ten, and more than ten years after the operation, recurrence appears in 54-63% (10), 66% (11), and 66-77% (9) of patients, respectively.

The intra- and postoperational mechanical irritation of fibroblasts seems crucial to the pathophysiology of the disorder. Irritated fibroblasts release the transforming growth factor beta (TGF- β 1), which in turn transforms the fibroblasts into myofibroblasts (3).

In contrast to oncologic treatment, DD therapy does not require the complete excision of the pathologic lesions of aponeurosis to obtain a therapeutic effect. Instead, it is necessary only to change the hand's biomechanics in such a way as to eliminate the tension exerted over the remaining parts of pathologic bands (1). Skoog pointed out that leaving the transversal cords, which do not take part in transmitting the tension along the longitudinal axis of the hand, does not affect the recurrence rate. Because of this, he advised others not to excise these cords (18). This same reasoning suggests that if the skin elasticity is conserved and the adipose layer well-developed, a simple incision of the cord will separate the endings of the cord, lead to their tethering, and hide them in the adipose layer that eventually prevents the cord from transmitting the tensions (1, 19, 20).

Such an effect cannot be obtained when the hand integument is rigid and infiltrated. In this case, Moermans recommends at least a partial excision of the diseased cords (21). Thus, the election of a therapeutic approach appropriate for a given patient is of great importance. A bending contracture of MCP joint, produced

because the aponeurosis' longitudinal cord resembles a string, can be easily compensated for with a transcutaneous incision that leaves only a small (3-5 mm) wound. Independent of the operational technique, a contracture in the PIP joint is always a more serious problem since there are more structures (the central, spiral, Natatory, and Greyson cord) involved in its formation (4, 7). Furthermore, the PIP joint, in contrast to MCP, has poor toleration of long-lasting contracture. Because of this, even after a radical fasciectomy, as proposed by McFerlane (17), the contracture persists and can be reduced by a capsulotomy, joint distraction with a distraction device and others (1, 22). It is then clear why the IR of PIP joint that we observed in this study was less than the IR of the MCP joint.

McCash proposed a method known as the open-palm technique, in which an extensive wound is left unclosed after a partial or total fasciotomy, and this approach is now well-established with 50 years of tradition (23, 24). This technique decreases the risk of complications associated with advanced DD, such as a hematoma, necrosis of the skin, or limb's atrophy, to a minimum. The small number of published studies examining OF makes the comparison of the results difficult. Bryen and Ghorbal observed no deterioration in the recovery of function in 55% of patients five years following the operation (24). This result does not vary significantly from the one obtained with more radical operations. Similarly, Colville obtained mean IR of 56% in 137 fingers directly after the surgery. After one year, the IR decreased to 49% (7). It seems that relatively quick recurrence is the only drawback to OF.

Lermusiaux proposed a form of fasciectomy consisting of multiple punctures of the diseased aponeurosis band with a size 20 injection needle (8). Bleton et al. operated 110 fingers in 67 patients in this way, and they obtained a TPED of 85% in 55 fingers (16). According to this author's grading system, a TPED improvement is considered as good if it exceeds 50%. In our study, the TPED improvement was good in 29 patients (76%). Rijsen et al. compared 166 fingers operated by either a needle fasciotomy or a partial fasciectomy. Contractures were reduced similarly in each group, but the fasciotomy group showed no complications while the fasciectomy group showed 5% (25). A needle-closed fasciotomy often becomes an open fascio-

tomy because of finger extension, and the risk of nerve damage increases considerably (19, 26). Thus its superiority over OF is rather doubtful.

On one hand, the expectations of patients over 65 years of age are indisputably distinct from those of younger patients. The majority of elderly patients prefer operations associated with the least operational risk that also guarantee immediate recovery and improvement, even if recurrence of the disease will be faster. On the other hand, however, the intensity of pathologic processes is assumed to be less in elderly patients (27). The opportunity

for DD treatment that does not require hospitalization and is virtually free from both local and anesthesia-associated complications. Therefore, the open-palm technique provides a very attractive therapy for this group of patients.

CONCLUSIONS

1. Open fasciotomy provides an immediate and significant correction of digital contracture caused by Dupuytren's disease.
2. This approach is recommended for elderly patients who prefer non-invasive treatment.

REFERENCES

1. McGrouther DA: Dupuytren's contracture. W: Green's Operative Hand Surgery, Green DP (red) Elsevier Churchill Livingstone, wyd 5, Philadelphia 2005; 159-85.
2. Tomasek JJ: Cellular structure and biology of Dupuytren's disease. *Hand Clin* 1999; 15(1): 21-34.
3. Bisson MA, McGrouther DA, Mudera V et al.: Different characteristics of Dupuytren disease fibroblasts derived from either nodule or cord: expression of alpha - smooth muscle actin and and the response to stimulation by TGF-b1. *J Hand Surg (Br)* 2003; 28B (4): 351-56.
4. Nagay B, Deskur: Przykurcz Dupuytren: etiopatogeneza - epidemiologia - klinika. *Pol Przegl Chir* 1992; 64(2): 128-34.
5. Nagay B: Two-stage operation. W: Dupuytren's disease-biology and treatment, RM McFerlane, DA Grouther, MH Flint (red), wyd. 1, Churchill Livingstone Edt. Edinburgh, London 1990: 337-40.
6. Jagieliński JW: Ocena wyników leczenia operacyjnego przykurczu Dupuytren z uwzględnieniem obiektywnych i subiektywnych parametrów sprawności ręki. Praca doktorska, PAM, 2005.
7. Coville J: Dupuytren's contracture - the role of fasciotomy. *The Hand* 1983; 15: 162-66.
8. Lermusiaux JL, Debeyre N: Le traitement medical de la maladie de Dupuytren. W: Seze S, Ryckewaert A (red) L'Actualite Rhumatologique, Expansion Scientifique Francaise, Paris 1980, 338-43.
9. Norotte G, Apoil A, Travers V: Resultats a plus de 10 ans de maladie Dupuytren: a propos cinquante huit observation. *Sem Hop Paris* 1989; 65: 1045-48.
10. Borowiec K: Ocena wyników operacyjnego leczenia choroby Dupuytren. *Pol Przegl Chir* 1992; 64(2): 141-45.
11. Leclercq C, Tubiana R: Resultat a long terme des aponeurectomies pour maladie de Dupuytren. *Chirurgie* 1986; 112: 194-97.
12. Dobrska E: Ocena skuteczności wybranych metod leczenia choroby Dupuytren. *Pol Przegl Chir* 1992; 64(2): 135-40.
13. Tubiana R, Huston JT: Dupuytren's disease, Churchill Livingstone, wyd.1, London 1974.
14. Nagay B: Przykurcz Dupuytren. *Wiad Lek* 1970; 23: 1979-83.
15. Jedwabiński M, Grygiel M, Biliński P: Ocena wyników dwuetapowego leczenia operacyjnego zaawansowanego przykurczu Dupuytren. *Chir Narz Ruchu Ortp Pol* 1996; 61(supl. 4 B): 241-44.
16. Bleton R, Merciereau D, Alnot J-Y: Treatment of Dupuytren's disease by percutaneous needle fasciotomy. W: Current practice in hand surgery. Saffar P, Amadio PC, Foucher G (red), Martin Dunitz, London 1997; 187-193.
17. McFerlane RM: Current status of Dupuytren's disease. *J Hand Surg (Am)* 1983; 8(5): 703-08.
18. Skoog T: The transvers elements of the palmar aponeurosis in Dupuytren's contracture. *Scand J Plast Surg* 1967; 1: 51-53.
19. Rowley DI, Couch M, Chesney RB et al.: Assessment of subcutaneous fasciotomy in the management of Dupuytren's contracture. *J Hand Surg (Br)* 1984; 9: 163-66.
20. Shneider LH, Fankin, FM, Eisenberg T: Surgery of Dupuytren's Disease; A review of the open palm method. *J Hand Surg (Am)* 1991; 11: 23-27.
21. Moermans JP: Long term results after segmental fasciotomy for Dupuytren's disease. *J Hand Surg [Br]* 1996; 21: 797-800.

22. Messina A, Messina J: The TEC (Continuous Extension Technique) for severe Dupuytren's contracture of the fingers. *Plast Reconstr Surg* 1991; 92: 84-89.
23. McCash RC: The open- palm technique in Dupuytren's contracture. *Brit J Plast Surg* 1964; 17: 271-74.
24. Foucher G, Cornil C, Lenoble E: Open palm technique for Dupuytren's disease. A five year follow-up. *Ann Chir Main Memb Sup* 1992; 32: 362-66.
25. Rijsen AL, Gerbrandy FS, Ter Linden H et al.: A comparison of the direct outcomes of the needle fasciotomy and limited fasciectomy for Dupuytren disease: 6 weeks follow-up study. *J Hand Surg [Am]* 2006; 31(5): 717-25.
26. Bryan RA, Ghorbal MS: The long term results of closed palmar fasciotomy in management of Dupuytren's disease. *J Hand Surg (Br)* 1988; 13: 254-56.
27. Wilbrandt S: The sex ratio and rate of reoperation for Dupuytren's contracture in men and women. *J Hand Surg [Br]* 1995; 24: 456-60.

Received: 8.08. 2007 r.

Adress correspondence: 55-100 Trzebnica, ul. Prusicka 53

COMMENTARY

Management of Dupuytren's disease has a long-term history, and its diversity is evidence of the limited efficacy. This mostly concerns conservative therapy, which only slows the development of contractures. Surgical intervention remains the only practical method. Radical excision of longitudinal cicatricial fascicles remains most effective, in combination with the removal of transverse fibers. In spite of the fact that the surgical procedures are not complicated, in the case of advanced changes the preparation of cicatricial fascicles might prove difficult in not damaging vasculo-neural fascicles and tendons. Due to the existing joint contractures, full digital extension is not always observed, although it is not necessary for proper functioning of the hand. Full extension or significant improvement can be obtained after physiotherapy or during the course of wound healing by first intention. This is not always true, since flap plasty used for the closure of skin defects, which develop during the course of contractures, does not always prove to be surgical strength. Due to the fact that simple V-Y plasty might pose a problem, some surgeons perform skin grafts (1) or, even worse, leave the wound to heal by second intention.

The mentioned difficulties considering the preparation and closure of skin defects have led towards interest in simple procedures, such as subcutaneous and intracutaneous incision of cicatricial fascicles of the palmar aponeurosis.

Supporters of the above-mentioned method underline the simplicity and minimal invasiveness of fasciotomy, although often disregard the effectiveness of treatment, duration of healing, and frequency of recurrence.

The extent of the operation is insignificant, although the same can be attributed to classical operations considering palmar aponeurosis. Conduction anesthesia and compression bandage are preferred, although infiltration anesthesia is sufficient, enabling surgery regardless of patient age or condition. Our own experience concerning 300 operated patients confirmed the above-described preference (2).

In publications concerning fasciotomy, most objections are connected with wound healing by granulation, which is contrary to the logic and principles of plastic surgery. Cicatricial contractures are usually more significant in comparison to those observed after skin graft operations.

Thus, distant results are scarce and limited to only 24% of operated patients. This is probably connected with numerous concomitant diseases and patient age, although ineffective treatment should not be excluded.

In conclusion, the principle that "simple is beautiful" does not always concern the described operative method, which should be limited to exceptional cases. In the remaining cases, the excision of the palmar aponeurosis seems most effective. However, the above-mentioned scena-

rio does not lead towards complete recovery, nor does it protect from recurrence, although, due to smaller tissue scarring, it enables higher efficacy of eventual reoperations.

REFERENCES

1. *Hueston J*: Dupuytren's contracture. *J Hand Surg (Br)* 1993; 18(6): 806.
 2. *Kobus K, Wójcicki P, Dydymski T* et al.: Evaluation of treatment results of patients with Dupuytren's contracture – our clinical experience. *Ortop Traumatol Rehabil* 2007; 9(2): 11-12.
- Prof. dr hab. dr h.c. *Kazimierz Kobus*
Ordynator Oddziału Chirurgii Plastycznej
w Polanicy Zdroju
Kierownik Kliniki Chirurgii Plastycznej AM
we Wrocławiu