

From the Orthopedic Hospital, Copenhagen.  
(Chief Surgeon: POUL GUILDAL).

## On the Treatment of Dupuytren's Contracture.

By

FRIDRIK EINARSSON.

Copenhagen.

Dupuytren's contracture was described by Sir ASTLEY COOPER in 1822 and by DUPUYTREN in 1832.

### Etiology and Pathogenesis.

The cause of the disease has not yet been fully elucidated, but a number of different factors seem to be responsible. In numerous cases heredity no doubt plays a part. Extremely varying figures (6—72 per cent.) have, however, been stated by the various authors reporting its frequency as a causative factor. KEEN found a family history in 50 out of 198 cases. BUNCH observed the lesion in father, son, and grandson of one family, the male members of which were said to have been affected with Dupuytren's contracture for a period of 300 years. Several reports have been published of the disease encountered in identical twins.

Various authors attach much importance to manual work as well as trauma, a single injury or repeated minor traumata. JANSSEN takes the view of a fibroplastic diathesis and LOEWY considers "an hereditary tendency to fibrous hyperplasia" to be the essential factor.

The importance of focal infection has been emphasized, especially by American authors.

KROGIUS has advanced an extremely interesting theory, viz. that the contracture arises in consequence of a disturbance in the development of the superficial muscles of the hand (musculi flexores breves manus superficiales) no more present in man or the ape, but demonstrable in the human embryo.

Dupuytren's contracture is about 7 times as common among men as among women (Table I).

Table I.

Sex.

Author	Cases	Males	Females
KEEN <sup>1</sup> .....	227	187	40
ANDERSON <sup>1</sup> .....	39	25	14
BLACK <sup>1</sup> .....	240	221	19
BYFORD <sup>1</sup> .....	38	35	3
KANAVEL, KOCH, MASON .....	29	27	2
MEYERDING .....	273	241	32
Writer's Material .....	111	101	10
	957	837	120

The frequency increases with advancing age. 25 out of 90 cases reported by KEEN had acquired the deformity before the age of 30, but severe cases seldom are observed before the age of 40. In MEYERDING's material the mean age was 54.

Some authors emphasize the common occurrence of Dupuytren's contracture in labourers engaged in hard manual work. Among 1,021 brewery workers in Copenhagen BONNEVIE *and co-workers* observed the disease in 20.9 per cent. It was found to be twice as common among the workmen who had been handling cases containing filled bottles for a long period as among their colleagues. NIEDERLAND observed the deformity in 17.8 per cent. of textile workers, more than 40 years of age, engaged in especially hard manual work, whereas an examination of 112 clerks above the same age only revealed 0.9 per cent. to be affected with the disease.

Hospital statistics do not, on the other hand, indicate the significance of hard work suggested by the investigations mentioned above (Table II).

LUND found Dupuytren's contracture to be 2—3 times more common among epileptics than among a control material consisting of old and elderly labourers in Copenhagen. NOBLE SMITH found a percentage of 18.3 among the men of the London Workhouses.

According to the literature Dupuytren's contracture occurs with

<sup>1</sup> Quoted from KANAVEL, KOCH & MASON.

striking frequency in association with certain other diseases, viz. plantar fibroma, peri-arthritis of the humerus, plastic induration of the penis, heloderma. The causal relationship is unknown.

Table II.

*Occupation.*

Author	Cases	Manual Work	Immaterial Work
KEEN <sup>1</sup> .....	123	49	74
BLACK <sup>1</sup> .....	131	63	68
BYFORD <sup>1</sup> .....	38	24	14
KANAVAL, KOCH, MASON .....	29	10	19
MEYERDING .....	273	123	150
Writer's Material .....	111	57	54
	705	326	379

**Pathological Anatomy.**

The disease starts in the palmar aponeurosis, especially in the superficial, longitudinal layers. Most authors agree that inflammatory changes and ordinary scar tissue may be ruled out. The initial stage is characterized by increased vascularization (JANSSEN) and a proliferation of connective tissue with a round cell infiltration almost reminding of sarcomatous changes. A tendon-like connective tissue containing few cells is a peculiarity of the more advanced stage. The aponeurosis is subject to a shrinkage and shortening causing the contracture. The subcutaneous fat is reduced or entirely lost. As the disease spreads to the deeper layers of the aponeurosis and its extensions, the digital arteries and nerves become embedded in the fibrous tissue. In severe cases they may become displaced as much as a fingerbreadth (MASON), a fact which should be kept in mind during an operation, if any.

The flexor tendons are never involved in the pathological process.

**Symptoms.**

In mild cases the disease manifests itself in the form of firm nodules, approximately the size of a pea, below the palmar skin, as a rule localized to the base of the ring or little finger, less frequently

<sup>1</sup> Quoted from KANAVAL, KOCH & MASON.

the middle finger. A situation at the base of the index finger or the thumb is rare in the initial stage. At this stage the patient is not embarrassed by the deformity, there is no pain or tenderness, and the mobility is still free. The disease progresses, however, though generally slowly. The skin becomes involved early, the nodules gradually merge, forming hard cords projecting above the level of the skin and extending from the palm on to the finger in question. At the same time the disease spreads to other parts of the aponeurosis and often, though not always, to other fingers. A flexion contracture results, first preventing an active extension of the finger, later even a passive extension. As the aponeurosis shrinks and shortens, the finger is flexed more and more, ending in pronounced cases in a maximum flexion with the finger-tip in contact with the palm. In a few cases the patient experiences pain and tenderness, because the normal protective tissue of the palm — skin, aponeurosis, and subcutaneous fat — has degenerated into fibrous tissue. As a rule, however, the inconvenience is due to the fact that the patient is unable to extend the finger which is in the way of the movements.

The deformity generally is bilateral, but sometimes is localized to one hand only, as a rule the right one (Table III).

Table III.

*Hand Affected.*

Author	Cases	Bilateral	Right hand	Left hand
KEEN <sup>1</sup> .....	184	103	58	23
ANDERSON <sup>1</sup> .....	39	24	10	5
HUME <sup>1</sup> .....	118	40	57	21
BLACK <sup>1</sup> .....	240	104	89	47
BYFORD <sup>1</sup> .....	38	25	9	4
KANAVEL, KOCH, MASON .....	29	17	4	8
MEYERDING .....	273	175	69	29
Writer's Material .....	111	53	35	23
	1032	541	331	160

Similar changes are sometimes encountered in the plantar aponeurosis. It is a peculiar feature that the lesion has been localized to the *tibial part* of the aponeurosis in all the published cases (KLOSSNER).

<sup>1</sup> Quoted from KANAVEL, KOCH & MASON.

## Treatment.

DUPUYTREN himself realized that the contractures did not yield to *extension treatment*. If instituted at an early stage energetic *massage* and *redressing exercises* may counteract, or at least postpone the contracture (JONES & LOVETT). Emollient *ointments*, *medical diathermy* and other forms of *thermotherapy*, *iontophoresis*, *radium* and *roentgen therapy* have been tried without definite results. A. A. DAVIS, KLAPP and a few others consider *fibrolysin injections* to be of a certain effect, alone or better in connexion with operation.

For the sake of completeness it should be mentioned that STAHNKE obtained good results treating 12 cases with injections of molten human fat (from lipomata etc.). Although the thickening remains unchanged, the function improves. The treatment may be tried in inoperable cases and in very old patients (LEXER).

The *operative treatment* follows three principles: *excision of the palmar aponeurosis*, *division of the palmar aponeurosis*, and *digital amputation*.

*Dupuytren's operation* consisted of transverse incisions,  $2\frac{1}{2}$  cm. in length, through the skin and fascia in numbers necessary to straighten the finger. He left the wounds to granulate and splinted the hand with stretched fingers.

*Subcutaneous division of the palmar aponeurosis* or *Adams' operation* (suggested by Sir ASTLEY COOPER as early as 1822). 10—15 incisions may be required in order to straighten the fingers completely. The operation is not an easy one, it being difficult, without the aid of the eyes, to avoid injuring vessels and nerves, a factor of immense importance, if a satisfactory result is to be obtained.

A thorough excision of the palmar aponeurosis followed by adequate post-operative measures is, however, the best and most radical method of treatment. The earlier the operation is done, the better are the results. According to KANAVEL, MOURE and others a recurrence is best avoided by removing not only the contracting cords, but as large a portion of the aponeurosis as possible. It is especially important that all the fascial slips to the interosseous membrane, metacarpal bones, and phalanges have been removed. Most authors also recommend the removal of skin areas exhibiting pathological changes which should be replaced

by skin grafts of full thickness. LEXER removes the skin in all cases (shaded area in drawing), whereas a few authors systematically preserve it (GILL, DESPLAS).

Various cutaneous incisions have been employed. Some authors consider the form of incision to be of great importance, whereas others regard it as subordinate to a thorough removal of the aponeurosis.

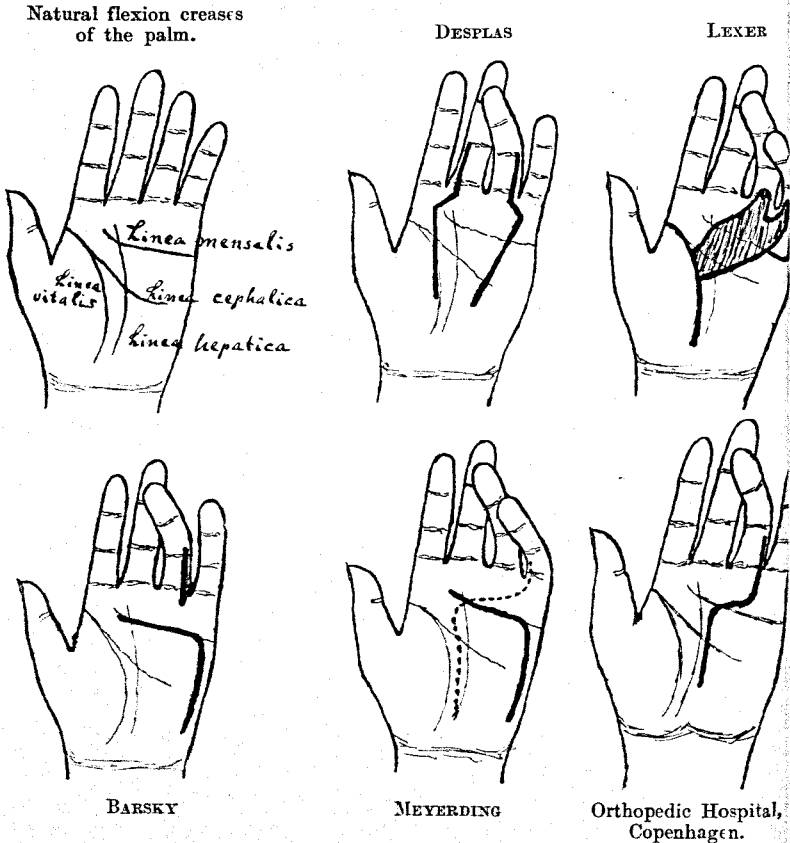


Fig. 1. Various forms of incision.

KANAVAL employs longitudinal as well as transverse incisions, according as the nodules extend in a longitudinal or transverse direction.

KOCH also adapts the cutaneous incision to the individual case,

but points out that it should be made along the natural creases of the palm.

ROUTIER, BUSCH and others use V-shaped or Y-shaped incisions.

DESPLAS applies the cutaneous incision shown in the drawing. The incisions form a bridge of skin which is raised during the dissection, whereupon it is replaced and sutured.

GILL makes an incision parallel with the *linea mensalis* and transversely on the base of the finger. He "has never found it necessary to remove the skin".

HUTCHINSON'S operation (1917). After the aponeurosis has been excised the base of the 1st phalanx is removed through a dorsal section and the extensor tendon is shortened.

The utmost caution should be exercised during the operation. One must be especially careful not to injure blood vessels and nerves which have become embedded in the fibrous tissue. Possibly blood vessels and nerves have to be sectioned separately and pulled aside. A wound heals more slowly in the palm than anywhere else except on the sole of the foot. The healing may be hastened by exerting an even pressure upon the entire surface of the wound. The best means of obtaining this end is the "sea sponge compression" suggested by BLAIR.

Most authors fix the stretched fingers with a splint for some time, about 3 weeks, and go on using the splint for the night for a period up to several months. KANAVAL, however, has reduced the splinting to 8—10 days which procedure in his opinion secures a quicker return of function.

### Prognosis.

In 1932 DESPLAS had operated upon 8 patients, with excellent results in 5 and fair results in 3. In 1934 he had operated upon 32 and obtained "excellent results".

Up to 1932 A. A. DAVIS had performed excision of the palmar aponeurosis on 31 hands. On after-examination only 12 of them were excellent, 10 had a partly and 3 a fully developed recurrence. In 6 cases the anatomical result was good, but the function was poor on account of tenderness or insensibility of the fingers.

Besides, he applied subcutaneous division of the palmar aponeurosis in 8 cases, 6 with excellent results, 1 with a partly, and 1 with a fully developed recurrence. The follow-up extended over a period of 1—5 years.

3 hands had been treated with fibrolysin injections. 2 had a partly, and 1 a fully developed recurrence.

In 3 cases the involved finger had been amputated.

For a period of 30 years LEXER has operated upon approximately 200 patients with "very few poor results or recurrences".

KANAVAL and co-workers have published a report of 29 cases operated upon in the course of 12 years. 20 were excellent (2 of which, however, exhibited new nodules, but at a distance from the operative incision), in 5 cases the results were fair, 2 had recurrences, and 2 had not been followed up long enough.

Up to 1936 MEYERDING had operated on 117 hands of 84 patients. 13 of these hands had been operated upon elsewhere previously. Excision of the palmar aponeurosis was made in 97 cases with excellent results in 55, fair in 11, and poor in 8. The possessors of the remaining 23 hands were dead or could not be traced.

Subcutaneous division of the palmar aponeurosis was made in 13 cases, with good results in 5, fair in 2, poor in 2. 4 hands could not be traced.

Besides, digital amputations were performed in 6 cases.

Teneotomy was done in one case with a poor result.

Up to the year 1940 the same author had seen 315 patients and operated upon "more than 100". He had obtained "satisfactory results in about 90 per cent."

S. L. KOCH has previously reported 29 cases and later operated upon 18. His results are "constantly improving".

### Writer's Material.<sup>1</sup>

During the period 1928—43 111 patients affected with Dupuytren's contracture have been treated at the Orthopedic Hospital in Copenhagen. 101 were males and 10 females.

The youngest patient was 17 and the oldest 76, mean age 51. The mean age among the operated patients was 50, the youngest being 25 and the oldest 66.

The occupation of the patients may be seen from Table II.

The duration of the disease had been from 1 month to 40 years, on an average a little more than 6 $\frac{1}{2}$  years.

Among the 111 patients 164 hands were affected with Dupuytren's contracture. Bilateral involvement was most common, next in order the right hand alone (Table III).

<sup>1</sup> My sincere thanks are due to Dr. KAREN RØJEL of Odense for leaving me the material, a great part of which had been followed up.



The writer has attempted to classify the disease into grades on the basis of the data obtainable from the case records. The classification in all essentials is according to MEYERDING:

- Grade 0: Nodules in the palmar aponeurosis, sometimes involving the skin, but no flexion deformity.
- Grade I: In addition to the conditions already mentioned, major or minor flexion deformity of one finger only.
- Grade II: Flexion deformity of more than one finger, nowhere attaining 60°.
- Grade III: Flexion deformity of more than one finger, exceeding 60° in at least one.
- Grade IV: Major or minor flexion deformity of all fingers.

As mentioned above the deformity as a rule affects the ring or little finger. The distribution in our material is as follows:

Thumb .....	6 times
Index finger .....	10 »
Middle » .....	36 »
Ring » .....	87 »
Little » .....	88 »

84 of the 164 hands were submitted to operation, 80 not. Table IV sets out the degree of the deformity of all the affected hands.

**Table IV.**

*Degree of Deformity of the 164 Hands.*

Grade	Excision of palmar aponeurosis	Digital amputation (sometimes supplemented with excision of palmar aponeurosis)	Not operated	Total
0 .....	10	—	16	26
I .....	34	8	24	66
II .....	13	1	20	34
III .....	11	7	19	37
IV .....	—	—	1	1
	68	16	80	164

### Operative Technique.

Considering that the material has been in the hands of different surgeons and that it extends over a period of 16 years witnessing a changing technique, the operation of course has been performed in various ways. The skin incision generally has been

adapted to the nature of each individual case, being S-shaped, cross-shaped, or, with increasing frequency during the latter years, as shown in the drawing. During recent years there has been an increasing tendency to wide excision instead of a removal of the contracting cords only.

In 7 cases only was the skin of the palm sacrificed and substituted by a skin graft, once by the method of THIERSCH, another time by a pedunculated graft from the abdomen, and in the remaining cases with KRAUSE'S flaps. All the transplants "took" without complications.

In the case of amputations the soft parts of the amputated finger often were applied to cover a defect resulting from the excision of the palmar aponeurosis.

Usually the operation was bloodless, performed in a number of cases under local, though as a rule under general anæsthesia. Mostly dry dressing. When dealing with skin grafts and in some other cases, e. g. of injury to the skin during operation, the bandage applied has been a "vaselin net" (i. e. vaselin on a single layer of extra coarse-meshed gauze) and sponge compression consisting of an ordinary sea sponge wrapped in a piece of dry gauze. In about half the cases the hand was immobilized in a splint with the fingers in extension. The splinting often was continued for the night up to several months.

The skin sutures are removed on the 14th post-operative day, and active movements are instituted. In case of slow restoration of function, physical therapy, exercise, warm hand baths, and often iontophoresis with potassium iodide. A few cases of hypertrophic scars have been treated with roentgen.

Excision of the palmar aponeurosis was employed in the case of 68 hands of 62 patients. 2 of these hands had previously been operated upon elsewhere, in the one case 5 times.

62 of the 68 hands have been followed up for a period ranging from 6 months to 12 years. The follow-up period was less than a year in the case of 4 hands only. 40 have been followed up for 2 years or longer, 27 for 3 years or longer.

*In 43 cases or 69 per cent. the results were excellent.*

This group includes 6 hands which later have developed nodules, but at a distance from the operative incision and without further symptoms. In one case the result is excellent as far as the contracture is concerned, the scar looks satisfactory, there is no tenderness or flexion deformity and the fingers spread normally.

but there is hyperæsthesia and when the hand is clenched the middle and ring fingers are 2 cm. and the little finger 4 cm. short of reaching the palm. It was, however, considered warrantable to include the case in this group, considering that a roentgen examination revealed arthritis of the finger joints.

*In 7 cases or 11 per cent. the results were fair.*

All the hands of this group are capable of working. In one case the operated finger is 2 cm. short of reaching the palm when the hand is clenched. The remaining hands could be clenched freely. In no case did the flexion contracture exceed  $20^{\circ}$ , but there was some paræsthesia, hypæsthesia or tenderness, cicatricial hypertrophy or a slight tension. If these conditions were pronounced, the case was classed with the poor results.

The group includes 3 patients exhibiting the initial stages of minor recurrences, but without tenderness, tension, or limited motion.

*In 12 cases or 20 per cent. the results were poor on account of recurrences, tenderness, hypertrophic scars, severe sensibility disturbances, or flexion deformity of more than  $20^{\circ}$  (cf. the case histories).*

16 hands of 12 patients were treated with amputation of the affected finger, and as a rule simultaneous removal of the adjoining aponeurosis. The little finger was removed in 11 cases, the ring finger in 4 cases, and the middle finger in 1 case.

Indication to amputate as a rule was constituted by severe articular contracture, especially when accompanied by subluxation, but sometimes amputation was preferred by the patient, who wanted to regain the use of the hand as quickly as possible, disregarding the cosmetic result.

13 of these hands were after-examined. 3 had recurrences with contracture of the adjoining fingers, but the remaining 10 are satisfactory.

The number of amputations, 16 out of 84 operations (19 per cent.) is high when compared with MEYERDING's figures, viz. 6 out of 117 (5 per cent.). This is not, however, the only striking difference between the two materials. Operation was performed in 74 out of the 111 patients constituting the writer's material (67 per cent.), whereas MEYERDING of the Mayo Clinic reports operation of "more than 100" of 315 patients up to 1940 (about 34 per cent.).

According to J. S. DAVIS the material reported by MEYERDING of 117. operated hands was the largest material reported from any single clinic up to 1936. The writer has not been able to find a larger material in the literature accessible for the present. In view of the limited size of the materials, a comparison of the results is of minor interest (Table V).

Table V.

## Results.

Author	Excision of palmar aponeurosis					Division of the palmar aponeurosis						
	Total	After-examined	Excellent	Fair	Poor	Total	Excellent	Fair	Poor	Digital amputation	Fibrolysin injection	Tenotomy
KANAVEL, KOCH, MASON 1929 . . . .	29	27	20 (74 %)	5 (19%)	2 (7%)							
DESPLAS 1932 . . . .	8	8	5 (62 %)	3 (38%)								
A. A. DAVIS 1932 . .	31	31	12 (39 %)	10 (32%)	9 (29%)	8	6	1	1	3	3	
MEYERDING 1936 . .	97	74	55 (74 %)	11 (15%)	8 (11%)	13	5	2	2	6		1
Writer's Material 1944 . . . . .	68	62	43 (69 %)	7 (11%)	12 (20%)							16
	233	202	135 (67 %)	36 (18%)	31 (15%)							

## Discussion — Conclusion.

Dupuytren's contracture has been known as an independent disease for the last one and one-quarter century, but even now its etiology is not clear. Several factors seem to play a part. The essential causes presumably are heredity and minor traumata. The significance of the trauma is indicated by a far higher frequency among labourers than among clerks and people of similar occupation, and moreover by the facts that the deformity is about 7 times as common among males as among females, that the onset as a rule occurs in the right hand, that it never is encountered in children, and that it is rare in early life, but increases in frequency with advancing age.

Numerous patho-anatomical investigations have been made, but the nature of the disease has not been fully elucidated. The onset is characterized by proliferating, amply vascularized con-

nective tissue with marked round-cell infiltration, in advanced stages passing into tendon-like connective tissue with few cells.

The discomfort is due to a flexion contracture of the fingers. The pain and tenderness sometimes experienced arise in consequence of the transformation of the aponeurosis into firm connective tissue, exerting a pressure upon blood vessels and nerves.

The treatment of choice is excision of the palmar aponeurosis in cases where it is practicable. Hardly any effect can be expected to result from physical therapy, though redressing exercises may contribute to delay the contracture. Fibrolysin injections were only attempted in the case of one patient before he entered the hospital. The injections were of no effect whatever, and the hospital has not felt tempted to try this method of treatment.

The incision should be made along the natural creases of the palm, an incision across the creases being apt to destroy an otherwise satisfactory result by the formation of a tense, hypertrophic cicatricial bridge giving rise to fissures and pain. An incision in the finger should be antero-*lateral*.

The excision of the aponeurosis is most easily accomplished when the mobilization is begun proximally, at the apex of the aponeurosis which may be raised with a forceps and pulled downwards. With the aid of a fine knife or scissors all the fascial strips are carefully dissected free of the surrounding tissue. While mobilizing the aponeurosis the surgeon should be extremely careful not to damage the blood vessels and nerves embedded in the fibrous tissue and which may be displaced as much as the width of a finger (MASON). For this reason a bloodless operative field is to be preferred.

Before the wound is closed, the hæmostasis must be complete. Post-operative hæmorrhage is an annoying complication which may compromise the healing and delay the restoration of function.

General anæsthesia is preferable to local anæsthesia, the risk of post-operative hæmorrhage being less.

A total removal of the aponeurosis would be most desirable, but it is technically impracticable. On the other hand, a systematic removal of the aponeurosis in line with the three ulnar fingers may be accomplished, and considering that the disease in most cases is localized to this area, such a procedure presumably would diminish the risk of recurrence.

Affected skin areas should be removed and replaced by skin grafts of full thickness. KANAVAL even recommends the removal

of skin injured during the operation, contending that such skin has a poor tendency to heal. His experience is not in accordance with ours. We have obtained excellent results in several cases in which the skin had become badly lacerated during the operation.

Dressing with sea sponge compression is to be recommended. The use of a hand splint may be discussed. KANAVAL, who formerly used a hand splint for a few weeks, has shortened the period to 8—10 days, maintaining that he obtains a more rapid restoration of function by this method. In case of a tendency to contracture of a finger we would, however, recommend a splint for the night for some length of time.

Hot hand baths are the best remedy against post-operative tenderness and articular stiffness. Iontophoresis with potassium iodide also has been applied with good results at the Orthopedic Hospital.

When is an operation indicated?

*In mild cases occurring in early life* it is advisable to excise the palmar aponeurosis as a prophylactic measure, since the deformity always is progressive, though slowly in most cases.

*In mild cases occurring at a mature age* (about 50) one must await developments, since these patients have a chance of escaping further symptoms on account of the slow progression.

*Severe cases occurring at a mature age* call for an operation, if the patient is embarrassed by the deformity. If the general condition is satisfactory and the tendency to heal is expected to be good, excision of the palmar aponeurosis should be performed, but a severe articular contracture requires digital amputation. The soft parts from the amputated finger may successfully be applied to cover a defect in the palm left by the excision of the aponeurosis. In several cases amputation is an excellent form of operation and the patient can as a rule quickly return to his work.

### Case Histories.

For lack of space the writer is unable to report all the case histories and therefore has chosen those exhibiting a poor operative result, which presumably are of most interest.

No. 1. — Left hand.

Case Rec. 2245/35. Painter, aged 50. First seen on June 12, 1935. An advancing Dupuytren's contracture had for several years been present in the ulnar fingers of both hands and the left thumb.

*Obj. exam.:* Contracting cords to the left thumb, ring and little fingers. The flexion deformity is most marked in the case of the little finger (Grade II).

*On June 13, 1935,* under ether anaesthesia, a cross-shaped incision was made opposite the ring finger and an antero-lateral auxiliary incision in the little finger. After all the contracting tissue had been removed the finger could be fully extended. Immobilization with extended fingers in plaster of Paris for a fortnight. Uneventful recovery.

*After-examination on March 2, 1943* ( $7\frac{3}{4}$  years after the operation): The scar is tender, projecting above the palm like a panel. Extensive recurrence. The tip of the little finger is in contact with the palm.

#### No. 2. — Left hand.

Case Rec. 2255/36. Tram conductor, aged 50. First seen on April 16, 1936. Dupuytren's contracture of 3 years' standing.

*Obj. exam.:* A  $45^\circ$  flexion contracture of the proximal interphalangeal joint of the little finger (Grade I).

*On May 26, 1936:* Operation. All the contracting tissue was removed with great thoroughness and a volar splint applied. The contracture quickly recurred and the scar was hypertrophic and tender.

*On Oct. 7, 1939:* Re-operation under ether anaesthesia. Excision of all the contracting cicatricial tissue. KRAUSE'S skin graft from the abdomen. Uneventful recovery. After-treatment with night-splint.

*After-examination on Febr. 13, 1943* (3 years and 4 months after the latter operation): Left little finger flexed  $90^\circ$  at the proximal interphalangeal joint. The scar is hypertrophic and tender, but the hand may be clenched freely.

(The same patient was submitted to amputation of the right little finger. Result satisfactory after a follow-up of 8 years).

#### No. 3. — Right hand.

Case Rec. 5460/36. Female brewery worker, aged 52. First seen on Aug. 26, 1936. Bilateral Dupuytren's contracture of 2 years' standing.

*Obj. exam.:* A bilateral, symmetrical flexion contracture of  $30^\circ$  at the metacarpophalangeal joint of the little finger and a slight contracture of the ring finger (Grade II).

*On Nov. 5, 1936,* under ether anaesthesia, through an S-formed incision with a bloodless operative field, the affected palmar aponeurosis of the right hand was excised. The surgeon was positive that all the contracting tissue had been removed. Post-operative treatment with iontophoresis and night-splint. 2 months after the operation the finger could be fully extended.

*After-examination on Febr. 3, 1943* ( $6\frac{1}{4}$  years after the operation): The patient is working, but there is a recurrence with a thick contracting cord of fascia and a flexion deformity of  $90^\circ$  at the proximal interphalangeal joint of the ring finger. (The left hand was submitted to the same operation and the same post-operative treatment with an excellent result (6 years after the operation)).

## No. 4. — Right hand.

Case Rec. 806/39. Boiler-smith, aged 46. First seen on Febr. 7, 1939. Dupuytren's contracture of 3 years' standing.

*Obj. exam.:* Flexion deformity of the middle and ring fingers of 30° at the metacarpophalangeal joint (Grade II).

On March 6, 1939, under ether anaesthesia, through a bayonet-shaped incision, operation for Dupuytren's contracture of the right hand. Dressed with sea sponge compression. The healing took a month, after which time there was full mobility.

*After-examination on Jan. 18, 1944* (nearly 5 years after the operation): Recurrence with tenderness of the volar scar and a rather marked contracture of the little finger. (2½ years after the operation the left little finger was amputated on account of Dupuytren's contracture with a good result).

## No. 5. — Left hand.

Case Rec. 2362/39. Painter, aged 52. First seen on May 11, 1939.

*Obj. exam.:* Dupuytren's contracture of the left ring and little fingers (Grade II?).

On June 16, 1939 operation was performed under ether anaesthesia. All the contracting tissue was considered to have been removed, down to the flexor tendons. Dry dressing and sea sponge compression. Uneventful recovery. Shortly after the operation there was a recurrence and the contracture progressed. On Febr. 17, 1943 the proximal interphalangeal joint of the left ring finger was 30° short of a full extension and the little finger was flexed 80°. Pronounced recurrence causing inconvenience during work. The right hand is now involved.

On Febr. 19, 1943 re-operation under local anaesthesia. After removal of all the contracting tissue the proximal interphalangeal joint of the little finger was 30° short of full extension which only could be obtained by articular resection. The patient did not, however, wish such a resection, so the wound was closed and the hand splinted and dressed with sea sponge compression.

*After-examination on July 17, 1944* (1 year and 5 months after the latter operation): 60° flexion deformity at the proximal interphalangeal joint of the little finger. The patient states that the finger is hardly any better than before the operation. 30° flexion deformity at the proximal interphalangeal joint of the ring finger, but the middle finger is satisfactory. The hand may be clenched freely.

## No. 6. — Right hand.

Case Rec. 888/40. Engineer (enthusiastic rower), aged 34. First seen on Febr. 20, 1940. Increasing flexion of the right little finger during the last 5—6 years. Is "unable to use the hand any more".

*Obj. exam.:* 90° flexion deformity at the metacarpophalangeal joint of the little finger and 45° at the proximal interphalangeal joint (Grade I).

On March 29, 1940, under ether anaesthesia, through a Z-shaped incision removal of all the contracting tissue between the skin and tendon. The finger could be almost fully extended. A slight infection



in the wound yielded to treatment with ointment, soap baths, and potassium iodide iontophoresis.

*After-examination on March 13, 1943* (3 years after the operation): Recurrence and a hypertrophic, somewhat tender scar, 45° flexion deformity at the proximal interphalangeal joint. Reduced sense of touch.

No. 7. — Right hand.

Case Rec. 4228/42. Coal carrier, aged 57. First seen on June 2, 1942. Advancing contracture of the right middle, ring, and little fingers of several years' standing.

*Obj. exam.:* 60° flexion deformity at the metacarpophalangeal joints of the little and ring fingers, 45° at the proximal interphalangeal joint and a slight tension when extending the metacarpophalangeal joint of the middle finger (Grade III).

*On July 27, 1942* an operation was performed under ether anaesthesia. The fingers now could be almost fully extended. There was some superficial necrosis of the wound. After-treatment with ointment of cod liver oil, soap baths, iontophoresis and at last Kanavel's glove.

*After-examination on Oct. 26, 1944* (2 years and 3 months after the operation): The patient states that the hand is much worse after the operation. He is unable to clench it properly and the scar is tender. He had been obliged to give up his work as a coal carrier and now earns his living as a labourer. On account of the hand he prefers handling a spade and similar coarse tools.

*The objective examination* did not reveal an actual recurrence, but a tender and hypertrophic scar involving a considerable contracture in the right palm. The contracture keeps the ring and little fingers close together, only permitting a spreading of a few mm. There is a flexion deformity of 25° at the metacarpophalangeal joints of the ring and little fingers and of 10° at the proximal interphalangeal joints. When clenched the ring and little fingers are 4 cm. short of reaching the palm.

No. 8. — Left hand.

Case Rec. 928/43. Fruit merchant, aged 37. First seen on Febr. 2, 1943.

During the last 3—4 years there have been nodular growths and tension of both palms and a flexion deformity of the fingers.

*Obj. exam.:* Contracting bands in the palm in line with the little, ring, and middle fingers. Flexion deformity at the proximal interphalangeal joint of the little finger of 40°, at the metacarpophalangeal joint of the ring finger of a few degrees, at the metacarpophalangeal joint of the middle finger of 30°, and at the proximal interphalangeal joint of the last-mentioned finger of 60° (Grade III).

*On Febr. 3, 1943*, under local anaesthesia, all the tissue contracting the little and middle fingers was removed. Dry dressing. Uneventful recovery.

*After-examination on Oct. 26, 1944* (1 year and 9 months after the operation): For the last 20 years the patient has run a whole-sale business in fruit. He spends much of his time handling boxes filled with fruit without major discomfort.

The objective examination revealed a hypertrophic, firm, and tense, though not tender scar. There is an extensive recurrence at the site of the incision and contractive changes spread over almost the entire palm and the fingers. The nodules are not tender. The mobility is still surprisingly good, there being a flexion deformity of merely  $10^\circ$  at the metacarpophalangeal and proximal interphalangeal joints of the middle finger, and the hand clenching freely. The fingers spread poorly.

No. 9. — Right hand.

The patient is identical with No. 8.

*Obj. exam.:* Contracting bands in the palm and to the index, middle, and ring fingers. Flexion deformity at the metacarpophalangeal joint of the index finger of  $10^\circ$ , at the metacarpophalangeal and proximal interphalangeal joints of the middle finger of  $45^\circ$ , at the metacarpophalangeal joint of the ring finger of  $20^\circ$ , and at the proximal interphalangeal joints of the ring and little fingers of  $45^\circ$  (Grade II).

On Apr. 7, 1943, under local anæsthesia, all the tissue contracting the middle and ring fingers was removed. Immobilization in a volar splint. The healing was delayed, and the patient received a post-operative treatment of iontophoresis with potassium iodide x16.

*After-examination on Oct. 26, 1944* (1 year and 8 months after the operation): No inconvenience when working. Recurrence and massive changes in the palm and on the fingers. The scar is very tender and there is a flexion deformity at the metacarpophalangeal and proximal interphalangeal joints of the middle, ring, and little fingers of  $20^\circ$ .

No. 10. — Left hand.

Case Rec. 1298/37. Warehouse foreman, aged 52. First seen on March 3, 1937. Dupuytren's contracture of the left hand of 10 years' standing.

*Obj. exam.:* A flexion deformity of  $90^\circ$  at the metacarpophalangeal and proximal interphalangeal joints of the ring and little fingers (Grade III). In 1943 the middle finger had become involved.

On July 28, 1943 an operation was performed under ether anæsthesia, leaving, however, a flexion deformity of  $10^\circ$ — $30^\circ$  of the middle, ring, and little fingers. Uneventful recovery.

*After-examination on Oct. 30, 1944* (1 year and 2 months after the operation): The scar looks satisfactory and is not tender. Flexion deformity of  $110^\circ$  of the little finger,  $90^\circ$  of the ring finger,  $70^\circ$  of the middle finger, and  $45^\circ$  of the index finger. When clenched all these fingers are 3 cm. short of reaching the palm.

No. 11. — Left hand.

Case Rec. 279/43. Housewife (epileptic), aged 39. First seen on Jan. 13, 1943. (More than a year prior to this time the *right hand* had been operated upon elsewhere and an exacerbation of the condition had necessitated an amputation of the ring and little fingers shortly after. The index and middle fingers are now becoming involved.)

*Obj. exam.* (left hand): Flexion deformity of  $90^\circ$  at the proximal

<sup>1</sup> Personal communication from the patient's own physician.

and 10° at the distal interphalangeal joint of the little finger, 45° at the proximal interphalangeal and 20° at the metacarpophalangeal joint of the ring finger, 45° at the proximal interphalangeal joint of the middle finger (Grade III).

*On Sept. 9, 1943*, under ether anaesthesia, through a Z-shaped incision, and with a bloodless operative field, all the tissue contracting the middle, ring, and little fingers was removed. The middle and ring fingers may now be fully extended, whereas there still is a contracture at the proximal interphalangeal joint of the little finger. Hand splint. Uneventful recovery.

*After-examination on Oct. 27, 1944* (1 year and 1 month after the operation): The little finger is in acute flexion and there is a flexion deformity of the middle and ring fingers. The patient has not regained the full use of the hand.

No. 12. — Right hand.

Case Rec. 11534/43. Representative (formerly mechanic), aged 42. First seen on Aug. 16, 1943. Increasing contracture of the right little finger of 2 years' standing. The patient has received fibrolysin injections elsewhere, but without effect.

*Obj. exam.:* Contracting bands to the ring and little fingers. A flexion deformity of 60° at the metacarpophalangeal and of 20° at the proximal interphalangeal joint of the little finger. A minor contracture of the ring finger (Grade III).

*On Dec. 22, 1943*, under ether anaesthesia, and with a bloodless operative field, removal of two thick lumps of fascia at the site of the extensions to the ring and little fingers. Sea sponge compression. Uneventful recovery.

*After-examination on Nov. 3, 1944* (11 months after the operation): Working as a representative. Is unable to carry bags or anything else in the right hand on account of tenderness and hypersensitiveness of the little finger.

On the flexor surface of the little finger there is a longitudinal, tender, and tense, rather nodular scar, adhering to the underlying tissue. There is a marked hyperaesthesia, "an electric current racing through" the patient when the finger is touched. There is full mobility of all fingers. The scar in the palm is hardly visible and neither tender nor hypersensitive.

### Summary.

After a brief survey of the etiology, pathogenesis, pathological anatomy, and symptomatology of Dupuytren's contracture the writer reviews the methods of treatment, surgical treatment in particular, and describes the various forms of incision.

111 patients affected with Dupuytren's contracture, 101 men and 10 women, have been treated at the Orthopedic Hospital in Copenhagen during the period 1928—43. The mean age was 51

years. Among these 111 patients 164 hands were affected. 84 were operated upon and 80 not. Excision of the palmar aponeurosis was performed in the case of 68 hands, 62 of which have been followed up for a period ranging from 6 months to 12 years. Only 4 hands have been followed up for less than a year, 40 have been followed up for 2 years or longer, and 27 for 3 years or longer.

The results were excellent in 43 cases or 69 per cent., fair in 7 cases or 11 per cent., and poor in 12 cases or 20 per cent. (Table V).

The writer recommends surgical treatment. Total removal of the aponeurosis is desirable, but technically impracticable. The risk of recurrence perhaps could be reduced by a consistent removal of the aponeurosis in line with the 3 ulnar fingers, this area usually being the site of the lesion.

Finally, the writer discusses the operative indications.

The case histories of the patients exhibiting poor results are appended.

### Zusammenfassung.

Es wird eine kurze Übersicht über die Dupuytren'sche Kontraktur, ihre Ätiologie und Pathogenese, ihre pathologische Anatomie und Symptomatologie gegeben. Darauf werden die Behandlungsmethoden durchgenommen, besonders die operative Behandlung, und die verschiedenen Inzisionsformen beschrieben.

Im Orthopädischen Krankenhaus in Kopenhagen wurden in den Jahren 1928—1943 111 Fälle von D. K. behandelt, 101 Männer und 10 Frauen. Das Durchschnittsalter betrug 51 Jahre. Diese 111 Patienten hatten 164 angegriffene Hände. 84 Hände wurden operiert, 80 nicht operiert. An 68 Händen wurde Fasziensexstirpation vorgenommen, und zwar sind 62 von ihnen nach einer Beobachtungszeit von  $\frac{1}{2}$ —12 Jahren nachuntersucht worden. Nur 4 Hände wurden weniger als 1 Jahr beobachtet, 40 sind 2 Jahre oder mehr beobachtet worden, 27 3 Jahre oder mehr.

Das Ergebnis war ausgezeichnet in 43 Fällen oder 69 %, mittelmässig in 7 Fällen oder 11 % und schlecht in 12 Fällen oder 20 % (Tabelle V).

Es wird betont, dass die Behandlung eine operative sein soll. Vollständige Entfernung der Aponeurose ist wünschenswert, technisch aber nicht durchführbar. Vielleicht würde systematische Abtragung der den 3 ulnaren Fingern entsprechenden Partie der

Aponeurose die Rezidivgefahr vermindern, da das Leiden zumeist in diesem Gebiete sitzt.

Schliesslich wird beschrieben, welche Fälle zu operieren sind.

Es folgen Auszüge der Krankengeschichten der mit schlechtem Ergebnis operierten Patienten.

### Résumé.

L'auteur fait un court exposé de la maladie de Dupuytren, de son étiologie et de sa pathogénie, de son anatomie pathologique et de sa symptomatologie. Il passe ensuite en revue les méthodes thérapeutiques surtout les méthodes opératoires et décrit les divers tracés d'incision.

A l'Hôpital orthopédique de Copenhague, on a traité 111 cas de la dite affection de 1928 à 1945, dont 101 hommes et 10 femmes. Age moyen: 51 ans. Chez ces 111 malades, 164 mains étaient atteintes. 84 ont été opérées et 80 ne l'ont pas été. Dans 68 cas, on a pratiqué l'extirpation de l'aponévrose; 62 ont été contrôlés postérieurement. Temps d'observation variant de 6 mois à 12 ans. 4 mains ont été observées moins d'un an et 40 l'ont été 2 ans ou plus, 27 mains, 3 ans ou plus.

Résultat excellent dans 43 cas ou 69 %; moyen dans 7 cas ou 11 %, mauvais dans 12 cas ou 20 % (Tableau V).

L'auteur souligne que le traitement doit être opératoire. Il faudrait pratiquer si possible la résection de toute l'aponévrose, mais c'est techniquement irréalisable. La résection de l'aponévrose correspondante aux trois doigts cubitiaux diminue le danger de récurrence, car c'est le point d'élection de la maladie.

Enfin l'auteur indique quels sont les cas qu'il faut opérer.

L'exposé se termine par des extraits de journal concernant les malades opérés avec mauvais résultats.

### References.

- BARSKY, A. J.: Plastic Surgery, Philadelphia and London 1938. — BONNEVIE, P.: Beretning om Arbejds- og Fabrikstilsynets Virksomhed 1939—41, Socialt Tidsskrift, Afd. C. 151: 1942. — DAVIS, A. A.: Brit. J. Surg.: Vol. XIX: 539—547 (April) 1932. — DAVIS, J. S.: Arch. Surg. 32: 332: 1936. — DAVIS, J. S.: Plastic Surgery, London 1919. — DESPLAS & MEILLÈRE: Bull. et mém. Soc. nat. de chir.: 58: 424: 1932. — DUPUYTREN: The Lancet, Vol. II: 222 (May) 1834. — FREDET, P.: Bull. et mém. Soc. nat. de chir. 58: 440: 1932. — GILL, A. B.: Arch.

Surg. 32: 332: 1936. — ISELIN, *Traité de Chirurgie orthopédique*, publié sous la Direction de L. Ombrédanne et P. Mathieu, Paris 1937. — KANAVAL, A. B., S. L. KOCH & M. L. MASON: *Surg. Gynec. and Obst.*, Vol. XLVIII, 145—190: 1929. — KLAPP, R.: *Lehrbuch der Chirurgie*, Wullstein und Küttner, Jena 1931. — KLOSSNER, A. R.: *Acta Societatis Medicorum Fennicae*, Series B., Vol. XXXIV, Fasc. 2. 1944. — KOCH, S. L.: *J. Am. Med. Ass.*, Vol. 100: 878: 1933. — KOCH, S. L.: *Arch. Surg.*, 32: 331: 1936. — KROGIUS, A.: *Acta chir. Scand.*, 54: 33: 1922. — LEXER, E.: *Die gesamte Wiederherstellungschirurgie*, Leipzig 1931, Vol. II. — LUND, M.: *Acta Psych. et Neur.*: Vol. XVI: 465—492: 1941. — MEYERDING, H. W.: *Arch. Surg.*: 32: 320—333 (Feb.) 1936. — MEYERDING, H. W.: *Am. J. Surg.*, Vol. XLIX: 94—103: 1940. — MOURE, M. P.: *Bull. et mém. Soc. nat. de chir.*, 58: 444: 1932. — NIEDERLAND, W.: *Archiv für Gewerbepathologie und Gewerbehygiene*, Vol. 3, 1932. — BLAIR, BUNCH, COOPER, KEEN: quoted from KANAVAL. — BUSCH, JANSSEN, ROUTIER, NOBLE SMITH: quoted from ISELIN. — JONES & LOVETT, LOEWY: quoted from MEYERDING.

---