

THE JOURNAL OF BONE & JOINT SURGERY

J B & J S

This is an enhanced PDF from The Journal of Bone and Joint Surgery

The PDF of the article you requested follows this cover page.

Dupuytren's Contracture: A New Concept of the Pathogenesis Correlated with Surgical Management

J. Vernon Luck
J Bone Joint Surg Am. 1959;41:635-664.

This information is current as of March 9, 2009

Reprints and Permissions

Click here to [order reprints or request permission](#) to use material from this article, or locate the article citation on jbjs.org and click on the [Reprints and Permissions] link.

Publisher Information

The Journal of Bone and Joint Surgery
20 Pickering Street, Needham, MA 02492-3157
www.jbjs.org

Dupuytren's Contracture

A NEW CONCEPT OF THE PATHOGENESIS CORRELATED WITH SURGICAL MANAGEMENT *

BY J. VERNON LUCK, M.D., LOS ANGELES, CALIFORNIA

From the Los Angeles Orthopaedic Hospital, Los Angeles

This important entity, known now for more than a century as Dupuytren's contracture, is controversial and incompletely understood except for the diagnosis. There are broad differences of opinion in etiology, pathogenesis, and therapy. A plan of therapy, based upon a new concept of the pathogenesis, to be herein presented, has been associated with superior results achieved with decidedly less stress for both patient and surgeon than was experienced by the routine use of radical aponeurosectomy.

This study of Dupuytren's contracture, palmar and plantar, has been pursued since 1936. During the first half of this period the pathological anatomy and etiology were investigated; during the second half the principal interest has been a correlation of pathogenesis and therapy¹⁷.

Evidence will be presented to support the concept of the pathogenesis herein described, and it will be contended that this concept forms a sound basis for surgical management. In this therapeutic program conservative surgical techniques, including subcutaneous fasciotomy, are emphasized.

CLINICAL PICTURE

The incidence of Dupuytren's contracture is much higher in men than in women. While published statistical reports vary widely, a summary of the literature of reported cases indicates that the ratio is approximately seven men to one woman. While the onset of typical cases may develop any time after the second decade of life, the resulting nodules occasionally lie dormant so that there is little contracture and little disability until a later decade. In this series of 154 cases, the oldest patient was eighty-five years old and the youngest twenty-one, with the average being 56.5 years for men and 61.1 years for women. There were 130 men and twenty-four women, a ratio of 5.4 to one. In thirty-six patients (23.4 per cent) there was a definite hereditary factor, as indicated by the presence of the disease in other members of the same family.

The initial symptom was usually one or more nodules in the ulnar half of the palm, or the volar aspect of the proximal one-half of one or more fingers. A nodule beneath a transverse crease may remain flat and poorly defined or bulge out like twin nodules on each side of the crease. With the passage of time involution occurs, the nodule tends to flatten, and the associated proximal cord becomes rounder and larger. As nodular involution progresses, cords and contractures evolve. The right hand was involved in forty-two patients and the left in eighteen, while in ninety-four patients the disease was bilateral. (Surgery was bilateral in fifty-two.) Pain was seldom a symptom, although occasionally there was slight to moderate pain and tenderness at the sites of nodules. In the rare occasions when pain became a disabling symptom, it took the form of a steady ache or a drawing sensation. Hyperhidrosis of the palms was an occasional finding and was interpreted as a reflection of anxiety. Grasping of hard objects was avoided

*This has been a continuing study. Parts of the paper have been read at the Annual Meeting of the American Society for Surgery of the Hand, New York, N. Y., January 1950, and the Annual Meeting of The American Academy of Orthopaedic Surgeons, Chicago, Illinois, January, 1952.

when the hands were sensitive. There were episodes, in seven patients, of either spasm or occlusion of a coronary artery.

CONTRACTURES

Flexion contractures of the fingers created most of the disability and had their highest incidence in the little and ring fingers. Involvement of the thumb and thenar eminence, while not the rule, was relatively common; contracture of the index finger was the least common. With advancing flexion contractures, the patients who were craftsmen, surgeons, or musicians became increasingly handicapped and many were forced to give up their trade or profession until the contractures were corrected. Involvement of the right hand frequently led to embar-

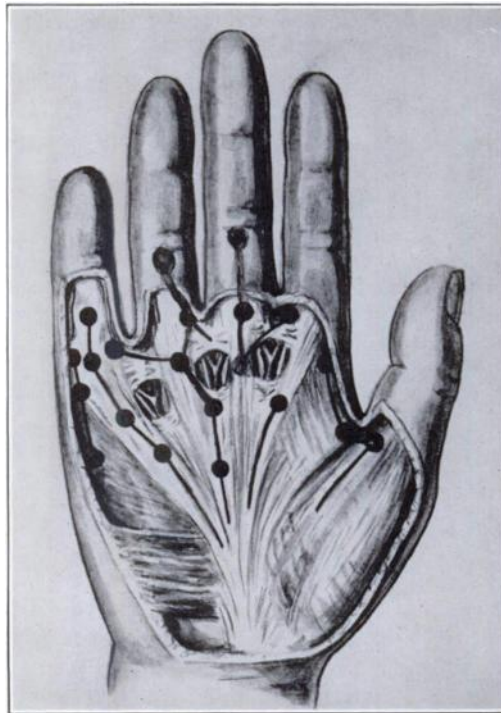

FIG. 1

The principal sites of nodules in palmar Dupuytren's contracture. The connecting black lines represent fascial cords.

rassment in shaking hands; more pronounced involvement led to sticking the finger in the eye when washing the face and difficulty in gloving the hand. As the contractures became yet more advanced, golf and other games were denied the patient. The rate of contracture proved extremely variable. There were instances when a finger became sharply flexed by the contracting nodules within a few months' time; in others the process of involution was so protracted that a period of many years was involved. The actual contracting process generally occurred by irregular steps, interspersed by periods of quiescence. At any time, the active disease process can come to a halt and remain unchanged for long periods of time—even for the remainder of the patient's life.

In this study the contractures are divided into three grades: Grade I contractures are those from 5 to 30 degrees; Grade II contractures are those between 31 and 60 degrees; and Grade III contractures represent contractures from 61 to 90+ degrees. The grade given to a hand is based upon the joint having the greatest degree of flexion contracture. In the classification devised by Meyerding

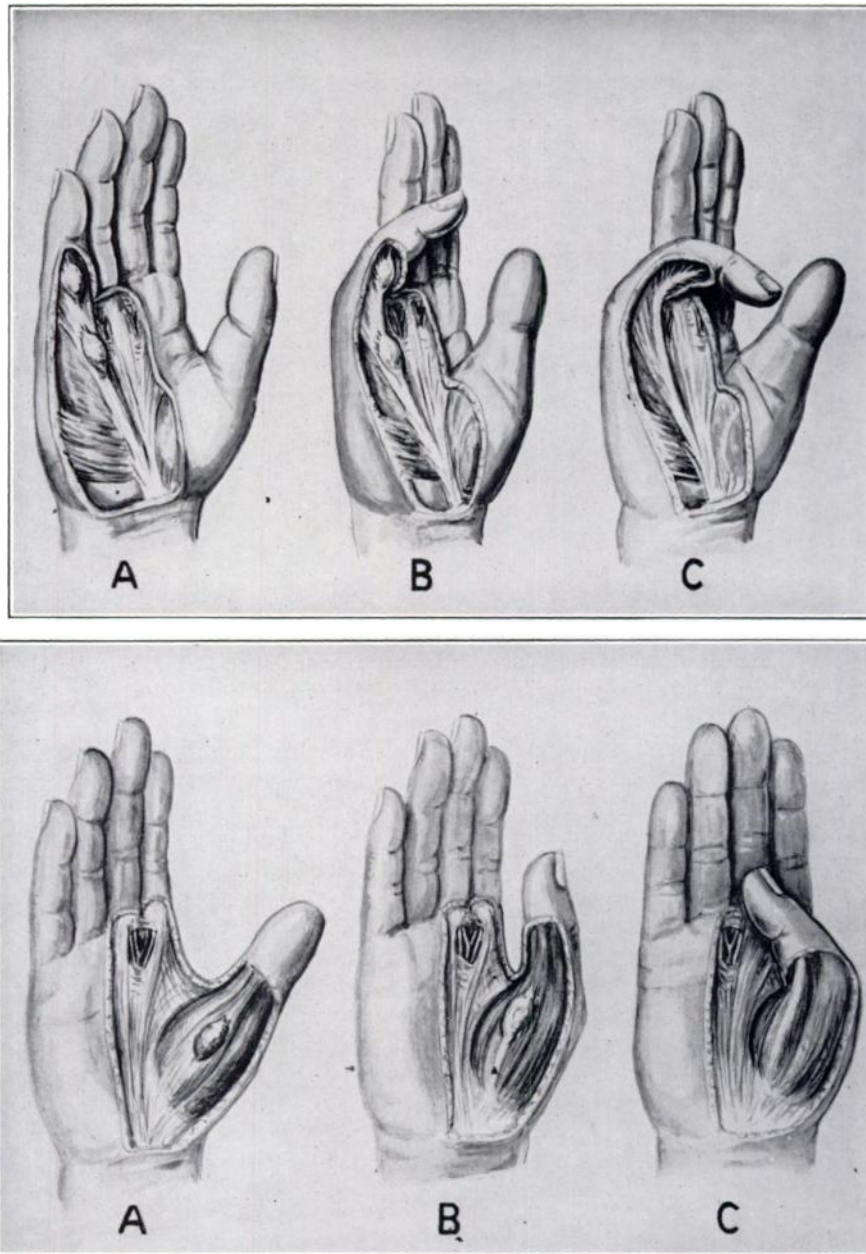


FIG. 2

Pathogenesis of Dupuytren's contracture showing three stages: *A*, the proliferative stage; *B*, the involutonal stage; and *C*, the residual stage.

and associates, account was taken of the number of fingers involved and the degree of general disability. The classification of degree of contracture presented here has simplicity in its favor which is highly desirable when dealing with the more complex patterns of contracture. Of the 154 patients, there were no contractures in twelve (nodules only); first-degree contractures in twenty-two; second-degree, in forty-nine; and third-degree, in seventy-one.

ETIOLOGY

The etiology of Dupuytren's contracture continues to elude us. Investiga-

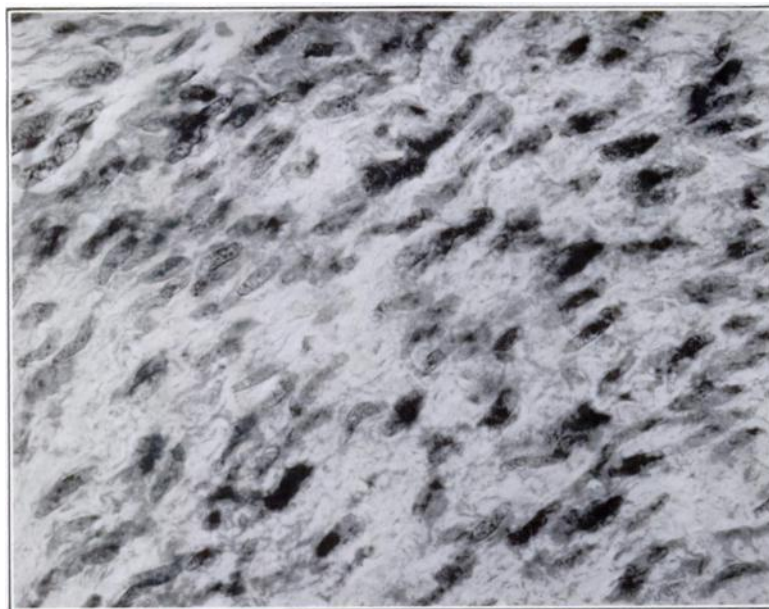


FIG. 3

Photomicrograph showing the cellular character of the proliferative stage. Nodules in this stage must not be misinterpreted as fibrosarcoma.

tions over a period of more than 100 years have failed to identify the true cause of this disease. Trauma appears to head the list of factors that are said to contribute to the disease. Actually, trauma has been variously credited as the sole cause of the disease, as only a contributing factor, or as playing no part whatsoever. Contemporary investigators, for the most part, credit trauma as being capable, at most, of being an aggravating factor, but not capable of causing the disease. Skoog presented the most comprehensive study of this concept. Many patients in the series herein reported gave a history of an accentuation of the flexion contracture following trauma to established nodules in the palm and fingers. While the trauma appeared to cause the contractures to evolve earlier, it probably did not materially influence the degree of contracture that ultimately would have evolved without specific trauma. Of the 154 patients, fifty-three did hard manual work, and 101 did light manual or sedentary work.

The hereditary factor is the most definite and best established of all potential etiological factors. The proportion of the total cases in which the hereditary factor was clearly noted varied in the different reported series from an insignificant percentage to an impressive 40 per cent²². In this series, a hereditary factor was evident in 23.4 per cent of the patients. The number of other alleged etiological agents that were found in association with this disease is legion. It may ultimately be disclosed that many factors, acting singly or in combinations, are capable of setting in motion the sequence of events which lead to Dupuytren's contracture in an individual so predisposed.

Identification of the fascial fibrogenic nodule as the essential lesion of this disease, in addition to the propensity of the nodule for recurring after incomplete removal (in the proliferative and early involutinal stages) would appear to favor the neoplastic theory. Histologically, the nodule has a fibromatous-like appearance during the proliferative stage. It is tempting to consider the disease as a fascial dysplasia. In considering neoplasia as against dysplasia, the dividing line is by no means sharp.

It is my belief that neither chronic inflammation, nor trauma, nor neurological or psychological factors represent primary etiological agents in this disease.

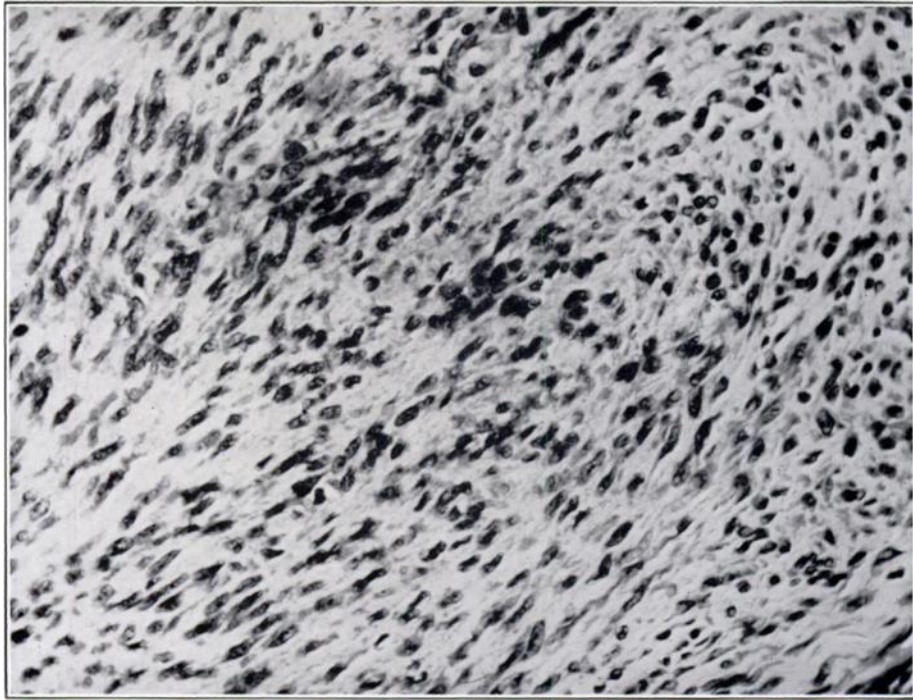


FIG. 4

The cells are beginning to align themselves with the major lines of mechanical stress. This change and the increase in collagen usher in the stage of involution.

PATHOLOGICAL ANATOMY AND PATHOGENESIS

The interpretation of the pathological anatomy of Dupuytren's contracture and the concept of the pathogenesis evolved from the meticulous study of tissues from more than 200 hands and twenty-eight feet involved by Dupuytren's contracture. While the etiology of this entity continues to elude us, much of the pathogenesis is becoming increasingly clear. An understanding of this aspect of the disease is decidedly helpful clinically in both non-operative and surgical management. In nearly all of the cases reported in this study, the operative procedure through which the pathological tissue was made available for study, was carried out by me, thus affording an opportunity to study both the gross and microscopic characteristics of the involved tissues. The initial and essential lesion in Dupuytren's contracture is a focus of proliferating fibroblasts (Fig. 3). While, grossly, a focus may exist as a solitary lesion in the palmar or plantar fascia, multiple foci are the rule. In most instances, the fibroblastic focus creates a palpable nodule. The fibrous cords, so prominent in this entity, form subsequent to the development of the nodule and are intimately related to the involution of the nodule. All the tissues identified with Dupuytren's contracture will be classified as (1) the essential fibrous nodules, (2) reactive tissues, and (3) residual tissues.

For descriptive purposes, the pathogenesis of Dupuytren's contracture will be divided into three stages: the proliferative stage, the involutional (contracting) stage, and the residual stage.

The Proliferative Stage

The nodule, whether it is one millimeter or several centimeters in diameter, is histologically a focus of fibroblasts which, in the proliferative stage, resembles a fibroma. At the onset, when the fibroblasts are young, the cells form a large portion of the tissue and the collagen a minimal portion (Fig. 4). In this focal fibroplasia, the fibroblasts do not align themselves with lines of stress and have,

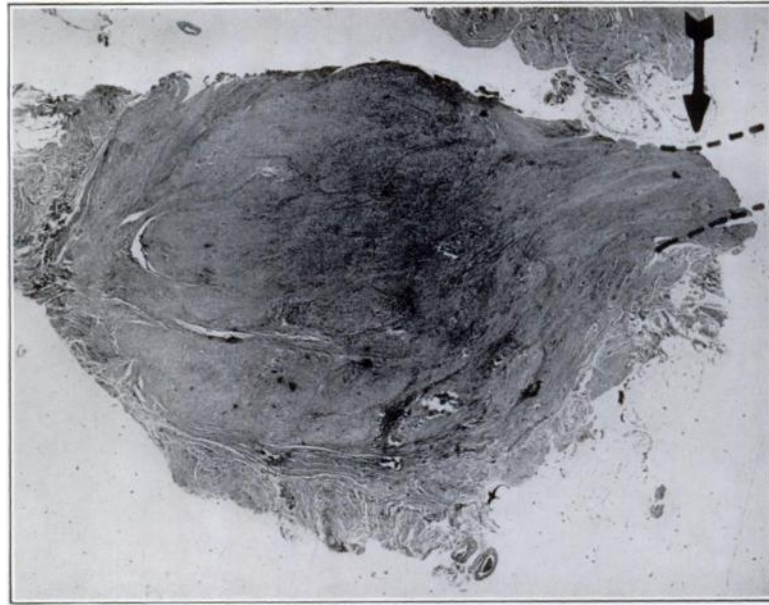


FIG. 5

Photomicrograph ($\times 12$) showing a palmar nodule in the early stage of involution. The arrow and broken lines point to the proximal small fascial cord in which there is early reactive hypertrophy.

in fact, no purposeful arrangement. There may be a solitary or multiple nodules appearing at various locations in the palm and fingers, and in the sole of the foot (Fig. 1). What might well be termed conglomerate nodules are rarely seen. These are made up of multiple nodules which coalesce and form a plaque. Such a plaque, in the hand, generally involves the ulnar half of the distal palm, and, in the foot, the medial aspect of the plantar fascia. A nodule in its early stage is rather resilient and even soft; later it becomes firm or hard.

While the nodules appear to originate in, or superficial to, the palmar fascia, they expand toward the surface, principally between the skin and the fascia. This creates a protruding mass easily identified by the palpating finger. A nodule having its origin either in, or directly adjacent to, the fascia or aponeurosis, attaches securely to this structure. Growth, by expansion, toward the surface generally causes the nodule to replace subcutaneous adipose tissue, and attach to the deep layers of the skin. At a later stage the nodule may replace or displace deep layers of the skin. Thus, with a deep attachment to the palmar aponeurosis and a superficial attachment to the under surface of the skin, the stage is set for the contraction of the involutional process to create a reactive fibrous cord. In the proliferative stage, the nodule is likely to be rather vascular and the considerable reactive tissue at the periphery appears partly related to the blood vessels supplying the nodule. It is not to be assumed that the nodules are limited to the distribution of the palmar and plantar aponeuroses. Actually, nodules frequently appear on the borders of the hand and in the webs, and are relatively common in the thenar eminence. A high incidence of nodules was observed on the volar aspect of the fingers, particularly over the volar aspect of the proximal interphalangeal joints and at the base of the fingers. In only two cases were nodules found distal to the proximal interphalangeal joint, and no typical nodules were seen on the dorsum of the fingers or the hand with the exception of knuckle pads (dorsal nodules) over the proximal interphalangeal joints (Fig. 25). In the foot, the nodules most frequently develop in the medial aspect of the plantar fascia, in its distal one-half. No nodules have ever been identified in relationship to the interphalangeal joints of the toes.

The Involutional Stage

In this stage, the fibroblasts of the nodule align themselves with the major lines of stress that pass through the nodules (Fig. 4). This is predominantly in the longitudinal axis of the hand or foot. As the cells become more mature and smaller they decrease in number, and the proportion of collagen steadily increases. It is during this process that contraction occurs. Actually, this involution, associated as it is with contraction of the nodule, is the process that creates the most prominent aspect of the clinical picture—the flexion contractures of the palm and fingers. As the process of collagenization and contraction evolves, the nodule becomes smaller in diameter and in so doing draws in or puckers the surrounding skin. In addition to its fixation to the overlying skin, the nodule may become anchored to an underlying tendon sheath or joint capsule. In the palm this process creates a skin contracture and at the same time increases tension stresses on the small band of fascia extending from the nodule to the apex of the palmar fascia. If, for example, a nodule is over a metacarpophalangeal joint, the process

A reactive fibrous cord (hypertrophied fascia) extending between two nodules in the involutional stage. (A cord develops proximal to each nodule, frequently creating a chain.)

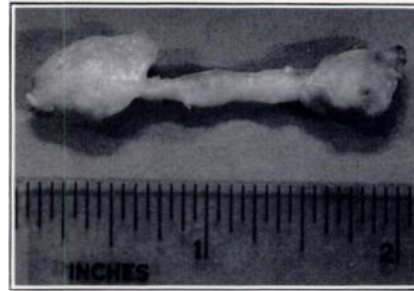


FIG. 6

of the contracture draws the metacarpophalangeal joint into flexion. It does this because the line of least resistance would be flexion of this joint. The innumerable attempts to extend the metacarpophalangeal joint subject the narrow band of fascia extending to the apex of the aponeurosis to intermittent tension stresses. Out of this investigation has come the conclusion that the cord of Dupuytren's contracture forms, for the most part, proximal to the nodule and represents reactive functional hypertrophy in response to the repeated tension stresses on the band of fascia from which the nodule took its origin. The nodule, together with its proximal fascial cord, will be referred to henceforth as a nodule-cord unit, because the more usual picture in Dupuytren's contracture of the hand is that of multiple nodule-cord units united to form chains of nodule-cord units (Fig. 1). Contractures, in this disease, take place only within the nodules and from the involution of these foci of fibroplasia. No contracture appears to occur in the fascial cord—only hypertrophy. Further support of this concept came from the observation that contractures of interphalangeal joints occurred only when nodules developed in relation to these joints. There is absolutely no evidence that involvement of the palm has any influence whatever in causing flexion contractures of the interphalangeal joints of the fingers. The only contractures that involvement of the palmar aponeurosis can create are contractures of the metacarpophalangeal joints. A nodule located in the vicinity of the two transverse creases of the palm creates, during its involutionary process, a reactive fibrous cord proximal to the nodule, extending to the apex of the palmar fascia. If a nodule develops directly over, or nearby, the volar aspect of the proximal interphalangeal joint, the involution of the nodule can draw the interphalangeal joint into a flexion contracture. In doing so, a reactive proximal cord appears and extends from the nodule overlying the proximal interphalangeal joint to the base of the finger. There the fascial cord ends, unless there is a nodule in the palm in line with this cord. If so, the cord from the nodule in the finger joins the nodule-cord unit of



FIG. 7

Photomicrograph showing moderately advanced involution in a nodule. The triangular, central cellular area of this nodule is the last to involute.

the palm, and upon complete involution of the nodules, leaves a residual fascial cord which is continuous from the middle phalanx to the apex of the palmar aponeurosis. Nodule-cord units may occur singly, but a finger tip flexed well into the palm certainly means that there were at least two nodule-cord units. In a few instances there were finger contractures from involuting nodules, but no involvement of the palm. Palmar involvement without finger involvement is relatively common and offers the best opportunity for observing the nodule-cord-unit concept.

If the fibrous cords are reactive (the result of hypertrophy from intermittent mechanical stresses) they should be the largest where they are subjected to the greatest tension stresses; this is precisely what was observed. The fibrous cords grow to large dimensions in those persons who use their hands a great deal. Patients who had unusually large cords frequently were preoccupied with passive stretching of the extensors of the involved fingers; this observation is further evidence that the fascial cords represent functional hypertrophy of a fascial band. At sites where there is little opportunity for either cord formation, or for subject-



FIG. 8-A

A palmar nodule (arrow) nearing the end of the involutinal stage. Note the long contiguous cord.




FIG. 8-B

Photomicrograph of a fascial cord.

ing the small cord that does form to the stresses that would cause substantial hypertrophy, there is little cord formation. Such sites are the lateral and medial aspects of the palm, or the fingers. An example is the nodule that occurs lateral to the first, or medial to the fifth, metacarpal head (Fig. 16).

Whether or not a nodule will be capable of causing disabling contractures of a joint clearly depends on the location of the nodule. In general, the more proximal the location, the less potential that nodule will possess for creating a contracture. Conversely, the more distally located the nodule is, the more contracture it can cause—but here there needs to be a qualifying statement. If a nodule is located directly over a joint, it will have a decided mechanical advantage during its involution. A good example is seen when the nodules develop directly over a metacarpophalangeal joint between the transverse creases of the palm. With every millimeter of contraction such a nodule may create several degrees of flexion contracture in the finger. Actually, several nodules were repeatedly measured during involution and, in some instances, the nodule contracted its full longitudinal diameter. A simple experiment can be carried out on a normal palm by pinching the skin between the transverse creases, drawing the creases closer together. If pinching the skin is carried out directly over a metacarpophalangeal joint, it can create anywhere from 40 to 90 degrees of flexion in that joint if the skin

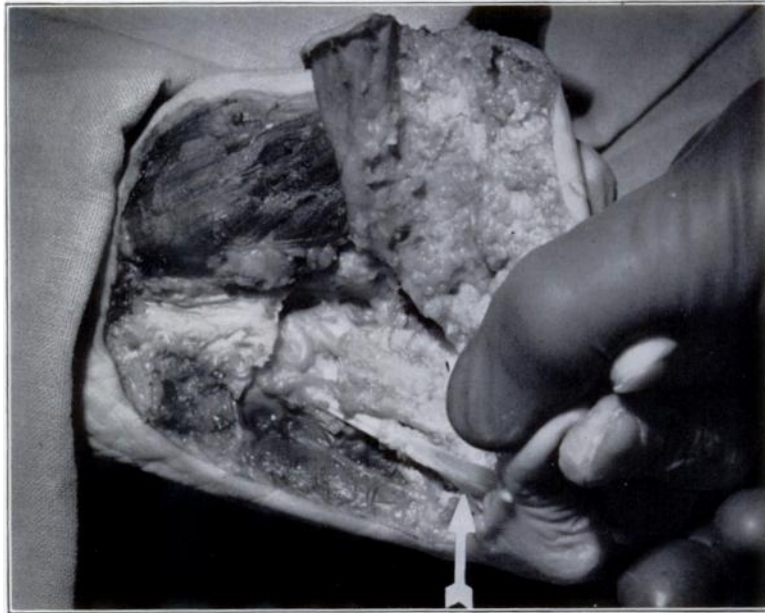


FIG. 9

The hand of a physician, eighty-five years old, at autopsy. The untreated Dupuytren's contracture was of approximately forty years' duration and in the residual stage. Note the tendon-like character of the fascial band (arrow). No trace of the nodules which created the contracture could be found.

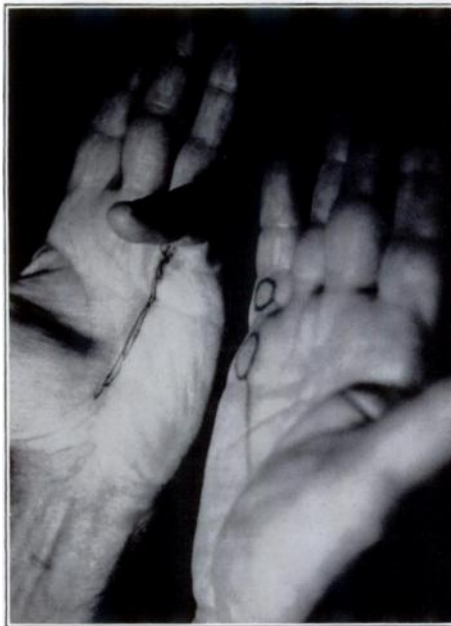

FIG. 10

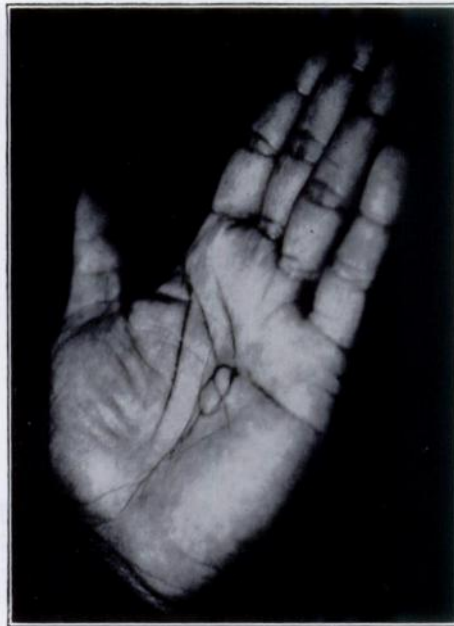

FIG. 11

Fig. 10: The hand on the right shows the proliferative stage. Similar fifth-ray nodules in the hand on the left have completed their involution leaving contractures and residual cord (as marked).

Fig. 11: The hand of a man, thirty-five years old, the only Negro patient in the series. Nodules located this far proximally in the palm cannot cause significant contracture.

is held pinched between the finger tips. By the same token, if a nodule is located directly over the volar aspect of the proximal interphalangeal joint—a frequent location for nodules—that nodule will have, during its contracting phase, tremendous contractural advantage. Here, again, some idea of the manner in which that joint can be contracted to as much as 90 degrees by a very short range of contraction in a nodule can be understood by simply visualizing a nodule steadily decreasing in diameter and drawing all adjacent soft tissue with it. If a nodule occurs at sites where the mechanical situation does not favor the creation of a flexion contracture of either an interphalangeal joint or a metacarpophalangeal joint, then the nodule goes through its life cycle creating relatively little disturbance.

It is not common for nodules to be located in the proximal one-half of the palm, except in the thenar eminence, and when they are so located they cause little difficulty. Nodules in the palm, that lie between metacarpal heads or in the region of the webs, produce cords which take an oblique course and seldom produce contractures (Fig.1). In the same way, nod-

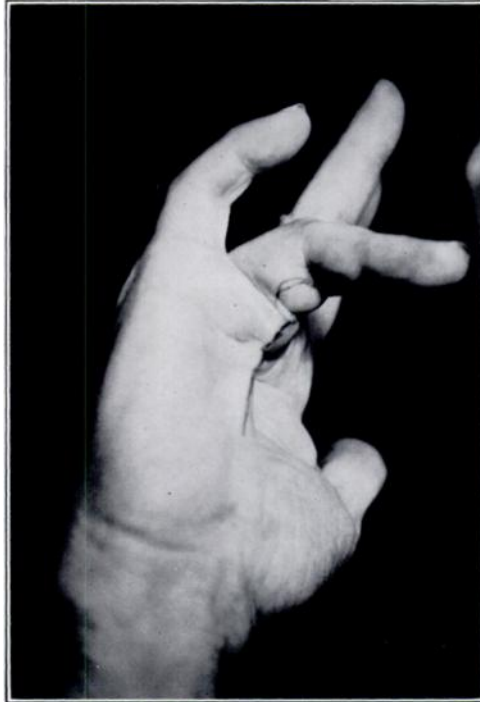

FIG. 12-A

Fig. 12-A: A hand before operation. The large, twin nodules are over the proximal phalanx of the ring finger. Note the heavy cord proximal to the two nodules.

Fig. 12-B: The same hand three weeks postoperatively. Normal mobility was restored. There was no recurrence in a follow-up period of three years.

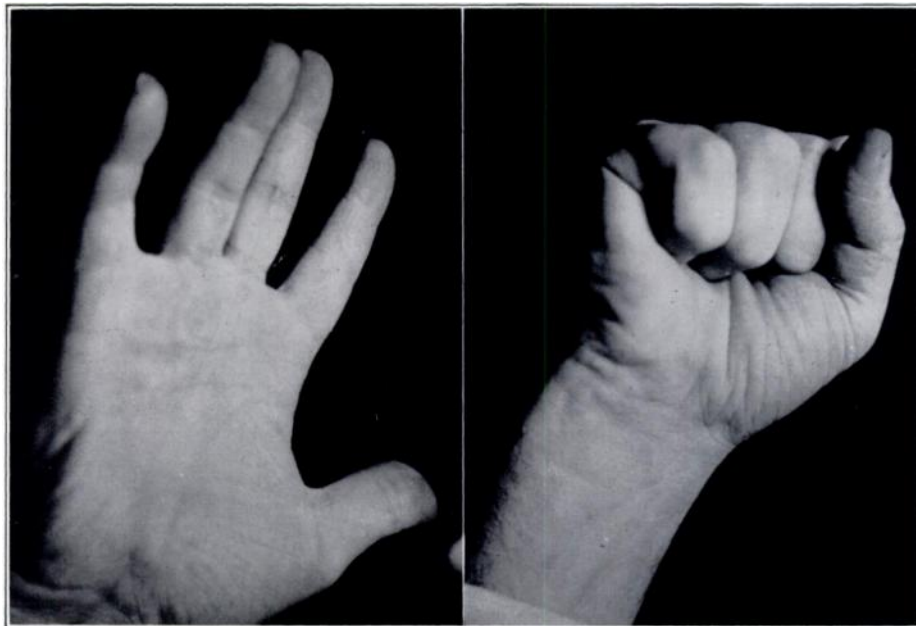


FIG. 12-B

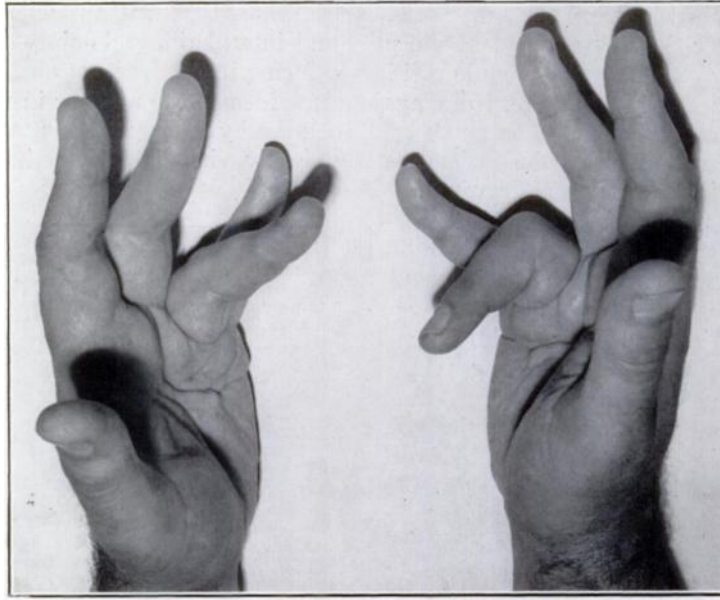


FIG. 13-A

Hands showing the involitional stage. Subcutaneous fasciotomy of the palms and excision of the nodules were performed on both the palms and the involved fingers.

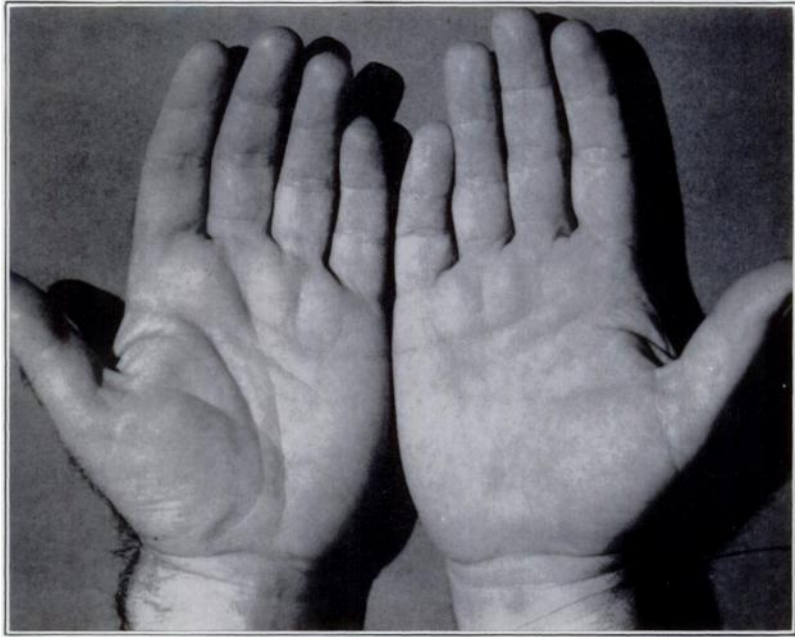

FIG. 13-B

The same hands five years after operation.

ules that are located either on the medial or lateral aspects of the fingers have less capacity to produce flexion contractures, particularly when they lie half-way between the proximal interphalangeal joint and the metacarpophalangeal joint. Contractures at such sites tend to limit or even obliterate spreading of the involved fingers. Many Y-shaped cords are seen and these are the result of eccentrically placed nodules. It is interesting and clinically useful to analyze the pattern of the nodule-cord units that develop in the thenar eminence and the thumb. The most

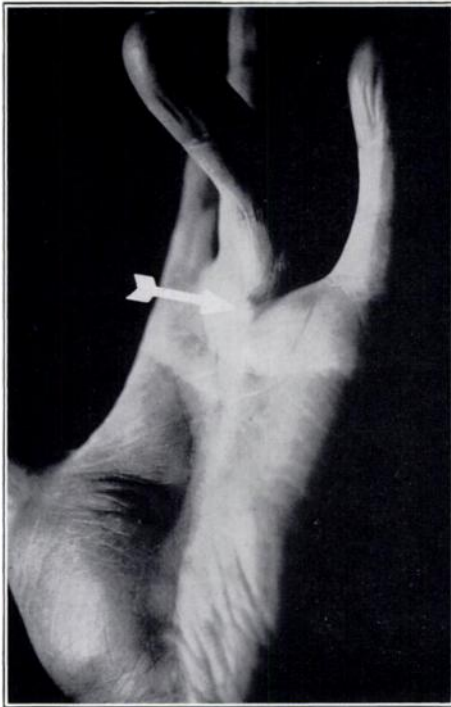


FIG. 14

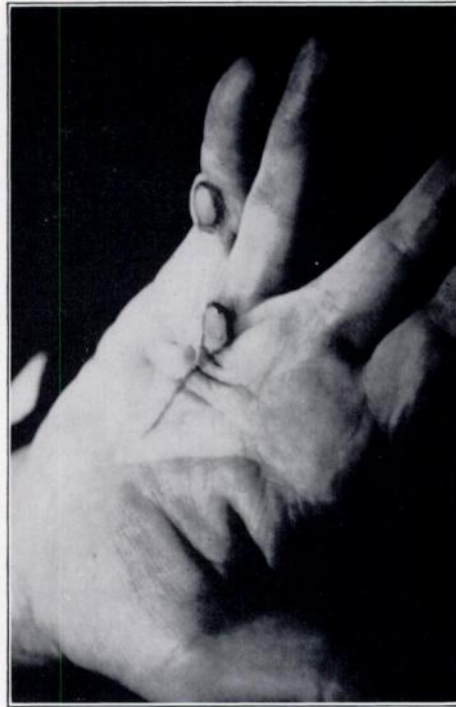


FIG. 15

Fig. 14: Hand showing a solitary nodule-cord unit. The nodule at the arrow point was observed over a period of eight years as it involuted and caused the prominent reactive cord extending to the apex of the palmar fascia.

Fig. 15: The two nodules in the hand represent the total involvement. They were excised. Note the V-shaped skin contracture distal to the palmar nodule.

Fig. 16: Hand showing abduction of the little finger. This deformity is the result of involution in a nodule located over the medial aspect of the fifth metacarpophalangeal joint.

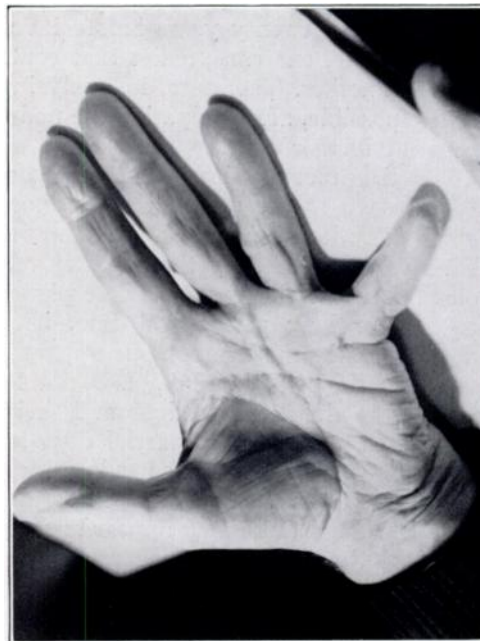

FIG. 16

common site for these nodules is over the first metacarpal head. A nodule that forms over the metacarpal head adjacent to the thumb web will form a cord that extends through the web to the second metacarpal head. Cords from nodules over the anterior, lateral, and medial aspects of the first metacarpal head tend to form a radial arrangement of cords beneath and in the skin of the thenar eminence; there may be two or three separate nodule-cord units.

A cord that forms in the web of the thumb from a nodule over the medial aspect of the first metacarpal head will tend to be well circumscribed and rounded, whereas the cords that form in the remainder of the thenar eminence tend to be flat with less well defined margins. Nodule-cord units of the thenar eminence can draw the thumb toward the palm and can sharply limit abduction, extension, and opposi-

tion. When a volar nodule forms over the interphalangeal joint of the thumb, the proximal cord of this nodule-cord unit generally joins a nodule-cord unit to the thenar eminence. It is thus possible, with the completion of involution, for a cord to extend from the terminal phalanx of the thumb to the base of the thenar eminence.

Nodules overlying metacarpal heads tend to become anchored securely to flexor-tendon sheaths. There is relatively less tendency for the nodules in the proximal one-half of the palm to develop attachments to tissues deep to the fascia (except tendon sheaths). In other words, nodule fixation in the palm is predominantly between the fascia and the skin and not between the fascia and the deep structures. Hypertrophy of normal bands and septa that penetrate deeply is not uncommon, particularly in the fingers. It has also been observed that deeper aspects of the palmar fascia, particularly the transverse fibers over the metacarpal heads, may appear completely normal in the presence of considerable involvement of the overlying longitudinal fibers. A nodule on the lateral aspect of the proximal third of the ring finger will, in its contracting stage, draw this finger toward the long finger and sharply limit spreading of these two fingers. Likewise, a nodule over the medial aspect of the little finger can create an adduction contracture and the patient may lose all ability to draw the little finger to the ring finger. This is as objectionable, to most patients, as a flexion contracture.

The rate with which the nodule involutes and, therefore, the rate of contraction, is widely variable and does not take place on any definite or predictable time schedule. A nodule can appear in the palm, a finger, or the sole of the foot, and remain unchanged over a period of many months or years, and then within a few months undergo involution and create a contracture dictated by the location and size of the nodule (or nodules). While the nodule tends to slowly involute and contract, there may be a period of a few weeks in which there is rather rapid progression of the contracture. In several instances, nodules remained unchanged for more than twenty years before involuting. While the rate of contracture is unpredictable, one can predict that contracture will nearly always occur at one time or another. Therefore, in analyzing a hand involved in this disease, it is readily possible, after palpating the nodules or nodule-cord units, to estimate the potential further contracture.

As the process of involution progresses, the nodule becomes less and less well defined until at the end of the process the nodule is no longer present and, of course, is no longer palpable. It is important not to misinterpret a rather rounded fold of skin, created by the contracture, as a nodule (Figs. 21-A and 21-B). If contractures at the proximal interphalangeal joint are allowed to remain untreated for long periods of time, irreversible changes may occur, including contractures in the ligamentous apparatus, intra-articular changes, and even fibrous ankylosis (Figs. 18-A, 18-B, and 20). The nodule can extend medially and laterally to the flexor tendons and their sheaths and directly involve the joint capsule. Capsulotomy or partial capsulectomy is indicated in some of these instances, but the results of capsule surgery leave something to be desired. In analyzing the involved hand it is important to evaluate the stage each nodule has reached. New nodules may appear in the palm at widely spaced periods. With this wide variation in time of appearance and the wide variation in rate of involution, it is not surprising that the microscopic picture of the nodular tissues reveals, at different sites, wide variations in both cellular maturity and the proportion of collagen to cells. Writers on this subject^{11,20,22} saw no basis in the microscopic picture for reconstructing the pathogenesis of the nodules and cords. Skoog said that it was not possible to establish any relationship between the histological picture and the clinical characteristics of the disease.

In the plantar fascia, the nodules tend to be larger than in the hand, coalescent nodules are more common, and the involutorial process tends to be slower.

The hypertrophy of bands of palmar and plantar fascia, which occurs when they are subjected to pronounced intermittent tension stress, is not unlike the

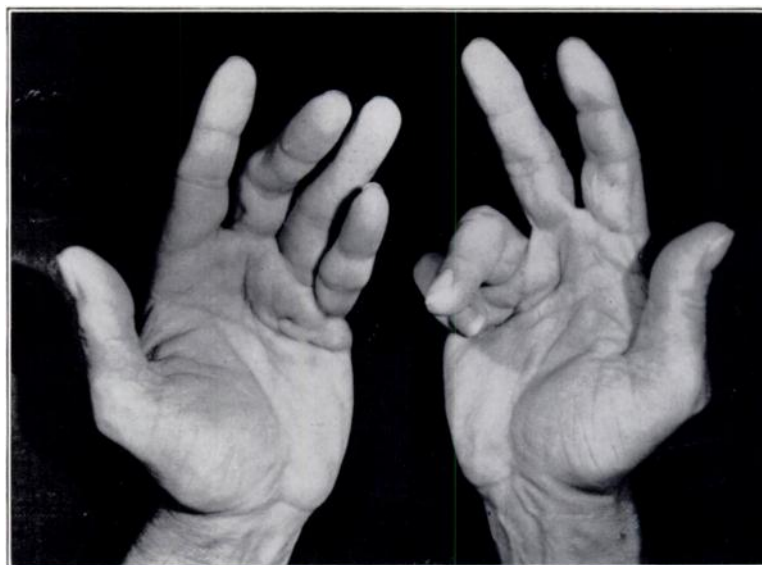


FIG. 17-A

Preoperative appearance of the hands of a general surgeon, sixty-two years old. Subcutaneous fasciotomy was performed in 1948. There was partial recurrence during the first postoperative year. The causative nodules were then removed; there was no further recurrence.

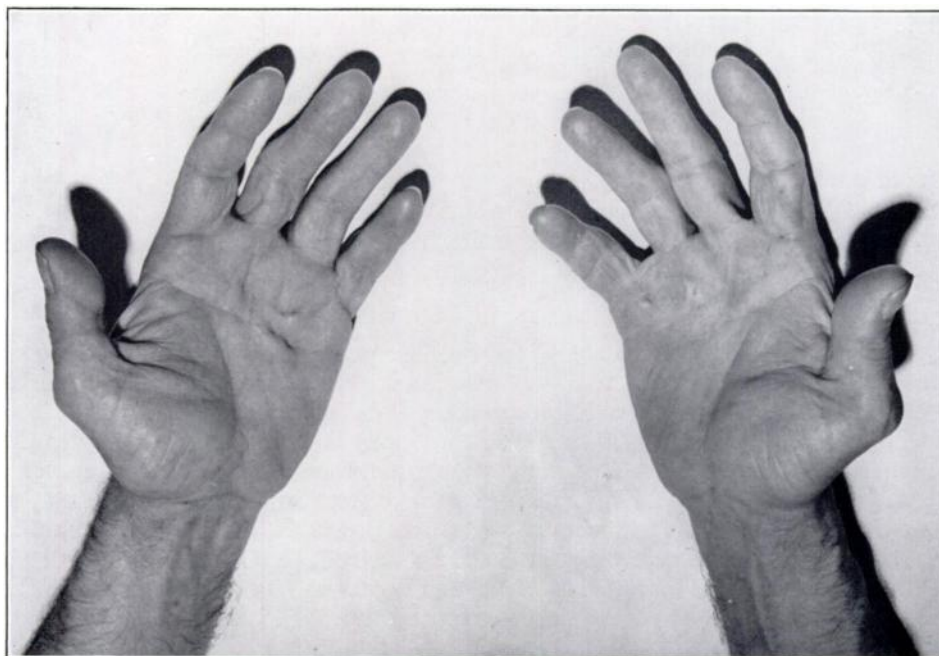


FIG. 17-B

Photograph of hands showing postoperative appearance. The patient resumed operating three days following subcutaneous fasciotomy, and within ten days after excision of the nodules.

dramatic hypertrophy that one sees after transplanting fascia lata grafts to the abdomen extending them from the ribs to the ilium¹⁶ (Lowman's operation). The intermittent tension stresses on these fascial straps are pronounced and the reac-

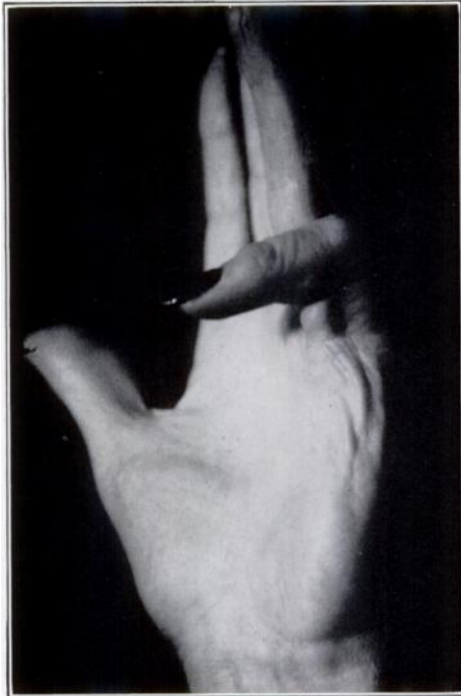

FIG. 18-A

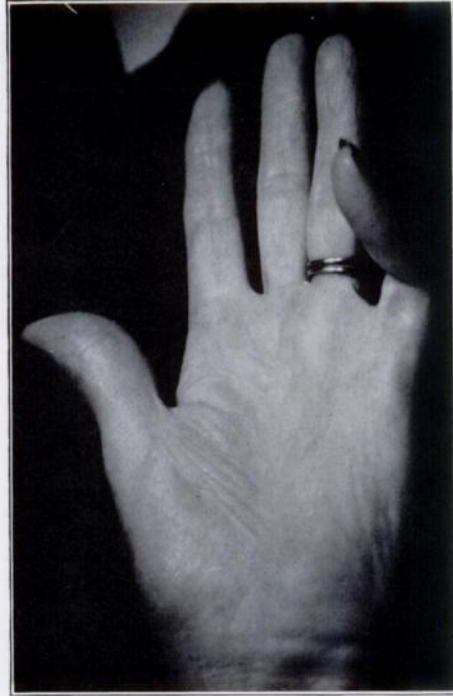

FIG. 18-B

Fig. 18-A: Photograph of hand showing contracture of the proximal interphalangeal joint of the little finger, in the residual stage.

Fig. 18-B: Photograph of hand showing postoperative appearance. The fibrous cord was excised at the site of the contracture, in addition to capsulotomy of the joint. The result was unsatisfactory. The proximal interphalangeal joint of the little finger is the most difficult problem in Dupuytren's contracture.

tion of the fascia is one of strikingly pronounced hypertrophy (Fig. 23). A thin, flat fascial graft, one or two millimeters thick and one-half inch to one-inch wide, can become as large and thick as the patient's tendo achillis, exhibiting a tendon-like structure of great strength.

THE RESIDUAL STAGE

With complete involution the nodule disappears, leaving only a focus of dense adhesions and the reactive proximal fibrous cord which is almost acellular and tendon-like. Where the nodule existed the skin is fixed, drawn into folds, and securely fused to underlying fascia. The cords may be short, existing only in the palm. If there is only a palmar nodule, usually between or adjacent to transverse creases, the skin will be drawn in a V-shaped contour in the palm just distal to the site where the nodule is anchored to the overlying skin (Fig. 15). Proximal to the contracted focus of skin will be the clearly defined fibrous cord which extends to the apex of the palmar aponeurosis. There is seldom any pathological fixation of the skin to the fascial cords in the proximal half of the palm since nodules are infrequent at this site.

In palpating a cord in which the nodules have entirely disappeared, the diameter of the cord will be found to vary but little from one site to another; thus, the margins are parallel. However, when there is fixation of the cord to the skin or skin callosities, palpation of the cord can be rather difficult. With practice, the presence or absence of nodules can be learned by careful palpation. Where no nodules can be identified, and where the contracture has not recently changed, it can be assumed that the process is completely involuted and that no further contracture will occur. After the process has burned out, areas of uninvolved palmar

fascia adjacent to the cords may atrophy and almost disappear. Likewise, if the finger contracts completely into the palm where further extensory stresses cease, the lack of stress on the cord is ultimately reflected by atrophy of the cord. Instances were encountered where the finger was completely flexed into the palm and the cord was reduced to a narrow, thin band. Such an instance was seen in a physician, eighty-five years old, who had had Dupuytren's contracture for approximately forty years and in whom the little and ring fingers of the right hand, completely flexed into the palm, had been useless for approximately twenty years preceding death. At the death of this physician, permission was granted to dissect the hand and it was found that these fibrous cords, no doubt once strong and thick, had atrophied until they were only thin bands resembling the digital tendons of an infant (Fig. 9).

Irreversible joint changes are much more likely to develop in the proximal interphalangeal than in the metacarpophalangeal joints. Joint involvement may be characterized by capsular contractures which

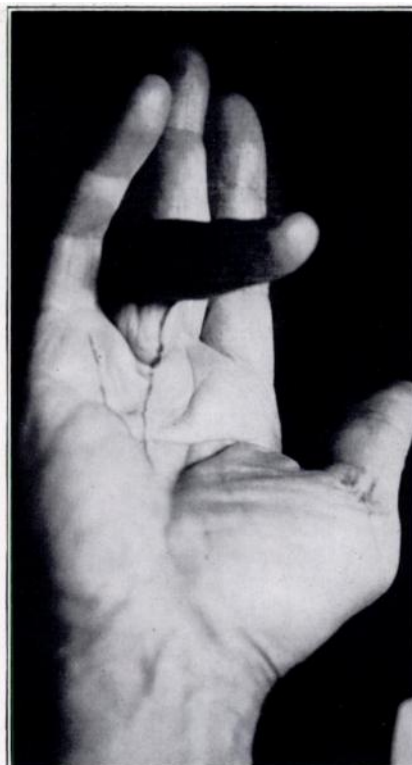

FIG. 19-A
Hand of a man, eighty-one years old, showing the residual stage.

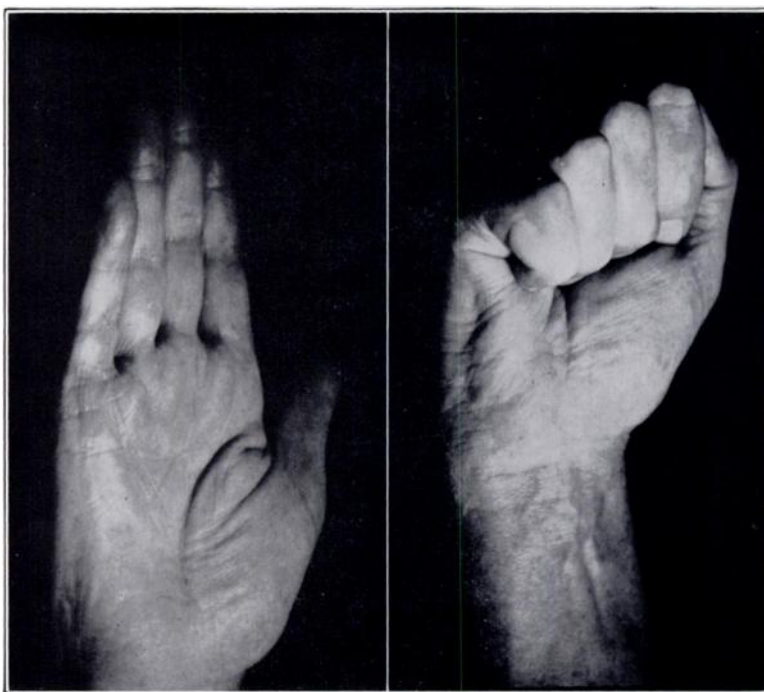

FIG. 19-B
One month following subcutaneous fasciotomy of the palm and partial excision of the digital cord. The patient had already returned to bowling and playing the zither, his principal pleasures in life.

occur through physiological adaptation to a protracted flexion. Atrophy and degeneration of the articular cartilage may occur together with contractures of the overlying skin. These changes are the result of the positional adaptation, involution of the nodules and, in some instances, actual encroachment on the stratum fibrosum of the joint capsule by the nodular fibroplasia. If the joint remains

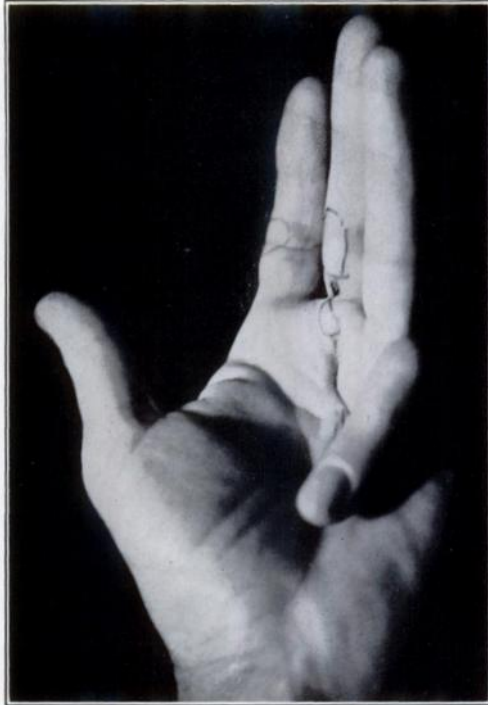

Fig. 20-A

contracted for long periods of time and, in particular, if there has been a nodule in direct relationship to the joint capsule, it may not be possible to correct this contracture completely, even though the procedure would include capsulotomy or partial capsulotomy. Adaptive shortening of the digital nerves, vessels, and tendons occurs and must be taken into consideration in surgically correcting the contractures. The digital nerves and vessels lie alongside the flexor tendons and rarely depart from this position.

Fig. 20-A: The little finger had been contracted completely into the palm for twelve years. Irreversible changes in and around the proximal interphalangeal joint were treated by resection of the distal one-third of the proximal phalanx and fusion of the joint in 30 degrees of flexion. The result obtained is usually preferable to amputation for most patients.

Fig. 20-B: End result after resection of the distal portion of the proximal phalanx of the small finger and fusion of the proximal interphalangeal joint.

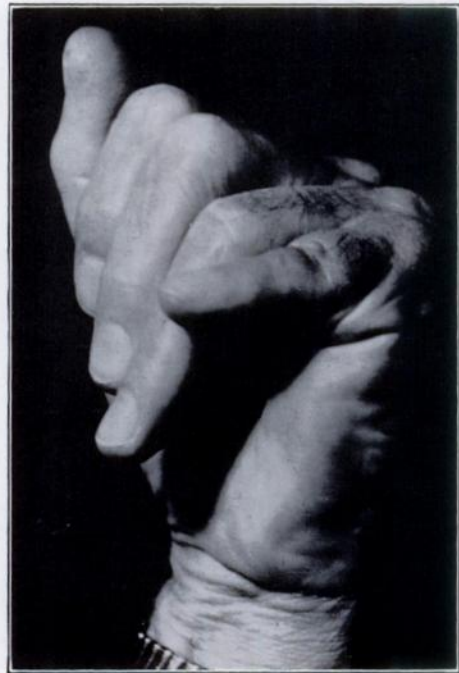
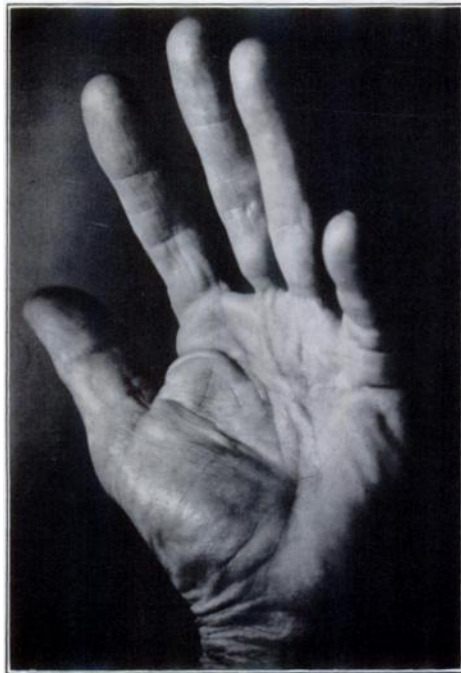
Fig. 20-B

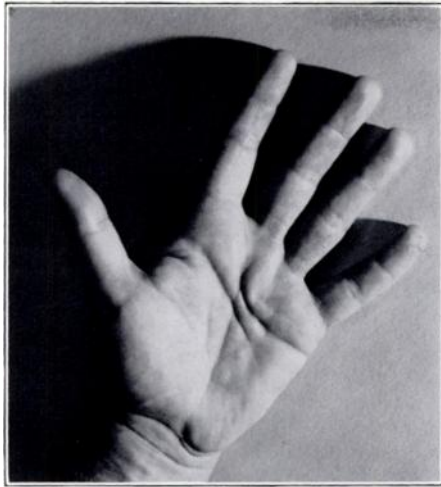

FIG. 21-A

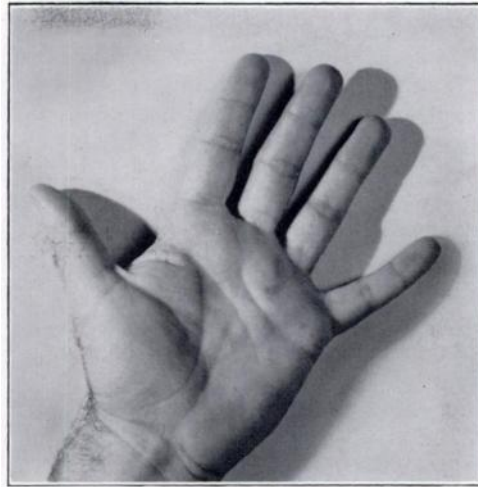

FIG. 21-B

Fig. 21-A: This hand, showing residual palmar involvement from a solitary nodule, was treated by subcutaneous fasciotomy.

Figure 21-B: There was no recurrence during the seven-year follow-up period.

While the hypertrophied fascia may bowstring volarward, the nerves and vessels are rarely carried forward with the fibrous cords. However, it is not uncommon for the nerves and vessels to become intimately entrapped during growth of the nodules. This is much more likely to evolve when a digital nodule arises in an eccentric position to lie medially or laterally rather than directly volarward in the mid-line. In the palm, even with extensive involvement, the nerves and vessels remain in their normal position and are neither enveloped nor encroached upon by the nodular masses.

THERAPY

When the contracture warrants treatment, the definitive treatment is surgical. Notwithstanding this well established fact, numerous non-operative methods have been employed and enthusiastic claims have been made of their efficacy in resolving both the disease process and the flexion contractures. Non-operative therapy includes a variety of splints, ultrasonics and other physical therapy modalities²², roentgen therapy^{8,9}, vitamin E^{14,21,23} and corticosteroids of which cortisone and hydrocortisone are the most frequently suggested. In the natural history of the Dupuytren process as here portrayed, the nodules undergo involution which generally creates contractures. In the past, little attempt has been made to classify the stage of the disease and then employ therapeutic methods based upon the predominant stage of the process. Obviously, if the process has burned out, leaving only the dense, almost avascular, tendon-like cords as a permanent residue, it is not to be expected that vitamins, hormones, roentgen therapy, splints, and various types of physical therapy would have any significant influence. It is hoped that in the future, an attempt will be made to limit non-operative methods to cases in which the disease is still active and the nodules are in either the proliferative or early involutional stage. As a facet of clinical management in this series, hydrocortisone acetate was injected into nodules on numerous occasions. The results to date have been disappointing, with the exception of several early-stage nodules which were rather soft and were actively growing. A definite statement on the value of this method cannot be included in this report. The ideal form of therapy would be a method that could be employed with the first appearance of the nodules that would cause a prompt resolution of the nodules without the nodule undergoing contracture. The use of hydrocortisone acetate, injected into the nodule, roentgen therapy, or ultrasonic therapy is limited to carefully selected early cases.

SURGICAL THERAPY

Since surgery has offered us the only reliable method in the management of this condition, intensive investigation has been directed toward surgical techniques. I have developed a method of surgical management of Dupuytren's contracture which is based upon my concept of the pathogenesis of this disease. If it be true that the nodule is the essential lesion, and my studies indicate that it is, it is not necessary to do a radical excision of all of the palmar fascia and associated fibrous cords. To eradicate the aggressive factor, it is necessary only to completely excise the nodules. If the process is in a stage of nodule-cord units (involutional stage), operative procedures which do not include excision of the nodules,

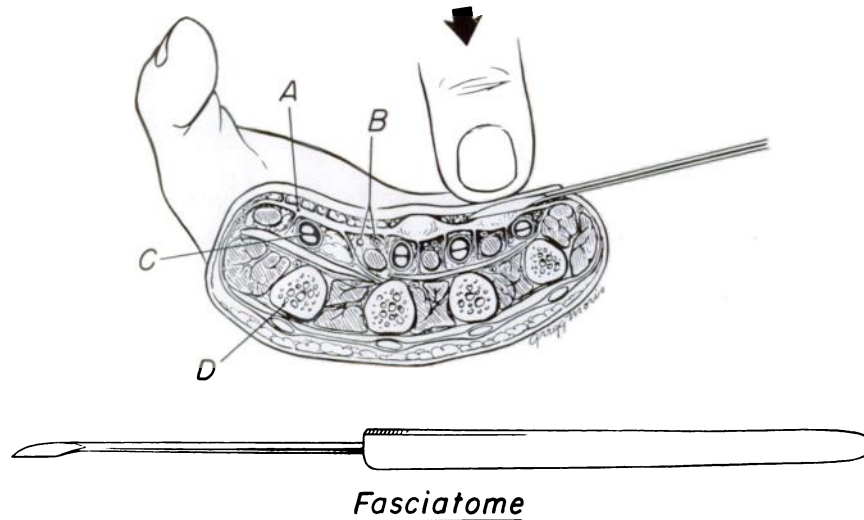


FIG. 22

Schematic drawing: the triangular handle of the fasciatome helps to indicate the location of the sharp edge of the blade when it is under the skin.

The cross-section drawing shows: *A*, the palmar aponeurosis; *B*, the neurovascular bundle; *C*, the flexor tendons; and *D*, the second metacarpal.

for example, subcutaneous fasciotomy, will generally be followed by at least a partial recurrence of the contracture. On the other hand, if the nodules are completely excised, and the fibrous cords are sectioned subcutaneously or by direct vision, recurrence will not take place unless there is some subsequent development of new nodules. In the involutional stage, excision of the nodule is the most essential step in the operative procedure. If the technique of subcutaneous fasciotomy is not familiar to the surgeon, the proximal cords frequently can be left undisturbed although the skin should be undermined at the sites of skin fixation or contracture. Undermining the skin can be accomplished by the same skin incision used to excise the nodule, by undermining proximally or distally with a small blade. When palmar nodules have completed their involution, leaving only residual fibrous cords and contractures, it is necessary only to section these fibrous cords subcutaneously at multiple levels and undermine the skin wherever it is pathologically adherent. In this residual stage, subcutaneous fasciotomy well deserves a prominent place in therapy.

Under no circumstance should subcutaneous fasciotomy be considered lightly or casually and interpreted as an easy procedure. It is a safe and effective procedure where proper attention has been given to mastering the important details of the technique. As much precision and skill are required as with the open operation. To me, radical excision of the palmar aponeurosis has appeared to be unnecessary.

Indications for Subcutaneous Fasciotomy

1. Subcutaneous fasciotomy should be restricted to the palm, proximal to the webs of the fingers and distal to the apex of the palmar fascia (junction of the thenar and hypothenar eminences).

2. Subcutaneous fasciotomy is applicable in all cases of palmar involvement where the nodules have either partially or totally involuted. Actually, this represents the majority of the surgical cases. In the involutational and residual stages of palmar nodules, there are fascial cords proximal to the nodules. These cords can be well resolved by subcutaneous fasciotomy.

Contra-Indications for Subcutaneous Fasciotomy

1. Subcutaneous fasciotomy should not be employed in fingers or thumb (or in the webs of the fingers).

2. Subcutaneous fasciotomy is unnecessary when the nodules of the palm are

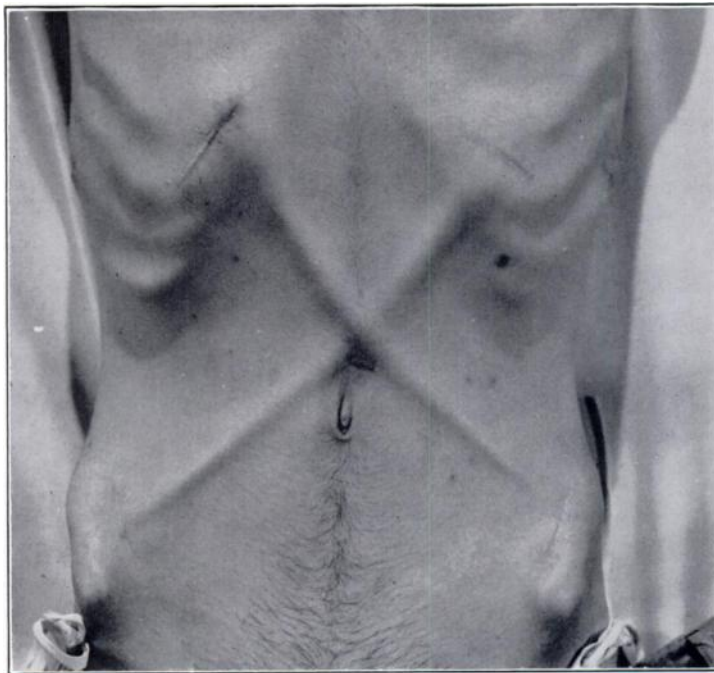


FIG. 23

Criss-cross fascial straps (patient's own fascia lata) have been extended from the rib margins above to the iliac crest below (Lowman operation) for flaccid paralysis of the abdominal wall. Intermittent tension stresses on these thin straps lead them to hypertrophy into thick fibrous cords. This same mechanism, in my opinion, is the cause of the cords in Dupuytren's contracture. (Illustration courtesy of Dr. C. L. Lowman.)

in the proliferative stage. (In this stage the hypertrophied fascial bands have not yet made their appearance.)

3. Subcutaneous sectioning in the palm should not be carried out if there is any question about the diagnosis. The prominent flexor tendons of rheumatoid arthritis and senility must not be mistaken for fascial cords.

Palmar Involvement versus Digital Involvement

In the vast literature on Dupuytren's contracture, the palm has been the center of discussion. In reality it is not the palmar lesions that create the greatest contracture and disability; rather, it is the nodules in relation to the proximal interphalangeal joints. No amount of palmar dissection, no matter how radical, will

resolve contractures of the proximal interphalangeal joints. This site of involvement must be approached directly, since it is not possible for palmar lesions, that is, palmar nodules, to create contractures of the interphalangeal joints. These joints are contracted by the involution of nodules that form directly over, or in close approximation to, them. Therefore, involvement of the proximal interphalangeal joint must be dealt with by surgery directly at the site of an existing causative nodule or its contracted residue. Prior to operative therapy, the hand must be meticulously studied; every nodule and every cord must be clearly delineated in the surgeon's mind as he plans the surgical correction. Identifying the stage of the disease leads to an estimate of the status of the contracture. The

plan of therapy is not complex if this information is utilized; results from pursuing this method of analysis and management have been gratifying.

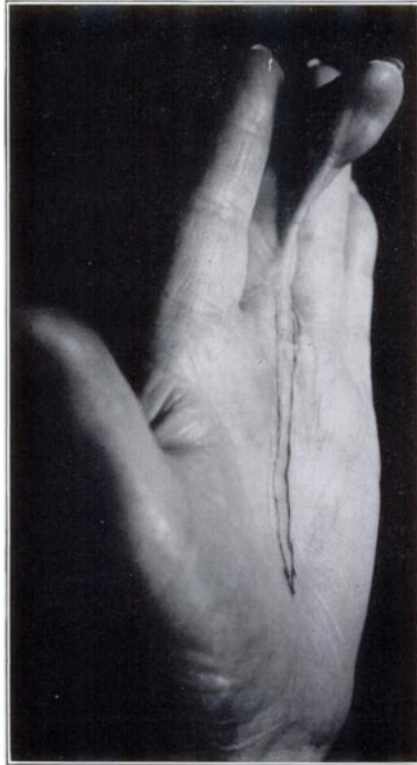

FIG. 24

This burn scar on the long finger was of many years' duration. A cord of hypertrophied palmar fascia extended from the base of the finger to the apex of the palmar fascia. Extensory tugging on the band of fascia caused the hypertrophy, just as it does in Dupuytren's contracture.

Subcutaneous Fasciotomy

Sir Astley Cooper was the first to use subcutaneous fasciotomy in what must have been a Dupuytren contracture. Prior to the time of Cooper and Dupuytren, the treatment of Dupuytren's contracture consisted in division of the flexor tendons; the results must have been discouraging. Dupuytren, in 1832, recommended the use of multiple, transverse incisions through the skin and the underlying fibrous cords. The small skin incisions were left open. A variety of limited operative procedures were recommended in the decades that followed. Adams, in 1878, did much to popularize the method of

subcutaneous fasciotomy. Good results were claimed by Adams and it was his belief that there never would be more than a partial recurrence. He stated that all operations by open wound should be condemned as unnecessarily severe. Macready, a student of Adams, continued the use of subcutaneous fasciotomy and, in 1890, stated: "The subcutaneous treatment of Dupuytren's contracture of the palmar fascia is so successful with those who use the necessary observances, that it is hard to understand why the treatment by open wound still holds its ground." Keen, at the turn of the century, did much to popularize radical excision of the palmar aponeurosis as a routine method irrespective of the extent of the pathological process. Since the turn of the century, aponeurosectomy has steadily increased in popularity and has become almost universally adopted as the method of choice^{2,4,5,12,15,19,20,22}. For the most part it is carried out without regard for the extent of the disease or the stage of the process. Hamlin, in limiting the excision to involved areas observed, in fourteen patients, a sharp decrease in the time between operation and return to work. He emphasized the necessity of removing all diseased fascia and stated that the cords and the fasciculi to the deep fascia must be searched for and excised. In thirty cases of radical excision that were reviewed, the average time between

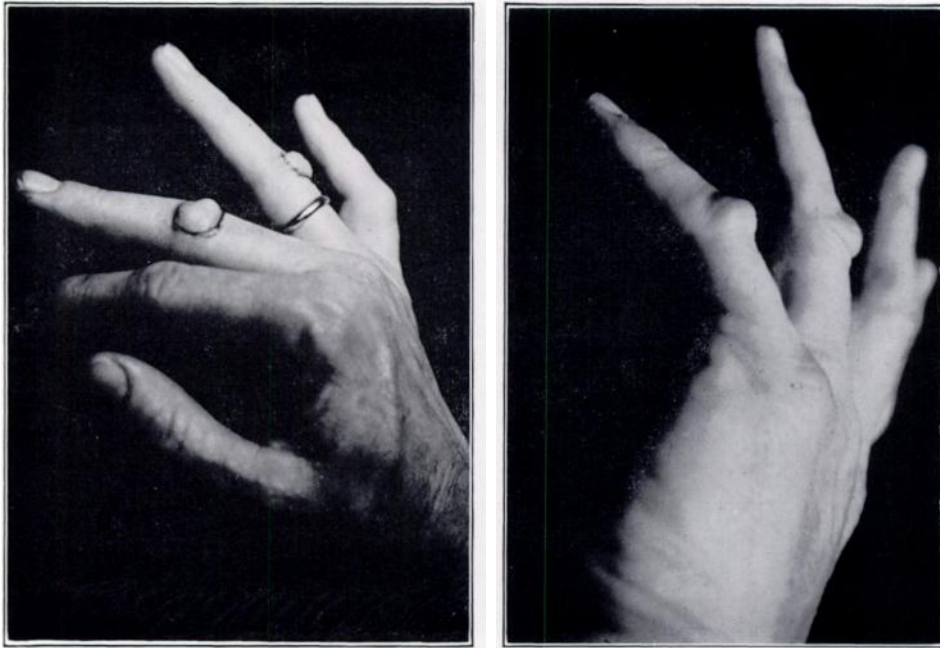


FIG. 25

Typical knuckle-pads. These dorsal nodules overlie the extensory apparatus of the proximal interphalangeal joint. Contractures of these nodules have not been observed.

operation and return to work was 118 days. In the fourteen cases of limited excision, the average was twenty-one days, notwithstanding longitudinal palmar incisions and dissection of the cords to the apex of the palmar fascia.

Less radical therapy, particularly treatment by subcutaneous fasciotomy, has been mentioned only rarely since the turn of the century, and usually mentioned only to condemn it. In his comprehensive monograph, Skoog summed up the literature on subcutaneous fasciotomy and ended his summary by condemning the method. Bunnell used subcutaneous fasciotomy in severe cases preliminary to radical excision of the aponeurosis. He stated that the radical operation should be performed within three weeks after the subcutaneous release to prevent loss of the correction achieved by the subcutaneous fasciotomy.

On the basis of my studies, it is evident that subcutaneous fasciotomy used alone and routinely without regard for the stage of the disease will be followed by a high incidence of recurrence of the disease. If the surgeon is working principally with elderly patients, as appears to have been the case with Adams and Macready, the incidence of recurrence would be low because a high percentage of these patients would have a long-standing and completely involuted process; conversely, those working with younger patients would have discouraging experience with routine use of subcutaneous fasciotomy. In the series of fifty cases reported by Skoog, all but five patients were under the age of fifty, and thirty-six of these patients were under forty.

Two erroneous concepts are widely encountered:

1. With the appearance of a nodule in the palm, it is a foregone conclusion that there will be more nodules at a later date and that the patient, without radical therapy, is destined to a gradual progression of the disease, ending inexorably with the fingers contracted into the palm. In the experience with the large series of cases herein reported, this error has become clearly defined. A patient with active involvement stands a better than even chance of never having an extension of the process to other areas.

2. It is widely believed that if the radical operation is carried out, the patient can be assured that there will be no further recurrence or extension of the

process. This is viewed as erroneous on the basis of several well documented cases where new nodules have appeared in hands after meticulous and complete excision of the palmar aponeurosis. It is my recommendation that only that portion of the palm and the fingers actually showing nodules should be the site of open surgery. In this study the evidence indicates that radical dissection of uninvolved areas of the palm or fingers has little to support it.

TECHNIQUE OF SUBCUTANEOUS FASCIOTOMY

Subcutaneous fasciotomy consists in severing palmar fascia subcutaneously at multiple levels. This technique is limited to the sectioning of well defined, fibrous cords. The procedure is carried out with a small knife, which will be referred to as a fasciatome. The writer's fasciatome has a triangular-shaped handle so that the location of the cutting edge of the small blade, when it is beneath the skin, will always be known to the surgeon (Fig. 22). The fibrous cords are sectioned transversely, the first level being just distal to the apex of the palmar fascia as it lies between the thenar and hypothenar eminences. The next level is at the site of the proximal transverse palmar crease, and the third, and final, level in the palm is at the level of the distal transverse crease. Through a one-eighth of an inch puncture wound, made by a pointed scalpel in the skin lines along the medial border of the palm, the fasciatome is inserted with the blade in a transverse position just beneath the skin. The blade is passed into the subcutaneous tissue directly beneath the skin until it reaches the site of the cord or fascia to be divided. The blade is turned until the sharp edge lies against the superficial surface of the cord to be divided (Fig. 22). With the surgeon's finger tip placed on the skin that overlies the back of the blade, the blade then is pressed by the surgeon's finger tip through the fibrous cord. These cords offer considerable resistance and it is almost a gritty sensation that the blade transmits to the surgeon's fingers as the blade passes through the fascial cord. Solid resistance to further progress of the blade ceases when the cord has been divided, and it is then as though the blade were pressing against sponge rubber. The blade is now advanced between the skin and the cord and another one-sixteenth or one-eighth of an inch of the cord is divided. Each time the blade is advanced between the skin and the involved area of the fascia, the blade is turned 90 degrees so that it is flat. The blade is turned again so that the cutting edge can be pressed through the cord or fascia. Under no circumstances should a reciprocal stroke be employed since this would obviously endanger the underlying nerves, vessels, and tendons. If no sawing or reciprocal action is employed, the vessels, nerves, and tendons are not in danger. Where there are adhesions between the skin, nodules, and fibrous cords (and this is regularly encountered) the overlying skin is dissected off the involved focus of fascia by turning the blade to a right angle and undermining the skin. Care must be taken, in this part of the procedure, that the blade does not repeatedly penetrate the skin; however, no harm is done if the point of the blade should once or twice protrude through the skin. Frequently, during the undermining, the skin is so thin that the outline of the blade can be seen. Where there is a deep crease at sites of considerable flexion contracture, the bottom of the crease, or dimple, may be difficult to see; it is best in this situation to divide the cord before undermining the skin. If an attempt is made to undermine the skin first, it is difficult to prevent severing the apex of the deep dimple, or crease. Once the cord is divided the apex of the dimple can be seen, as can the apex of a deep crease. Pathological fixation of the skin is a prominent part of this disease and a major source of the contractures. The skin can be undermined as extensively as desired without fear of necrosis. There were no instances of skin necrosis regardless of the extent of the undermining and the thinness of the skin where no incision was made in the palm.

Under no circumstances should the blade be plunged into the palm and the cutting edge turned toward the surface so that the cord and fascia are divided in

a cut carried toward the skin. This would grievously endanger the deep structures. The blade should not be passed into the webs of the fingers since the nerves and vessels become fairly superficial at this point. It is reasonably safe to use the subcutaneous technique in the fingers proper if the fibrous cord is tented up and not displaced from the mid-line. In numerous instances the nodule responsible for the cord develops toward the lateral or medial aspects of the finger. Because of the danger to digital nerves and vessels, a longitudinal incision should be made over the mid-lateral or mid-medial aspects of the finger at the site of the cord. The nerves and vessels should be visualized by meticulous dissection, retracted, and then the cord should be divided. A segment of the cord should generally be removed and, when present, the nodule or nodules. When large nodules are present, both a mid-lateral and a mid-medial approach may be necessary. The nerves and vessels should be exposed proximal or distal to any nodule encountered and followed along the nodule.

Involuting Palmar Nodules

After subcutaneously sectioning palmar cords, a short transverse incision is made in either the distal or the proximal transverse palmar crease and the nodule, or nodules, removed. The skin incision is not usually long—seldom more than one and one-fourth inches—and through this approach the nodules are carefully visualized and excised along with the adjacent portions of their respective cords. The dissection is carried out proximodistally, the proximal fibrous cords having been previously divided by subcutaneous fasciotomy. The ends of the cords that were divided subcutaneously are found not far from the nodules and are readily brought into the operative field. The tendons, nerves, and vessels should then be identified. Where the nodule is securely anchored to the underlying tendon sheath, the sheath at this site should be excised along with the nodule. A thenar-eminence nodule over the first metacarpal head is usually best visualized by a transverse skin incision in the transverse crease overlying the first metacarpal head. The fibrous cords that extend from this nodule into the thenar eminence can be divided subcutaneously. It has been claimed that subcutaneous fasciotomy could not possibly succeed because there are no means whereby the deep ramifications of the fascia can be divided. This is an erroneous concept. In the cases of this report, complete correction of palmar contractures nearly always occurred when the cords were divided and the skin undermined at sites of adhesions. This experience indicates that the deep ramifications of the fascia are not nearly so important in the cause of the contractures as has been supposed.

Skin Closure and Postoperative Care

Skin incisions are accurately but loosely closed by interrupted everting sutures and the procedure is completed by the application of a compression dressing generally consisting of fluffed-gauze sponges and a two-inch elastic bandage. If the skin of the palm is contracted, and if extending the fingers would place a strain on the skin incision, the fingers are held flexed by adhesive-tape loops in the amount of flexion that brings relaxation of the skin incision; this is maintained until the skin is healed. After the wound is healed, vigorous exercises are begun and, in most cases, the skin can be relied upon to stretch to the length required. It is remarkable how well the skin is able to return to a more normal character. In my opinion, there is no evidence that areas of involved skin should be excised and replaced by skin grafts; this procedure was never performed on any patient in the series herein reported. When subcutaneous fasciotomy has been used alone, the patient was able to begin actively using his hands within two to seven days. In several instances, the patient was able to return to manual work within one week. In most instances, no splints of any type were employed. In a few of the more resistant contractures, a night splint was used. In three patients, a stellate block was employed for postoperative pain and tenderness and evidence

of sympathetic-nervous-system disturbance (reflex sympathetic dystrophy). Hydrocortisone acetate was injected when the postoperative swelling and pain were beyond average. Both the stellate blocks and the injections of hydrocortisone proved helpful enough to justify their use.

Postoperatively, in palpating areas of palmar subcutaneous fasciotomy, the fibrous cords that previously were so conspicuous were no longer palpable. These sectioned cords presumably atrophy and disappear once the stresses, which the writer believes created and perpetuated them, have no further influence. When the related nodules were properly removed and the cords completely divided, the cords gradually disappeared and were not a source of recurrence. In the residual stage, where only the subcutaneous technique is employed, recurrence generally means that the cords were not completely divided.

In instances where there is an extreme contracture (90+ degrees) in the proximal interphalangeal joint, in which the contracted soft tissues (tendons, ligaments, nerves, and vessels) will not allow the finger to extend, the distal one-third of the proximal phalanx can be excised and the joint fused in 30 degrees of flexion. (A small Kirschner wire is used longitudinally for fixation.) This will give a shortened finger but most patients will prefer it to either amputation or extreme contracture. This technique has been used on the little finger in two instances with good results.

ANAESTHESIA

The anaesthesia most frequently employed in this series was local infiltration of either 1 per cent procaine hydrochloride or 1 per cent xylocaine. A 25 or 27-gauge hypodermic needle is used for the first infiltration (five to ten cubic centimeters) into the lateral border of the proximal one-third of the palm. A 22 or 23-gauge spinal needle is then used, and the xylocaine solution infiltrated subcutaneously throughout the palmar operative sites. The needle is inserted at two levels in the palm: the proximal third and the distal third. This technique produces excellent and dependable anaesthesia in the palm and all fingers. Separate infiltration is required at the base of the thumb and in the thenar eminence if surgery is to be performed at these sites. A sphygmomanometer cuff or pneumatic tourniquet is employed around the mid-forearm. This tourniquet was exceedingly well tolerated for as long as forty-five minutes—well within the time customarily used for this operation. In the instances where the operation had not yet been completed, the tourniquet was released for a few minutes and either reapplied or the remainder of the operation completed without it. Nearly all of the patients in this series were out-patients and were operated upon with only a barbiturate as the preoperative medication.

POSTOPERATIVE COMPLICATIONS

Complications have been few and, with two exceptions, were not serious. No severe infections developed. In the two instances of postoperative infection—the only instances where antibiotics were given—the infection was of low grade and of only a few days' duration.

Hematomata were a factor in impaired skin circulation at the operative site in four instances; in these a small focus of skin necrosis developed. Skin grafts were not needed. In only one instance did a large hematoma develop following extensive subcutaneous palmar fasciotomy. In this hand the skin was tented up and paper thin at several sites, but no necrosis of the skin resulted. There was not a single instance of skin necrosis from palmar subcutaneous fasciotomy when it was not associated with a skin incision. Skin incisions should be closed with sufficient space between the interrupted sutures to permit blood to find an exit.

The most feared and disabling complication is reflex sympathetic dystrophy. Fortunately it is rare, having occurred in only three instances of the 154 reported cases. In these three patients pain—generally of a burning character—stiffness,

reddish discoloration, and swelling of the fingers and wrist persisted for five to eighteen months. The pain and stiffness were severe in the shoulder and hand, but for the most part the elbow was spared. This is a distressing complication for both patient and doctor. Only one of these three patients regained full motion in the involved joints.

Hypalgesia

Impaired sensation in the form of hypalgesia occurred in eight instances. The cause was either division of a digital nerve during the operation or stretching a digital nerve (stretch neuritis) when the proximal interphalangeal joint was straightened after a protracted severe flexion contracture. In eight instances, the nerve was sufficiently injured to cause hypalgesia. In three hands there was recovery of normal sensation within a few weeks; in the other five the hypalgesia still persisted at the time of writing. For the most part the hypalgesia was well tolerated and caused the patient little concern.

In nearly all instances the digital nerves are more likely to be injured within the finger than in the palm. Palmar subcutaneous fasciotomy, when properly done, does not endanger the nerves, blood vessels, or tendons. The subcutaneous technique within the fingers is not recommended because of the danger of dividing a digital nerve. When there are large, eccentrically placed nodules in a finger they may be fused to a digital nerve. Even with direct vision it takes meticulous technique to prevent injury to the nerve. The nerves and vessels should be visualized proximal to the sites of encroachment and then dissected free.

Pain and itching: Disabling pain and itching occurred postoperatively in eight instances, but resolved in from two to ten weeks. In all the patients the stage of the disease was proliferative or early involutinal. Local injections of hydrocortisone at sites of symptoms proved helpful.

Recurrent contracture: Contractures recurred after having been corrected at operation in thirty-one hands. These recurrences were the result, principally, from irreversible capsular changes associated with protracted and severe flexion contractures, impaired extensor function, failure to divide completely the fibrous cords, and inadequate excision of the nodules. Flexion contractures of the proximal interphalangeal joint are the most difficult to correct and have the greatest propensity for recurrence, particularly in the little finger, while contractures of the metacarpophalangeal joint are much more tractable. Involvement of the proximal interphalangeal joint is difficult to treat since the capsular changes may be irreversible, particularly when nodules have involved the capsule.

When flexion contracture is long-standing the extensor apparatus may be impaired. The resulting muscle imbalance can be a factor in creating recurrent flexion contractures.

In nineteen hands (12.3 per cent), new nodules subsequently appeared in other fingers or in the palmar area, clearly separated from the site of surgery. This is not viewed as a surgical complication, but as a potential capacity of the natural process of the disease.

RESULTS

In presenting the results of the operative techniques used in this series, the cases will be divided into three groups according to the predominant stage of the disease existing at the time of the operation: proliferative, involutinal, and residual. The majority of the operations were carried out when the disease was in the involutinal stage—the one at which the patient usually requests treatment. Another factor accounting for the small number of cases treated in the proliferative stage has been the tendency to postpone surgery during this stage, except in those cases where a nodule directly overlies a proximal interphalangeal joint. Since there are no contractures in the proliferative stage there is seldom disability, although there may be pain and tenderness at the sites of the nodules.

Postoperative results are classified into three groups: good, fair, and poor. In the proliferative stage a good result is one in which there is no recurrence of a nodule in an operative area and no impairment of function. In the involutinal and residual stages a good result is a painless hand that is nearly normal in mobility, strength, and appearance. The classification of fair is given to a hand whose function has been substantially improved and in which the contractures have been corrected to at least 50 per cent. In the proliferative stage a slight nodular recurrence is also classed as a fair result. A result is classed as poor in a hand in which the contractures have been improved less than 50 per cent, or there is permanent stiffness. After surgery in the proliferative stage an obvious recurrence of nodules at a site of surgery is classed as a poor result. (A second operation was generally followed by a good result.)

Proliferative Stage

Twelve patients were treated by nodular excision. All had unilateral involvement and none had contractures. The results, as shown after two to ten years of observation, were: good in seven, fair in three, and poor in two. In the three patients who had fair results, there was a slight nodular recurrence at the site of surgery, necessitating further surgery, in one instance with a good final result. In the two patients who had poor results the nodule (or nodules) recurred. The result of a second operation was good in both cases. Nodules in the proliferative stage have the highest propensity for recurrence, and meticulous technique must be used when nodules are excised during this stage. Nonetheless if a nodule is located over, or adjacent to, the volar aspect of a proximal interphalangeal joint it is proper to remove the nodule even if recurrence is a threat. It is a brief and simple matter to remove a nodule from a hand locally anaesthetized; the patient experiences little incapacity. Even when it must be done a second time, it is far superior to the alternative of permitting the proximal interphalangeal joint to go into a severe flexion contracture with its disturbing incidence of irreversible periarticular and articular changes. Nodules at those sites where there is less potential of contracture can be observed.

Involutinal Stage

The contractures in this stage were treated by a combination of palmar subcutaneous fasciotomy and excision of nodules in the palm or fingers or both. The results in ninety-seven patients and 125 hands, as shown after two to ten years of follow-up, were: good in ninety-two (73.6 per cent), fair in twenty-seven (21.6 per cent), and poor in six (4.8 per cent). The fair and poor results were generally caused by irreversible joint changes and recurrent nodules. More meticulous excision of these finger nodules would have led to better end results in the fair and poor groups. This was indicated by the improved result after a second operation on two hands with poor results and nine with fair results. The ultimate results in the 125 hands were: good in 101 (80.8 per cent), fair in nineteen (15.2 per cent), and poor in five (4 per cent).

Subcutaneous Fasciotomy in Involutinal Stage

In fifteen patients (twenty-one hands) subcutaneous fasciotomy alone was carried out in the involutinal stage as a definitive procedure. Most of these patients were treated early in the study, and the results in these have firmly established that if nodules are left behind at the contracture-producing sites, they will generally cause partial or complete recurrence of the contracture. In these hands the results were: good in five, fair in seven, and poor in nine. In three of the five patients who had good results, the nodules were well advanced in their involution at the time of removal, while in the other two the nodules, although well defined preoperatively, seemed to have been destroyed by the operative procedure. In the seven patients who had fair results there were partial recurrences of

the contractures. The nine poor results could be attributed to leaving behind large nodules in close proximity to the proximal interphalangeal and metacarpophalangeal joints.

Residual Stage

Subcutaneous fasciotomy of the palm, in addition to sectioning of digital fibrous cords through small mid-lateral incisions, was carried out on thirty patients (forty-eight hands). The results, shown after two to ten years of observation, were: good in thirty-seven, fair in six, and poor in five. Many of the patients in this group were old or chronically ill, and this simple operation performed with the hand locally anaesthetized was welcomed by both the patient and his doctor. The fair and poor results were caused principally by irreversible soft-tissue changes although osteo-arthritis also played a part.

RESULTS IN THE TOTAL SERIES

After the initial operation and the revisions, the follow-up studies disclosed that in the entire group of 206 hands the results were: good in 164 (79.6 per cent), fair in twenty-nine (14.1 per cent), and poor in thirteen (6.3 per cent). All were followed for from two to ten years and, in a few instances, twelve years.

SUMMARY

1. A new concept of the pathogenesis of Dupuytren's contracture has been presented together with a plan of therapy based upon this concept. In the disease process three stages can be identified: the proliferative stage; the involutinal (contracting) stage; and the residual stage.

2. In a hand with nodules in the proliferative or involutinal stage, the sites and approximate degree of potential future flexion contractures can be predicted.

3. Operations, based upon the stage of the pathological process, were carried out, during a ten-year period, on 206 hands of 154 patients. The over-all results were: good in 164 (79.6 per cent), fair in twenty-nine (14.1 per cent), and poor in thirteen (6.3 per cent).

4. Selection and evaluation of therapeutic measures in Dupuytren's contracture should be based upon the stage of the disease existing at the time of the therapy.

5. The nodule is interpreted as the essential lesion; the fibrous cords are interpreted as hypertrophy of fascial bands reacting to intermittent tension stresses. Nodules require excision; the cords do not.

6. In the palm, the reactive fascial cords were sectioned by subcutaneous fasciotomy. In the fingers, the cords were sectioned (or a segment excised) by direct vision.

REFERENCES

1. ADAMS, W.: Contraction of the Fingers (Dupuytren's Contraction), and Its Successful Treatment by Subcutaneous Divisions of the Palmar Fascia and Immediate Extension. *British Med. J.*, **1**: 928, 1878.
2. BUNNELL, STERLING: *Surgery of the Hand*. Ed. 3. Philadelphia, J. B. Lippincott Co., 1956.
3. COOPER, ASTLEY: *A Treatise on Dislocations and on Fractures of the Joints*. London, Longman, Hurst, Rees, Orme and Browne, 1823.
4. DAVIS, A. A.: The Treatment of Dupuytren's Contracture. A Review of 31 Cases, with an Assessment of the Comparative Value of Different Methods of Treatment. *British J. Surg.*, **19**: 539-547, 1932.
5. DAVIS, J. S., and FINESILVER, E. M.: Dupuytren's Contracture. With a Note on the Incidence of the Contraction in Diabetes. *Arch. Surg.*, **24**: 933-939, 1932.
6. DUPUYTREN, GUILLAUME: *Leçons orales de clinique chirurgicale faites à l'Hotel-Dieu de Paris*. Vol. I, Chap. 1. Paris, Germer Baillière, 1832.
7. DUPUYTREN, GUILLAUME: Permanent Retraction of the Fingers, Produced by an Affection of the Palmar Fascia. (Translation.) *Lancet*, **2**: 222-225, 1834.
8. FINNEY, R.: Dupuytren's Contracture. A Radiotherapeutic Approach. *Lancet*, **2**: 1064-1066, 1953.
9. FINNEY, R.: Dupuytren's Contracture. *British J. Radiol.*, **28**: 610-614, 1955.

10. HAMLIN, EDWARD, JR.: Limited Excision of Dupuytren's Contracture. *Ann. Surg.*, **135**: 94-97, 1952.
11. HORWITZ, THOMAS: Dupuytren's Contracture. A Consideration of the Anatomy of the Fibrous Structures of the Hand in Relation to This Condition, With an Interpretation of the Histology. *Arch. Surg.*, **44**: 687-706, 1942.
12. KANAVAL, A. B.; KOCH, S. L.; and MASON, M. L.: Dupuytren's Contracture. With a Description of the Palmar Fascia, a Review of the Literature, and a Report of Twenty-nine Surgically Treated Cases. *Surg., Gynec., and Obstet.*, **48**: 145-190, 1929.
13. KEEN, W. W.: A New Method of Operating on Dupuytren's Contracture of the Palmar Fascia. Together with the Successful Use of Neural Infiltration in Such Operations. *Am. J. Med. Sciences*, **131**: 23-25, 1906.
14. KING, R. A.: Vitamin E Therapy in Dupuytren's Contracture. Examination of the Claim that Vitamin Therapy is Successful. *J. Bone and Joint Surg.*, **31-B**: 443, Aug. 1949.
15. KOCH, S. L.: Dupuytren's Contracture. *J. Am. Med. Assn.*, **100**: 878-880, 1933.
16. LOWMAN, C. L.: Plastic Repair for Paralysis of Abdominal Musculature. A Preliminary Report. *New England J. Med.*, **205**: 1187-1188, 1931.
17. LUCK, J. V.: Dupuytren's Contracture. *In* The Cyclopedia of Medicine, Surgery, Specialties. Vol. 9, pp. 391-394. Philadelphia, F. A. Davis Co., 1953.
18. MACREADY, J.: On the Treatment of Dupuytren's Contracture of the Palmar Fascia. *British Med. J.*, **1**: 411-414, 1890.
19. MASON, M. L.: Dupuytren's Contracture. *Surg. Clin. North America*, **32**: 233-245, 1952.
20. MEYERDING, H. W.; BLACK, J. R.; and BRODERS, A. C.: The Etiology and Pathology of Dupuytren's Contracture. *Surg., Gynec., and Obstet.*, **72**: 582-590, 1941.
21. RICHARDS, H. J.: Dupuytren's Contracture Treated with Vitamin E. *British Med. J.*, **1**: 1328, 1952.
22. SKOOG, TORD: Dupuytren's Contracture. With Special Reference to Aetiology and Improved Surgical Treatment. Its Occurrence in Epileptics. Note on Knuckle-Pads. *Acta Chir. Scandinavica*, **96**: Supplementum 139, 1948.
23. STEINBERG, C. L.: A New Method of Treatment of Dupuytren's Contracture, a Form of Fibrositis. *Med. Clin. North America*, **30**: 221-231, 1946.

DISCUSSION

PRIMARY TENDON REPAIRS

(Continued from page 598)

these distal joints and boutonnière deformity give us the most difficulty. In the latter we have used Fowler's method of tendon-grafting with improved function.

In flexor tendons we have not used the sublimis tendon of the index or long finger for the flexor pollicis longus but we have relied more on tendon grafts taken from the extensor tendons of the toes. Our grafts in the thumb extend from the distal phalanx to the thenar eminence.

It is refreshing to see that more and more delayed procedures are carried out in the lacerations in the flexor tendons of the fingers. In this series 107 tendon repairs were done as secondary operations. Repair of open fractures, crush injuries, saw injuries, and so forth, should be delayed.

We have just about given up the use of penicillin in our practice, not only because of the danger of anaphylactic reaction as mentioned here but also because of delayed allergic response. We do not use antibiotics routinely on our elective cases. In our acute injuries we use one of the broad-spectrum antibiotics.

I agree with Dr. Kelly that the primary repair of the flexor tendon in the sheath should be done only by interested surgeons. Many times this means that the resident just closes the skin or else the hand surgeon has to get up out of bed in the middle of the night and do the repair himself.