

ON SURGERY OF DUPUYTREN'S CONTRACTURE*

JACK E. DAVIS, M.D.†

Buenos Aires, Argentina

After reviewing the literature on Dupuytren's contracture, two basic facts are evident: (1) ignorance of the cause of the contracture, (2) lack of statistical surgical experience in the entity. This paper is an attempt to break through these two barriers.

With no intention of replotting the field of facts known to most plastic surgeons, it is well to remember that the contracture was probably first mentioned by Felix Plater²⁶⁷ (1614) and that "crispatura tendinum" of "manus apostolicus" was attributed to disease of the palmar fascia by Henry Cline (1808) and Sir Ashley Cooper⁵⁵ (1822) before Baron Guillaume Dupuytren's famous lecture on December 5, 1831. Veritable chaos in pathology ensued and the cause thought to be fibromata of the palmar fascia,^{160, 235, 308, 350} chronic inflammation with residual scar formation,¹⁵ sarcomata without malignancy,¹⁵⁵ fibroplasia-like keloids or desmoids¹⁴¹ and progress of hematoma from micro-trauma.³⁰⁸ Although Richter²⁸² and Chevrot²³⁵ first attempted histology, Langhans¹⁸⁵ described the typical changes, especially around the vascular adventitia. Krogius¹⁷⁰ observed the distinction between new and old connective tissue. Iklé¹⁴⁰ pointed out the multifocal origin. Abbé¹ and others drew attention to nervous influence. San Martino^{294, 295} considered small vessel involvement.

The relative success of trial and error surgical procedures, in proportion to the disability produced by the contracture, can explain the limited statistics. Many skin incisions allow different approaches and solve the surface defects. However, the pathology is underlying. Subcutaneous division of the bands was introduced by Cooper,⁵⁵ open incision by Dupuytren,¹⁶ band excision by Kocher,¹⁷⁶ "total" fasciectomy by Lexer,²⁰² nodulectomy by Routier²⁸⁹ and extended band excision termed "limited fasciectomy" by Hamlin.¹²⁵ These procedures have been subsequently reported by many, and perhaps in our day McIndoe has most contributed to the popularity of radical excision, Hueston to the limited, and Luck to blind fasciotomy. Blocking of the stellate ganglion was pioneered by Keen.¹⁰⁶

There are milestones in the literature and in this century mention must be made of the scholarly contributions of Coenen,⁴⁸ Kanavel and associates,¹⁶⁰ Meyerding and associates²³²⁻²³⁶ and Skoog.³⁰⁸

We have performed three basic studies on the only real material for investigation: the human patient. The product of this work and other observations in our experience have combined to form a theory that has been applied in

Presented at the annual meeting of the American Society of Plastic and Reconstructive Surgery, San Francisco, October 13, 1964.

* From the British Hospital and the Hospital Español, Buenos Aires, Argentina.

† Awarded First Prize, Senior Division, in the 1964 scholarship contest of the Foundation of the American Society of Plastic and Reconstructive Surgery.

practice. We are now able to report on the results achieved in surgery with this development.

Associated Conditions

Our incidences of sex (78 per cent male, 22 per cent female), age (from 17 to 77 years, average 52) and finger involvement were similar to previous compilations. Possibly associated conditions have been sought in the heart and mediastinum, the nervous system, "fibroplastic diatesis," the lower cervical spine, the sole and the penis.

We found diabetes in 3 per cent of these patients. Routine heart and EKG examinations were also in keeping with age group findings. This is in contrast to Kehl and others, who relate association with cardiac infarct. We have not observed a high proportion among epileptics, as have Lund and Skoog. We screened 500 and found no Dupuytren. Six per cent of our operated group were epileptic. Rheumatic tendency was frequent, but can usually be established preoperatively and after care planned accordingly. *Eighty-six per cent of our cases had osteoarthritis of the lower cervical spine.* Knuckle pads appeared often, but we observed no relation to type of contracture, progress of the disease or postoperative course. Keloids have not occurred in our operated cases. Eight per cent also had plantar retraction. So-called Ledderhose's disease is different from palmar retraction in distribution and progress. The variations are possibly in keeping with general foot pathology as compared with the hand, but our experience is too limited to be conclusive. In this series only 2 had induratio penis plastica. Peyronie is not a clinically defined entity, as Dupuytren's contracture. In our two urologic services, of 52 cases classified as Peyronie, only 2 also had palmar contracture. We consider Peyronie's disease to be a coincidental and not an associated condition.

Monkey Experiments and Traumatic Dupuytren

Excellent studies have been done by Skoog, Larsen and Posch, and Larsen, Takagishi and Posch, who have stretched monkey fascia and report equal microscopic observation to Dupuytren's contracture. They infer traumatic etiopathology. There are two flaws in this reasoning: (1) To establish Dupuytren there must be contracture. They have been unable to reproduce it in monkeys. (2) Their microscopic observations do not make a diagnosis, including hemosiderin deposits. We have seen palmar nodules appear in cases of attrition of the hand, which do not produce a contracture and gradually disappear in the course of years. In these, and in retractile and hypertrophic scars that cross a flexion crease in the palm, the microfindings have resembled, but both were obviously not, Dupuytren's contracture.

We have had three unequivocal cases of post-traumatic Dupuytren's contracture. Two were after oblique wounds in the palm, the third followed a crush injury. The other hand was normal in all cases. These contractures characteristically progressed to 30° to 40° in 3 months, commenced with trauma and were painful and tender. Surgical excision was eventually satis-

factory, but the postoperative course was very slow and pain continued for many months.

Wounds on Dupuytren's contractures established and in progress have systematically been observed to hasten the course of the disease. This is especially important to avoid inadequate surgery. It is here that microtrauma, such as passive stretching, can trigger retraction.

ULNAR ARTERY INVESTIGATION

During surgery, we soon observed that the ulnar artery was very irregular. So an arteriographic study was performed on 40 hands. The outstanding finding was a similar abnormality in 39 cases. This has been designed for a usual ring finger contracture and compared with the normal (fig. 1). The ulnar artery was dilated, tortuous and delayed with relation to the radial. Marked hypothenar collateral circulation occurred. Digital arteries were abnormal. X-rays taken at the moment the arteries were filling illustrate variations in different types, as compared to a normal hand (figs. 2, 3). The exception to this rule was a total "stop" of the ulnar artery (fig. 3.D). Comparison is shown with a normal case (fig. 4). That this abnormality is prior to contracture is strongly suggested by three observations: (1) it appears equally and symmetrically in a patient with a minimal nodule in one hand and a marked contracture in the other; (2) after fasciectomy, the image persists (it has been observed up to 3 years) although all tissues were soft in the operated palm; (3) in one unilateral case, we took x-rays on the sound side and also found the typical design. One year later contracture appeared in this sound side.

Angiocinematography was performed in a similar manner and the motion studied picture by picture. The dye normally reached the hand, but suddenly

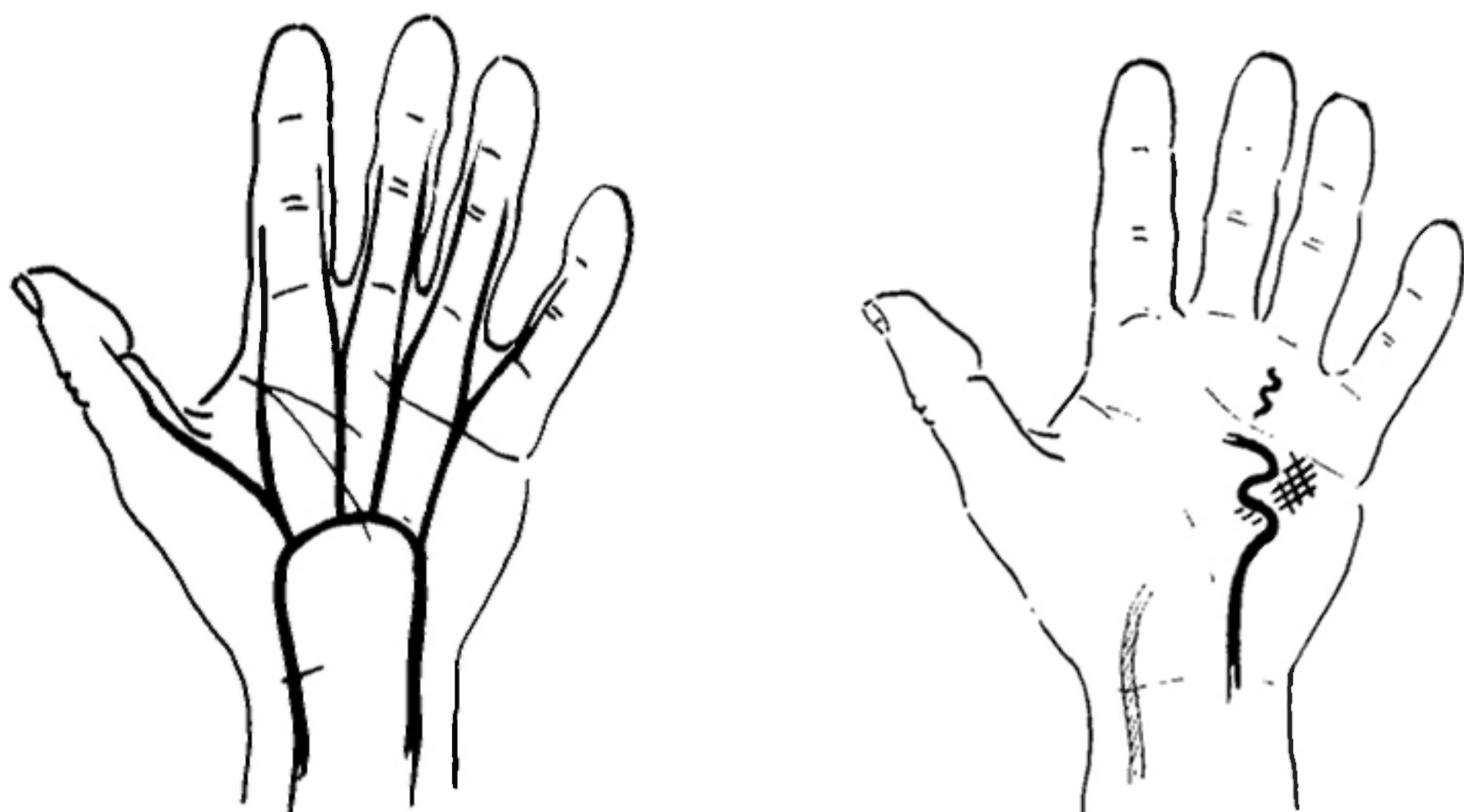


FIG. 1. *A*, a normal hand. *B*, a Dupuytren, showing the "snake," altered digital rami, and hypothenar collateral circulation.

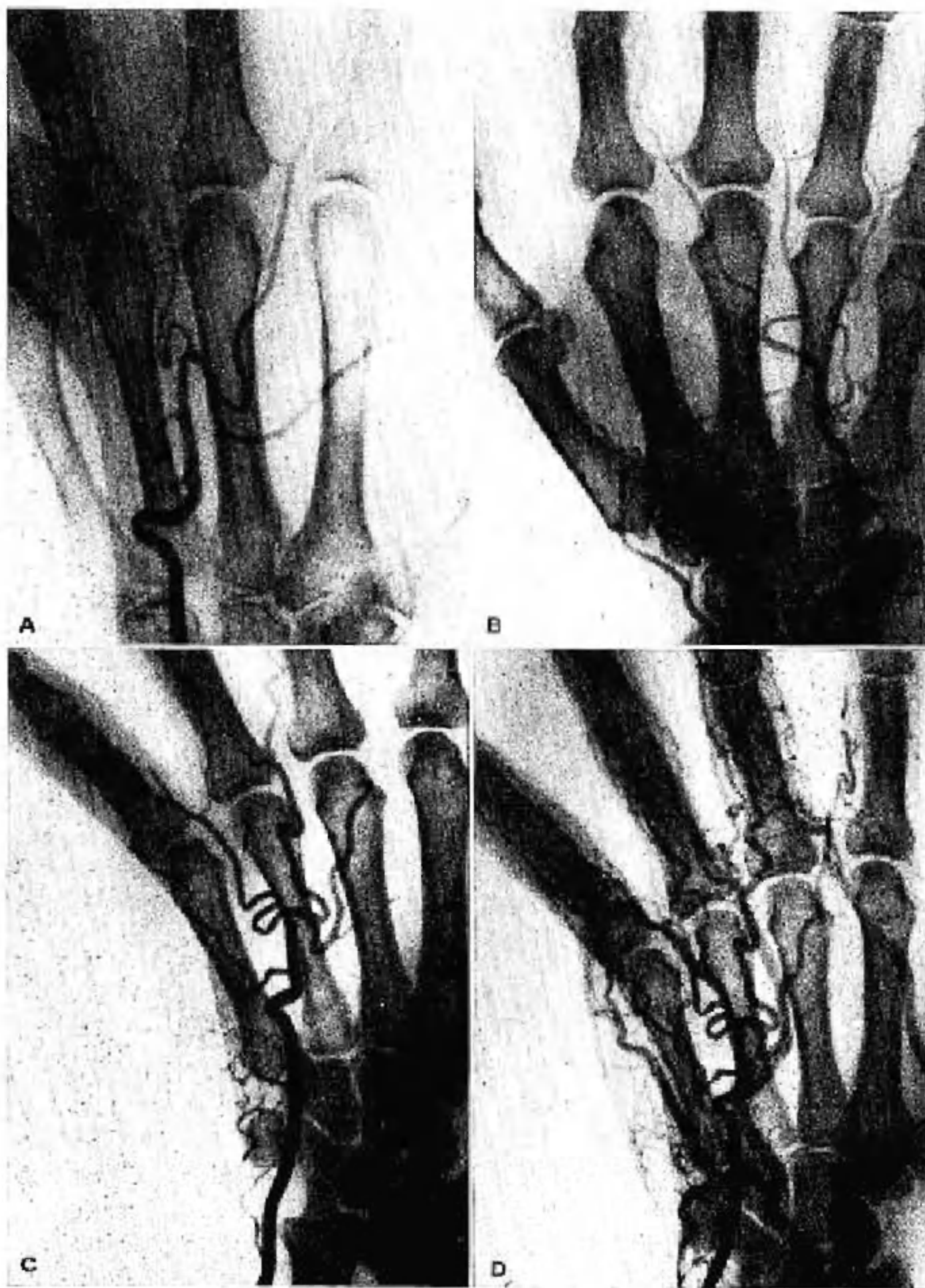


FIG. 2. *A* and *B*, ring finger contracture. *C*, ring finger contracture to show the arteries filling; the palm. *D*, the digital arteries.

paused at the "snake" for several seconds. This is a real index of sluggish circulation at this point.

In all these studies radial arteries and branches have been entirely within normal limits. Technical faults and interpretation have been carefully analyzed to sieve out only positive data.

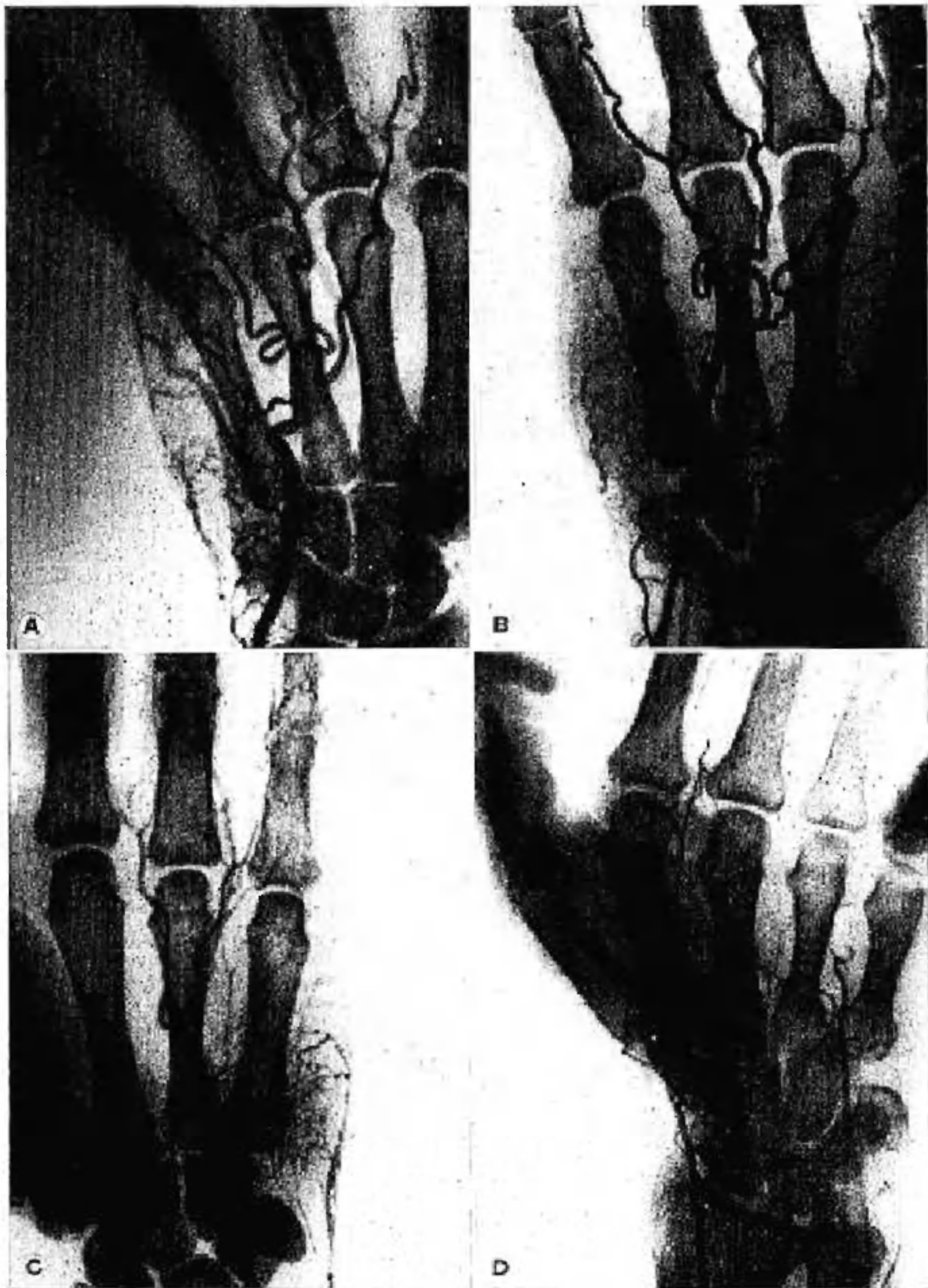


FIG. 3. *A*, ring finger contracture; the hypothenar network is filled last. *B*, contracture of the last three fingers. *C*, ring and little finger bands; marked hypothenar circulation. *D*, severe little finger contracture; "stop" of the ulnar artery in the palm.

An interesting observation was the *pale wave* sign. On injecting the radiopaque medium above the elbow, blood supply was blocked in both forearm arteries and the hand became a livid white. A hyperemic wave appeared with returning circulation and progressed in the wake of subsiding paleness. At a

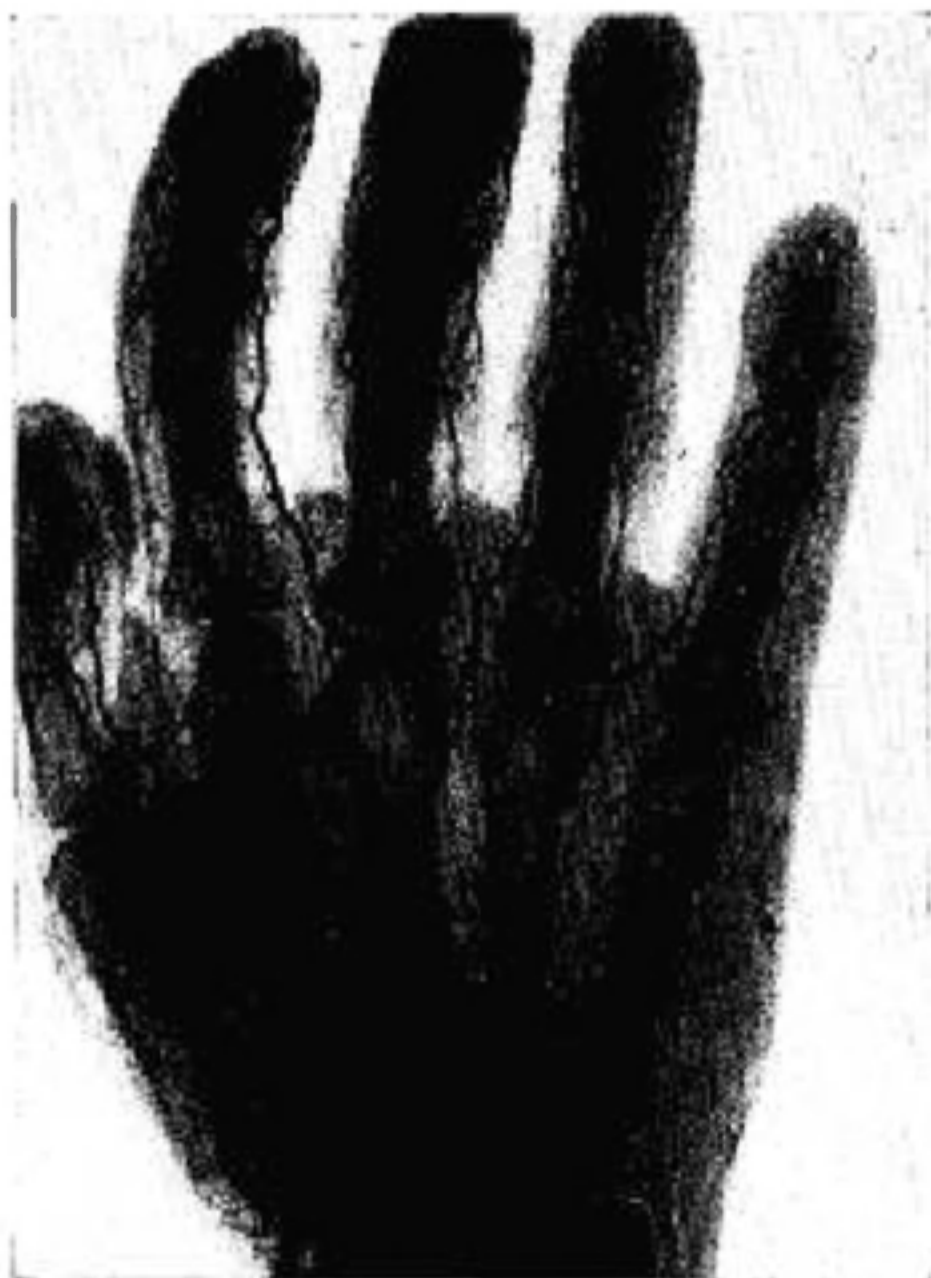

FIG. 4. Normal case for comparison

given moment, and lasting for 2 sec., the diseased palm was outlined in white on a deep red background. This outline was more exact than palpation in limiting the pathology. The value of this sign is to: (1) control that both radial and ulnar arteries have filled simultaneously; (2) time the precise moment for taking x-rays, which can be calculated by watching the "wave" progress.

Circulation of the palm has been studied by injecting liquid plastic (Markee and Wray) and with radiopaque medium (Conway and Stark). These studies were in dead hands, but enhance the following points: (1) over 30 per cent of the blood volume is in the central palm; (2) the mid-palm has the least circulation ("mesopatamia"); (3) circulation in the palm is concentrated into two networks: subpapillary and subdermal.

Microscopically, we have observed that these two networks fuse at the distal palmar crease in normal hands (fig. 5). This is the point of least blood supply in the palm and exposed to maximum movement. In Dupuytren's contracture there is interruption of the deep network and development of the superficial from this point distally (fig. 5).

Briefly: we have found an abnormality of the ulnar artery in all cases of Dupuytren's contracture producing a delayed and sluggish circulation and this appears to precede the contracture. The point of maximum abnormality is where the artery crosses the distal flexion crease. The radial arteries and branches and the venous return flow were normal.

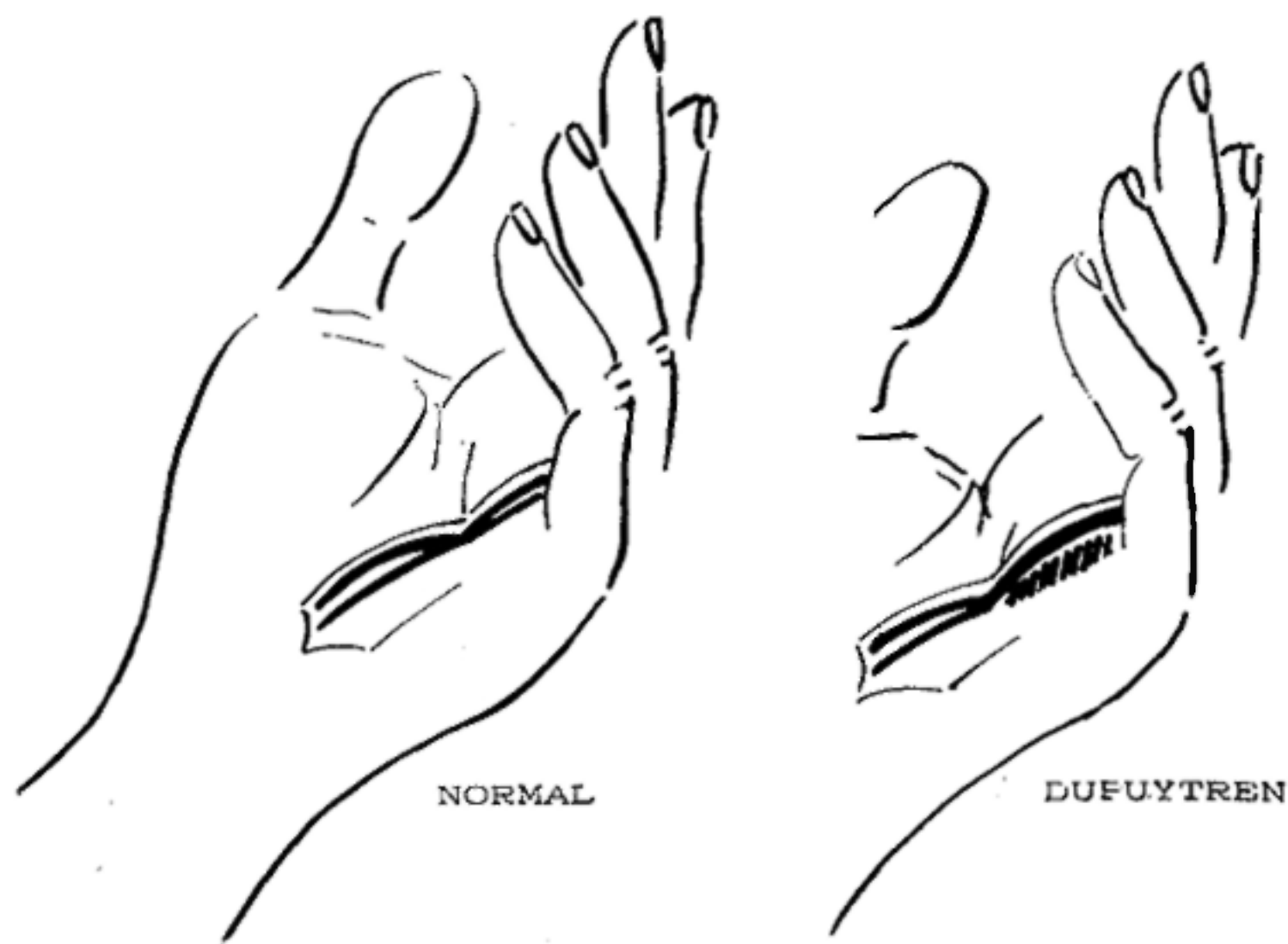


FIG. 5. A normal case and a Dupuytren

ULNAR NERVE STUDY

While operating, we noticed that in contractures involving the last three fingers, the collateral branches of the ulnar nerve frequently also supplied these three fingers. Many times, on examining the nerves more carefully, anastomotic fibers were seen going obliquely from the ulnar to the medial branches in the palm and not inversely. So examination by blocking the ulnar nerve at the elbow was carried out on 42 hands with Dupuytren's contracture. Both anesthetic and anhydrotic areas have been mapped out: loss of sensation has been lined and loss of sweat dotted (figs. 6-9). Results varied with regard to sensation and were not conclusive, but the outstanding finding was that trophic ulnar nerve supply (tested by sweating) was regionally exactly that of the diseased fascia, including atypical cases, in 100 per cent of these patients. This was even true in contractures of the thumb and index finger. On blocking the ulnar nerve, these areas did not sweat, *i.e.*, anastomotic fibers from the ulnar to the medial supplied these regions of contracture.

We wish to call attention to the "*atrophic skin triangle*," usually seen in the distal palm. The vertex of the triangle in a nodule, localized in the distal flexion crease. The triangle spreads in a fan shape distally. There is frequently a history of pain or disaesthesia and if examined early and carefully, it is usually tender. Sebaceous glands below the skin are microscopically normal, except for minor changes in the most advanced stages. The skin has normal corium, but is thin, hyperkeratotic, without sweat, creaseless and shrunken. The only plausible explanation is a functionally severed trophic nerve supplying the region (fig. 10A).

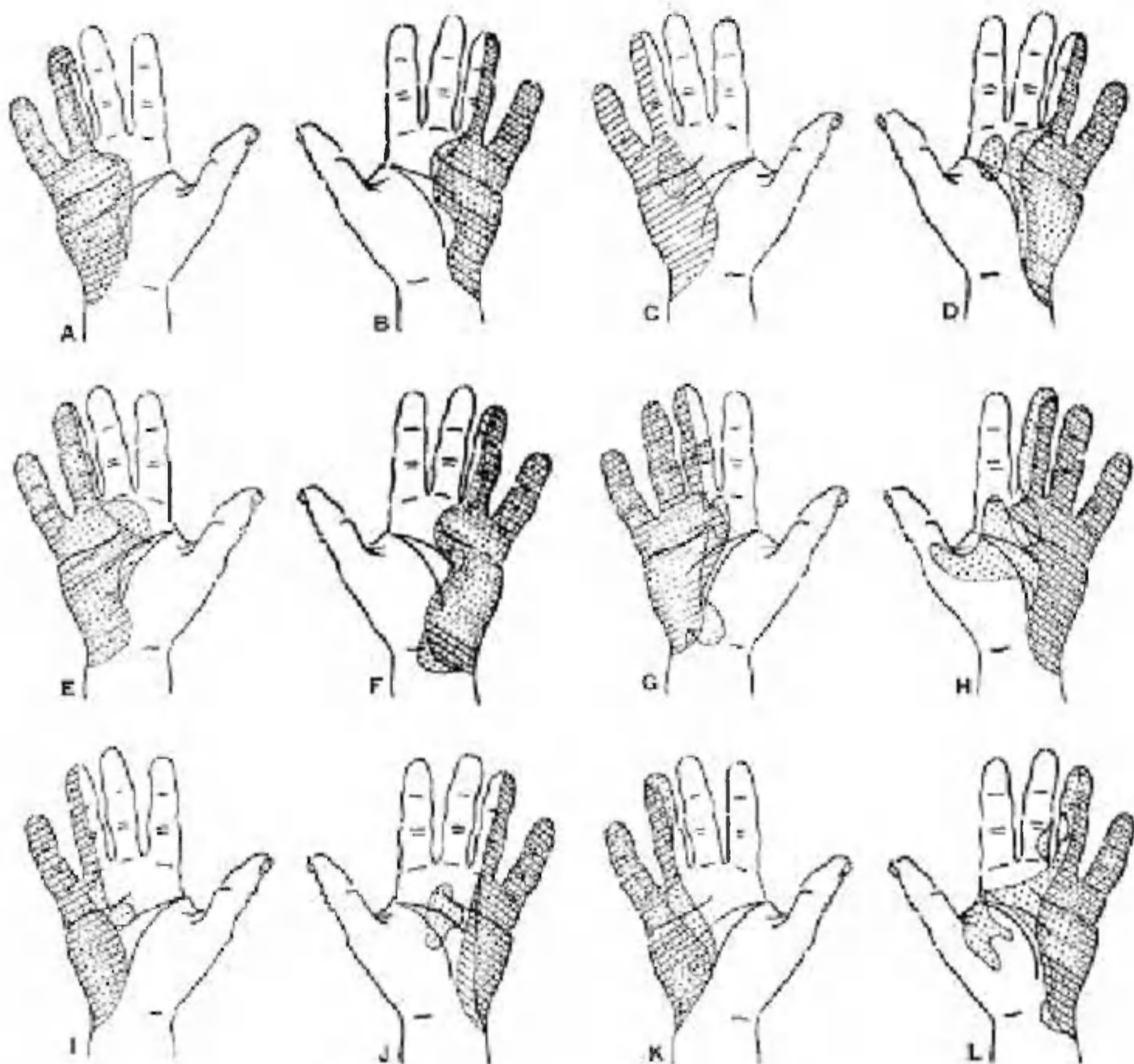


FIG. 6. *A*, (patient I. B.) ring and little finger bands with 20° retraction of both digits. *B*, symmetrical pathology. *C*, (J. L. P.) palmar nodule without band or retraction. *D*, 40° contracture of the ring finger, 20° contracture of the little finger; nodule in index ray. *E*, (O. P.) 30° contracture of the ring finger, 15° of the little finger (recurrence); two nodules in the 4th ray. *F*, nodule and band with 15° retraction of the ring finger. *G*, (S. C.) retraction of the last three fingers: middle, 20°; ring, 30°; and little, 20°. *H*, practically symmetrical condition with regard to the fingers, but nodules and incipient retraction at the base of the thumb and first web are evident; note that the ulnar region of sensation also involves the last three fingers. *I*, (A. V.) 30° retraction of the ring and little fingers. *J*, 10° retraction of the ring and little fingers; midpalmar nodule. *K*, (S. S. C.) ring and little fingers with retractions of 60° and 30°, respectively. *L*, 30° retraction of the ring and little fingers. The natatory ligament between the middle and ring fingers is grossly involved; nodules in the midpalm and first web.

BRACHIAL PLEXUS EXPLORATION

Eight brachial plexi have been explored during treatment for Dupuytren's contracture. Three of these cases were associated with ulnar paralysis, which appeared coincidentally with the contracture and had been slowly progressive. One patient was an alcoholic who also had bouts of polyneuritis. The ulnar picture was independent from the polyneuritis, although both may be interpreted as neurolability. The other two cases with paralysis had no other nervous signs. The remaining five had only the contracture.

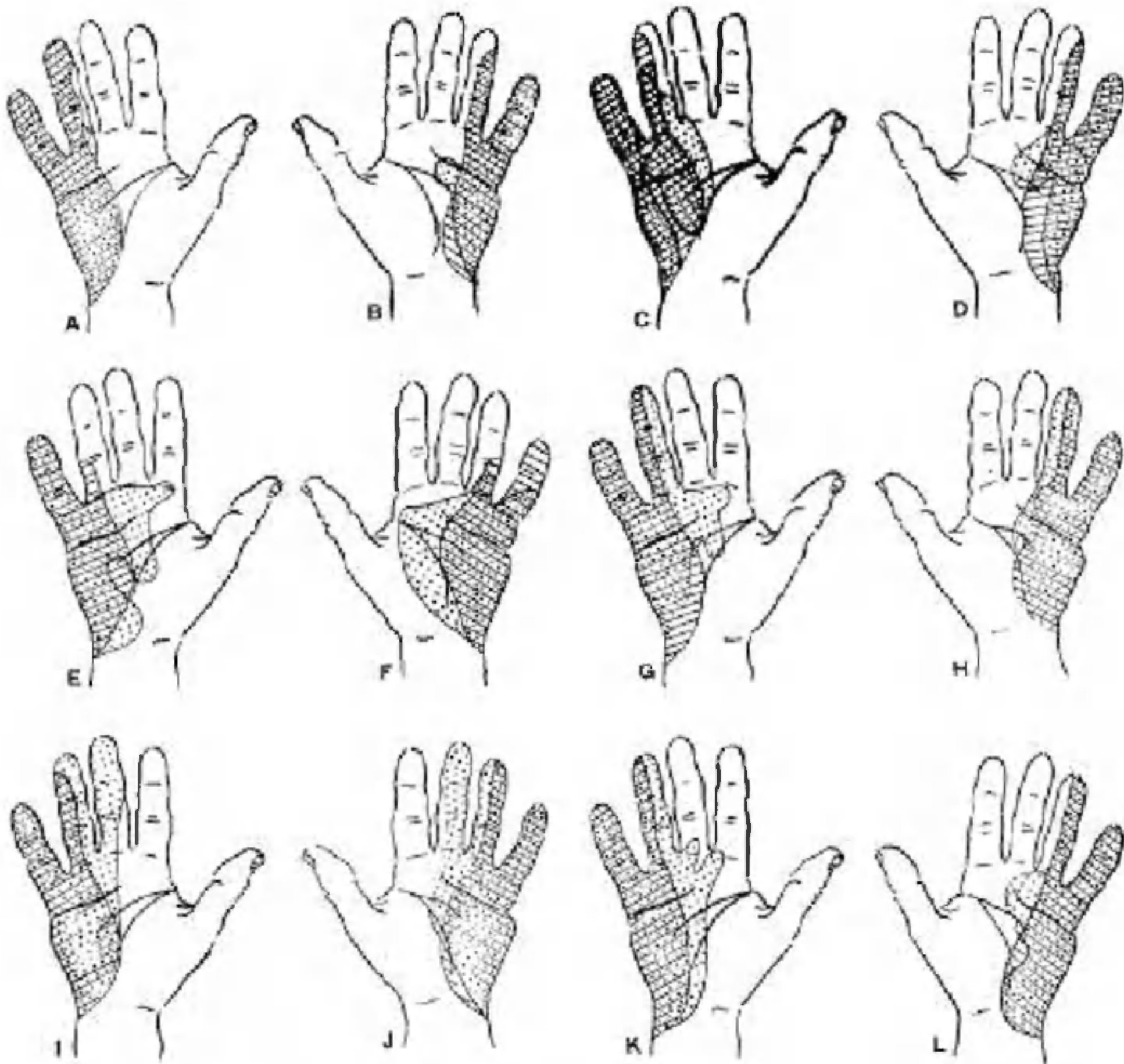


FIG. 7. *A*, (*A. B.*) palmar nodule. *B*, ring and little fingers with retractions of 60° and 30° , respectively; large nodules in palm. *C*, (*N. P.*) 30° contracture of the ring and little fingers. *D*, 20° retraction of the ring finger with slight retraction of the little finger. *E*, (*L. V. V.*) contracture of the last three fingers: middle, 10° ; ring, 20° ; and little, 20° ; 4 nodules in the palm. *F*, contracture of the last three fingers: middle, 20° ; ring, 20° ; and little, 15° ; 3 nodules in the palm. *G*, (*E. M.*) 30° retraction of the ring finger with bands in the web to the middle; slight little finger retraction. *H*, nodules in the palm with incipient ring and little finger retraction. *I*, (*N. F.*) contracture of the last three fingers: middle, 30° ; ring, 50° ; and little, 40° . Bands are spreading to the last phalanx of the ring finger and there are web bands with marked hypertrophy. *J*, symmetrical distribution of the process, but of more recent origin. Several nodules in the palm. Middle finger retraction, 15° , ring, 20° , and little, 10° . *K*, (*O. F.*) nodules in the palm, 15° retraction of the ring finger; some bands spreading to the web and middle finger. *L*, symmetrical condition.

After observing improvement with stellate blocking, brachial plexi were explored surgically. Approach was through a decompressive scalenotomy. In one patient, a diabetic, a rigid arteromatous subclavian artery was found pressing on the plexus and 10 cm. of the disease vessel removed. In the remaining seven cases no abnormality was observed and sympathectomy performed from C4 to D2. All cases improved, but to a varying degree. The most spectacular was a 60° ring finger retraction with a single band. Four hours after the operation the hand was red and dry and the finger could be totally extended! Other cases

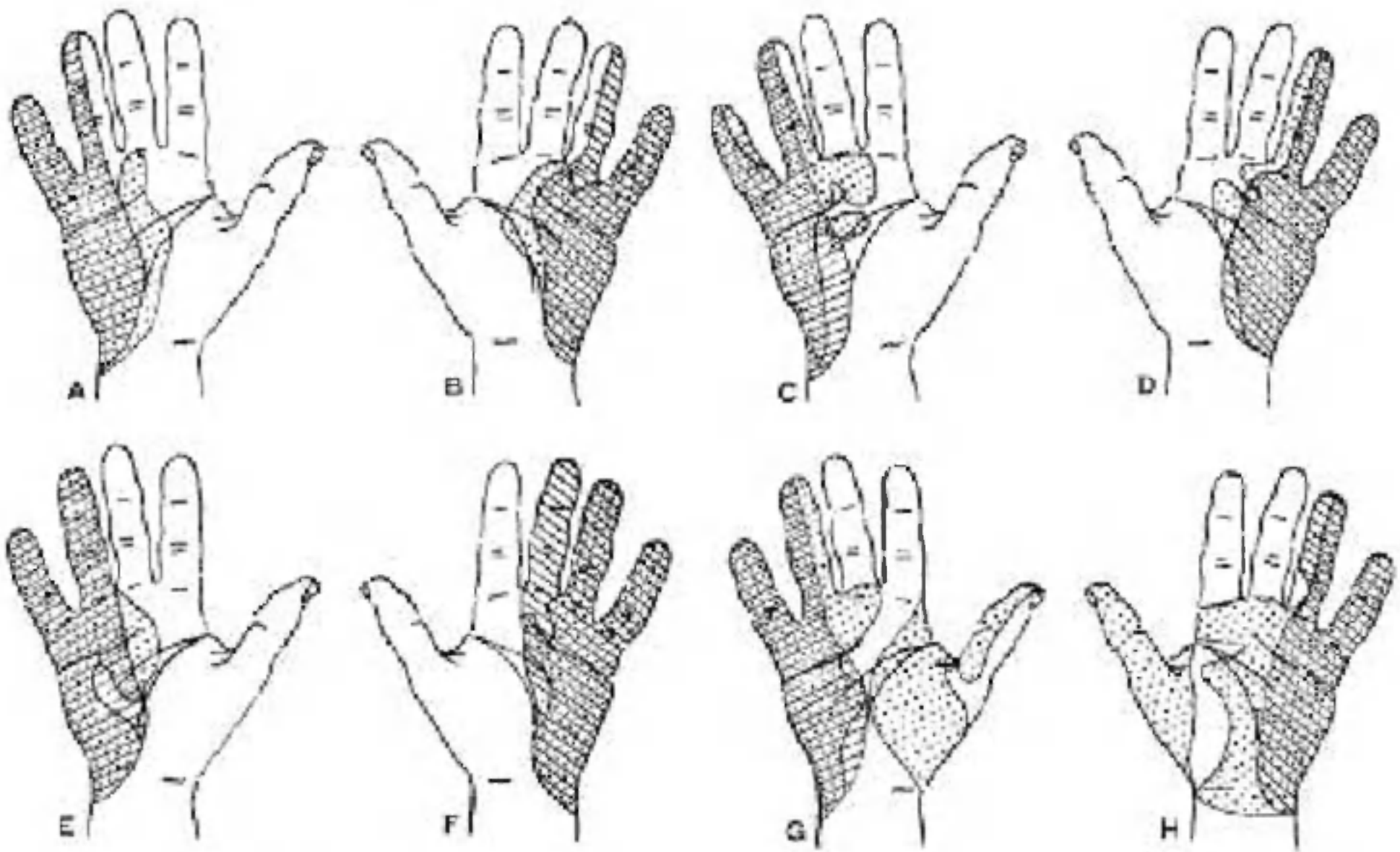


FIG. 8. *A*, (O. J. R.) nodules in the palm and slight ring and little finger retraction. *B*, symmetrical condition. *C*, (M. A.) 30° retraction of the ring and little fingers with web band to the middle finger. *D*, retraction of the ring and little fingers, 20° and 15°, respectively; some web bands to the middle. *E*, (G. P.) 20° retraction of the ring finger and slight retraction of the little finger. Large single nodule in the palm which was painful and tender. *F*, a single nodule in the palm, symmetrical with the other side, painful and tender. *G*, (M. G.) a case of severe bilateral disease with 90° of the ring and little fingers and 60° retraction of the middle finger. There are retractile nodules at the base of the thumb and the first web. *H*, similar involvement but not quite as severe. There is also 20° retraction of the index finger.

improved from 20° to 40°. The effect of the sympathectomy gradually subsided and was gone 1 to 3 years later. The contracture recurred with abeyance of vasodilation and return of sweating. In three cases radical palmar fasciectomy was performed with the sympathectomy. These hands progressed exceptionally well, practically without edema and had full movement in 20 days.

The ulnar paralysis improved in all three cases, with return of sensation, active movement and trophism (muscles increased in volume, ulnar claw relaxed, sweating returned to the dry surface, fingerprint, finger volume and nail quality improved and coldness with easy cyanosis subsided).

Therefore, improvement varied. These are the only cases of Dupuytren's contracture on record so far with brachial plexus investigation, decompressive scalenotomy, sympathectomy and one excision of a diseased artery squeezing the lower trunk.

MICROSCOPIC STUDY

The microscopic picture is like examining the disaster produced by a bomb. We view the consequence, but we must search and find where the bomb was placed and how it exploded. To investigate functional pathology, sections have been cut in parallel layers, so that everything from skin to sheath was included

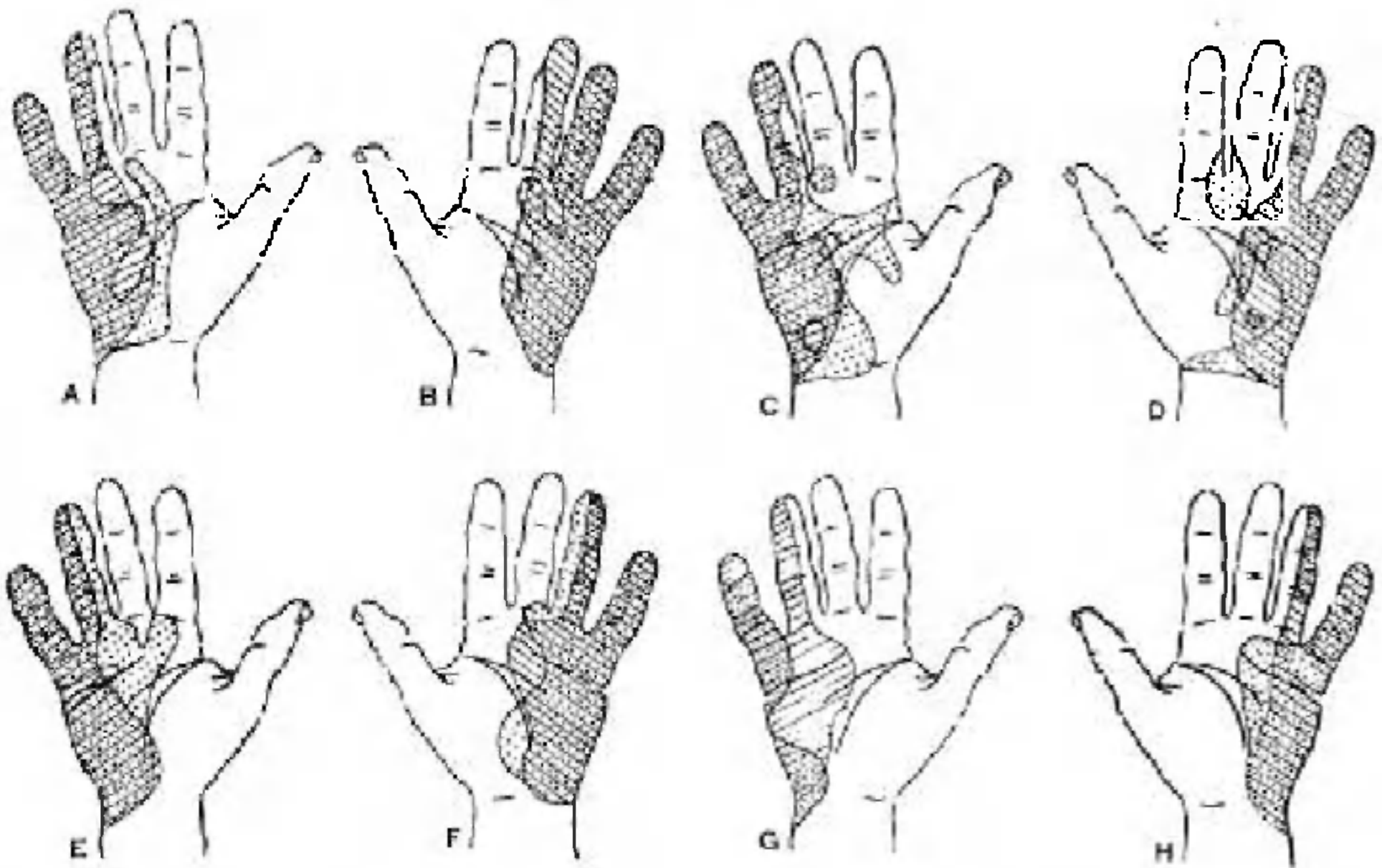


FIG. 9. *A*, (A. R.) 20° retraction of the little finger with a band to the ring finger. *B*, similar distribution, with 15° retraction of the ring and little fingers. Note that in this case, as in the left hand illustrated in figure 8. *F*, the ulnar area of sensation did not coincide with the pathology. *C*, (E. D.) severe recurrence with retraction of the index, middle, ring and little fingers 15°, 60°, 70°, and 90°, respectively. This case was operated upon 4 months ago with so-called "radical" fasciectomy. *D*, final band with 10° retraction of the ring finger and slight retraction of the little finger. *E*, (W. G.) 30° retraction of the ring finger and 20° retraction of the little finger. The middle finger is slightly contracted by a band. *F*, similar distribution but less contracture; 15° retraction of the ring finger and slightly less in the middle finger. *G*, (J. B. G.) marked little finger contracture of 60°. *H*, slight little finger contracture of 20° with bands to the ring finger without contracture.

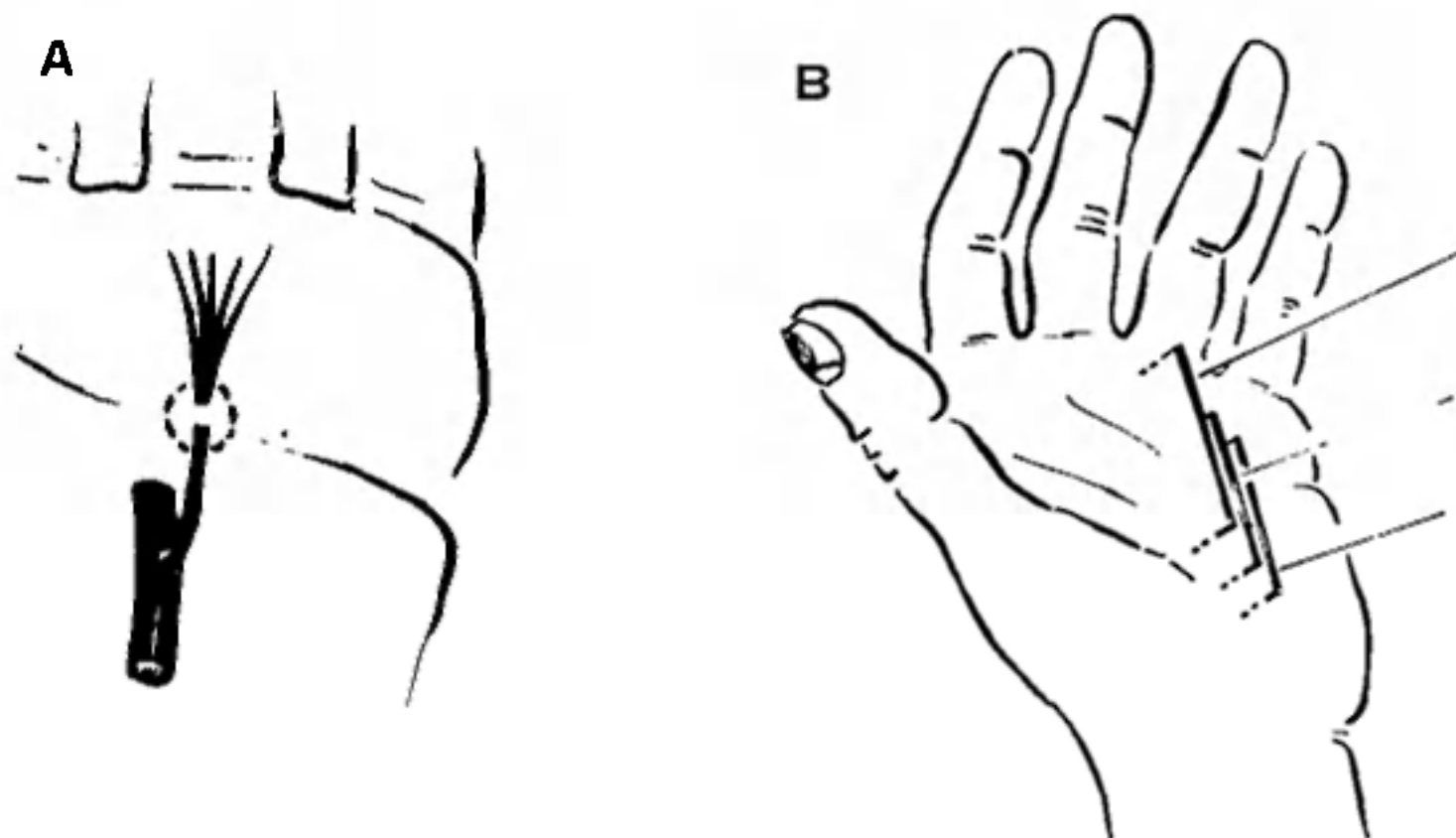


FIG. 10. "Atrophic skin triangle" syndrome

(fig. 10.B). Slides were stained with hematoxyline and eosine, Masson's trichromic, Gallego's, Prussian blue and silver.

Previous authors^{147, 186, 308-310, 350} have made the following observations: (1) Nodules are richly cellular with immature fibroblasts. They change with

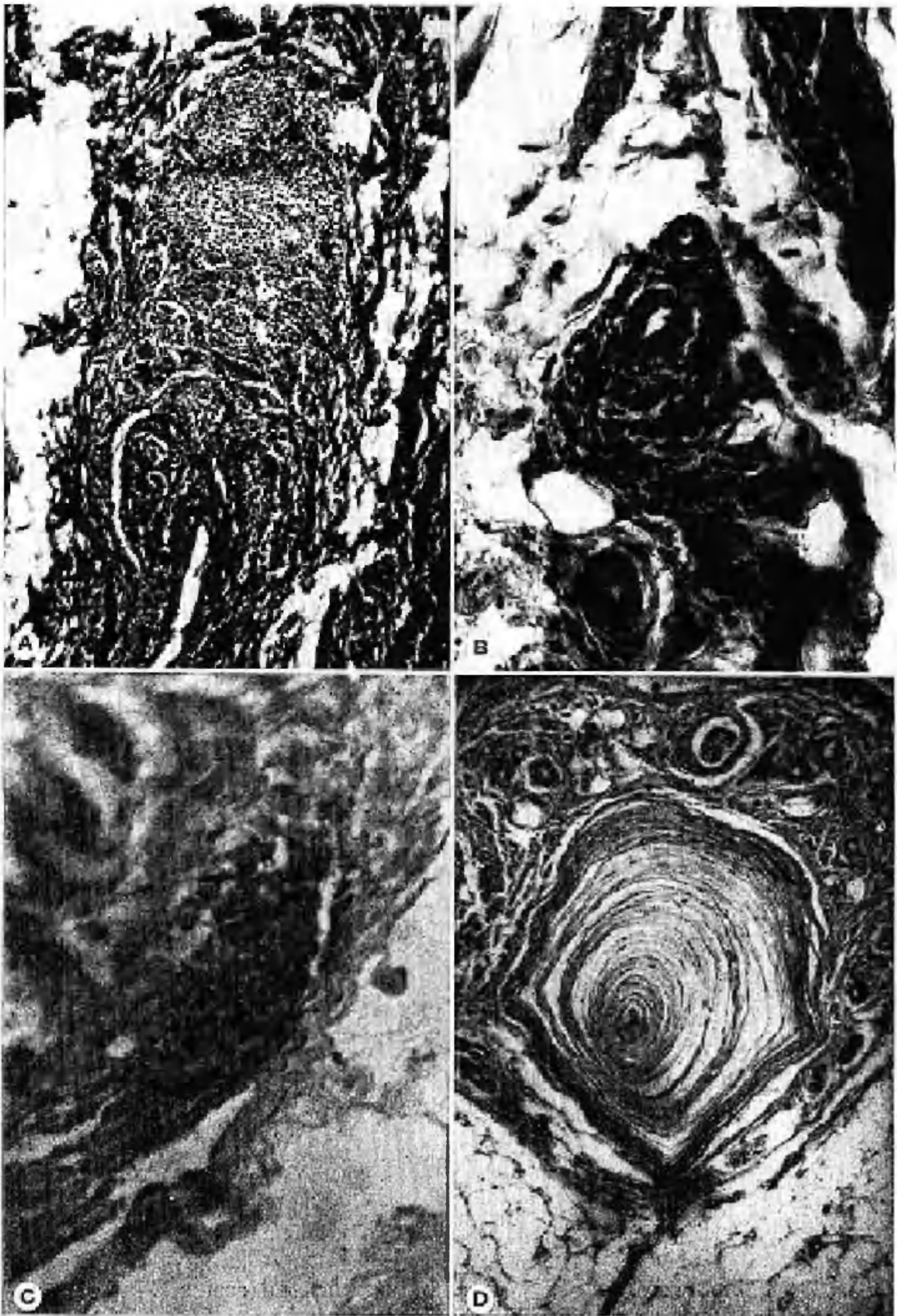


FIG. 11. *A*, interfascicular lymphocytic infiltration. *B*, perivascular lymphocytic infiltration. *C*, hemosiderin deposits. *D*, edema of the Paccinian bodies.

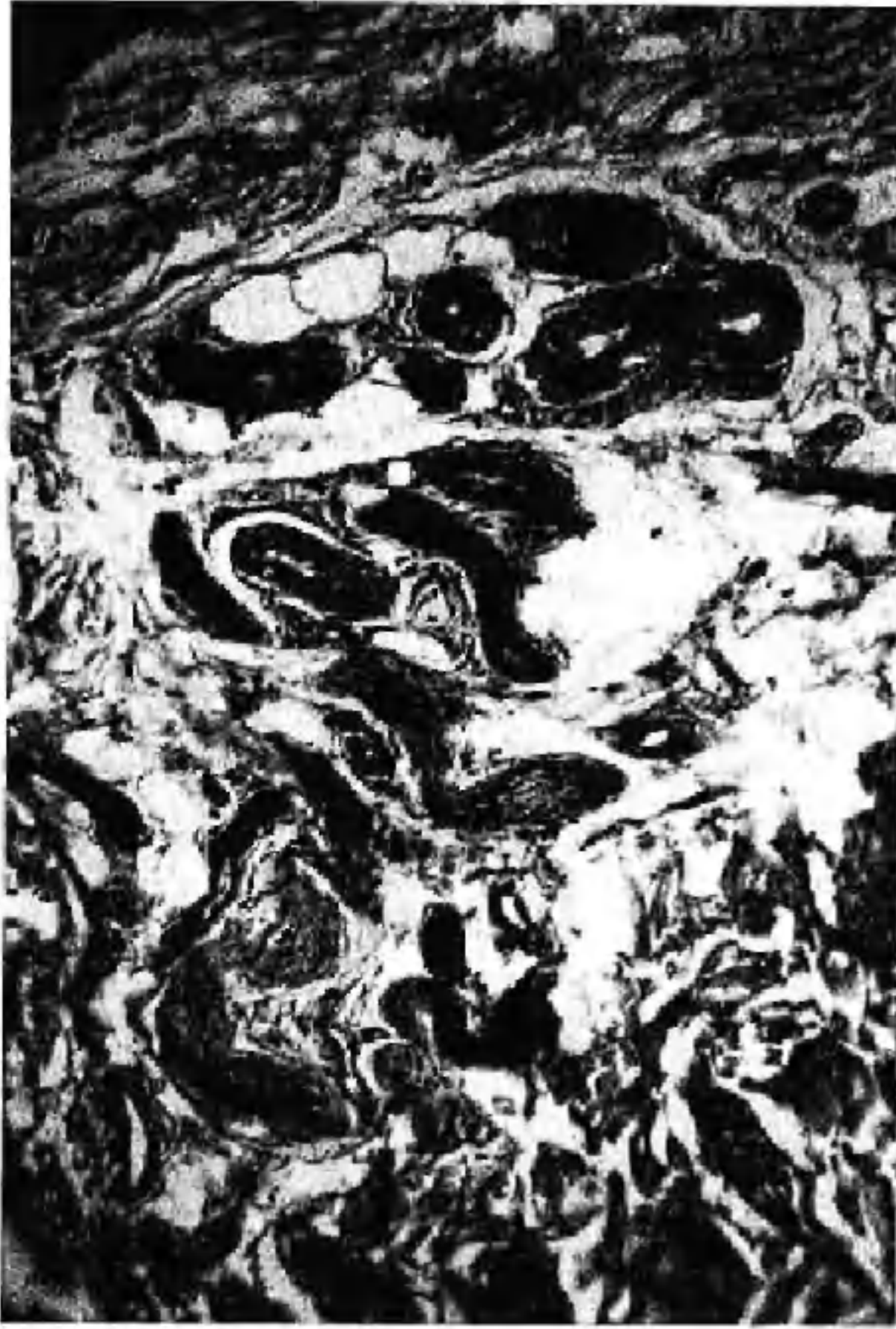


FIG. 12. Normal sweat glands

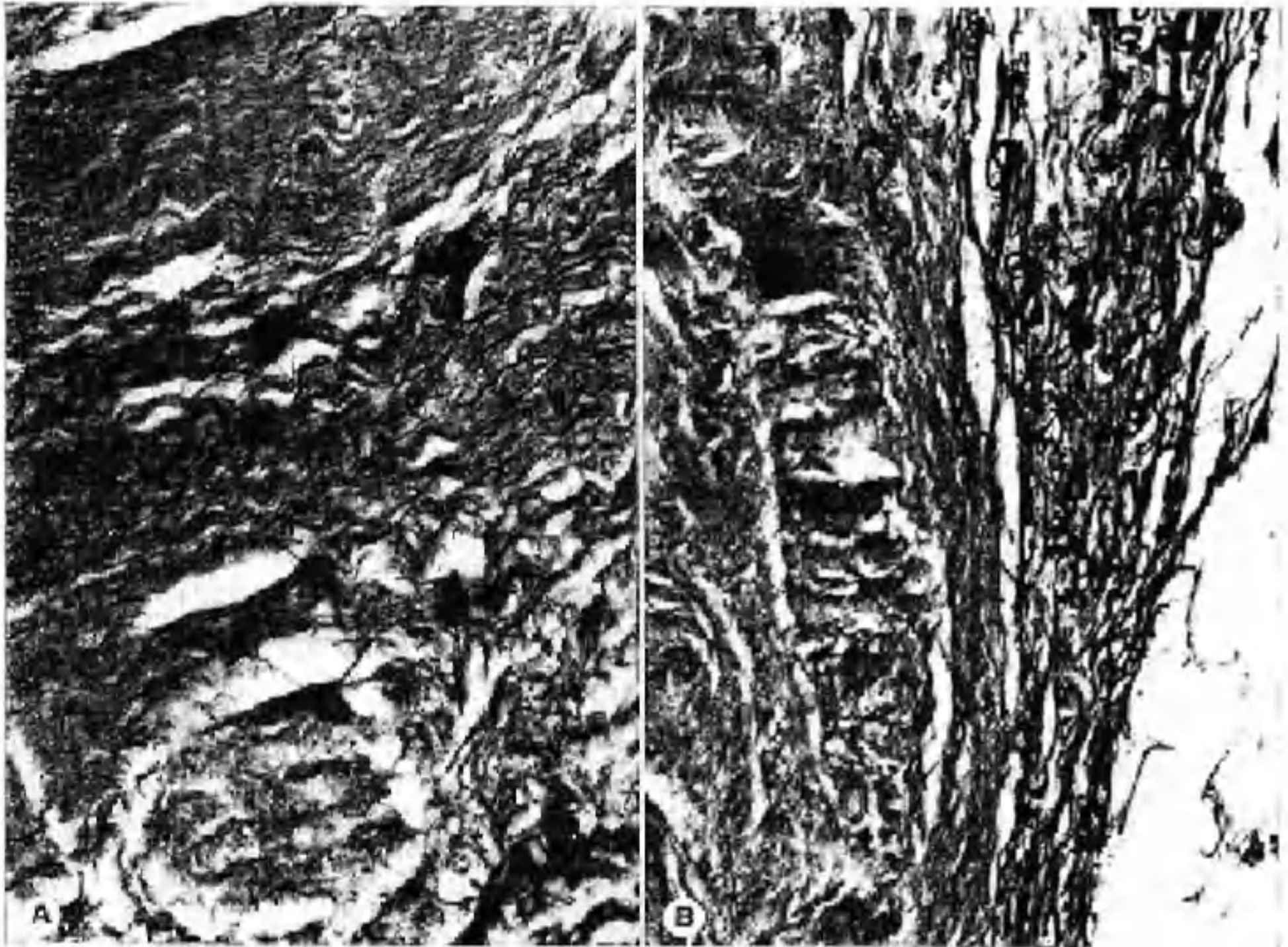


FIG. 13. *A* and *B*, normal elastic fibers

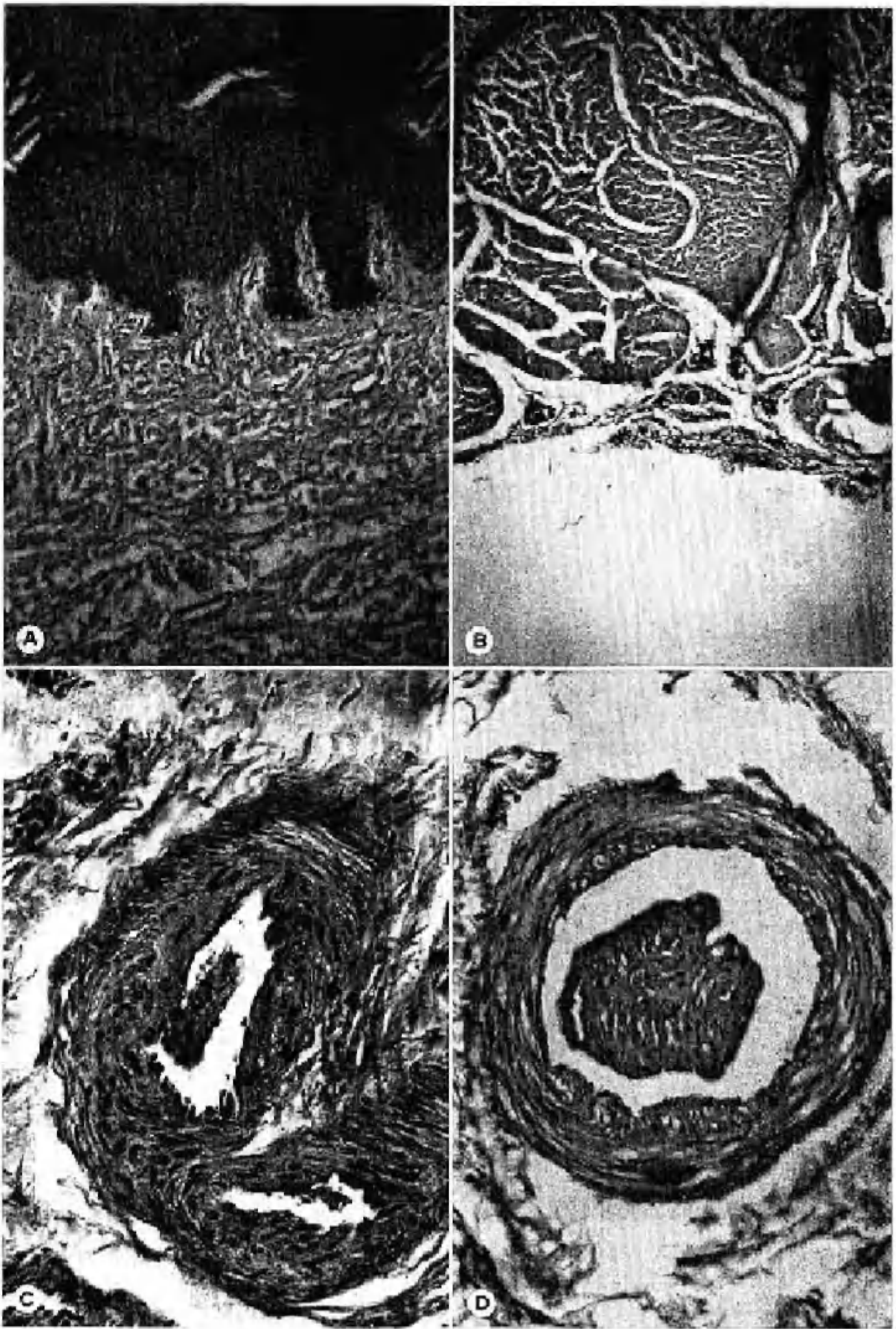


FIG. 14A-D.

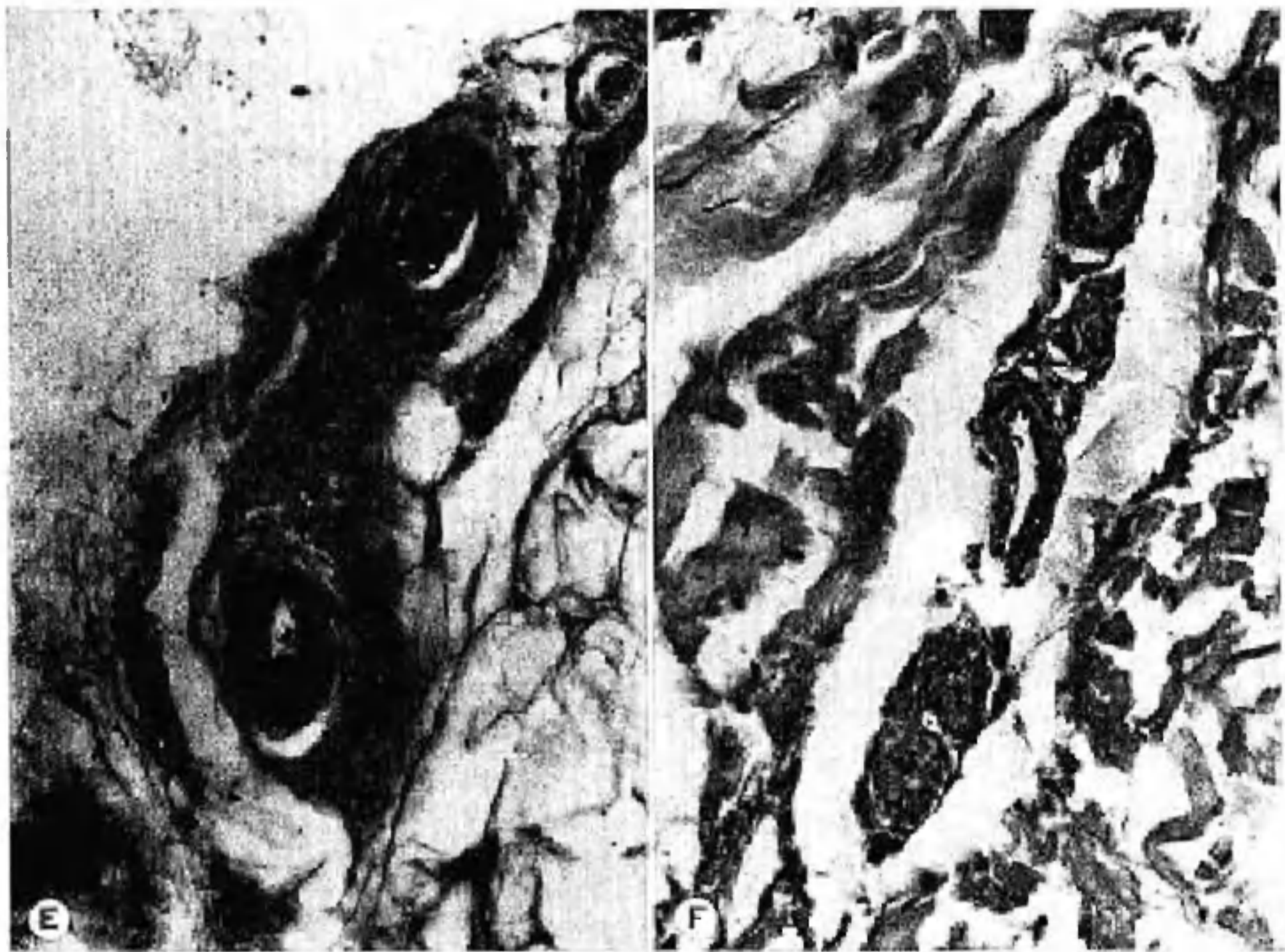


FIG. 14. *A*, numerous dilated capillaries. *B*, thrombosis of a small artery between the fibrous tissue and the sheath. *C*, recent thrombosis. *D*, thrombosis. *E*, patent lumen and thrombosis. *F*, several sections of open lumen and thrombosis.

progress of the disease and are replaced by dense, mature fibrous tissue filled with collagen fibers. There is no relation between the degree of maturity and the degree of contracture. Some collagen fibers do not pass through the nodule. (2) Nonspecific lymphocytic infiltration and free hemosiderin deposits appear in the early progressing fibrous tissue (fig. 11). (3) Probable perivascular origin (fig. 11). (4) Edema of the Paccinian corpuscles (fig. 11). (5) Skin is thin, corium is normal, but with hyperkeratosis. (6) Sweat glands are normal, except for slight changes in marked skin atrophy (fig. 12). (7) Elastic fibers are normal (fig. 13).

We have confirmed these observations, but wish to add: (1) Hypertrophy affects not only the longitudinal, but also the transverse fibers. (2) Increase in number and lumen of the subpapillary capillaries, with loss of the subdermal network (fig. 14.A). (3) Small arteries are normal at the sheath. As the vessels cross the palmar fascia, however, some are obstructed by embolism. These vessels progress toward the surface with diminished lumen due to hypertrophy of the wall, hyalinosis or sclerosis (figs. 14-15). (4) These vessels have been surrounded by lymphocytic infiltration, at times close to Paccinian corpuscles and enmeshed in nerves (fig. 16).

Seventy-four specimens were examined. When the search was complete, 76 per cent were positive for vascular disease.

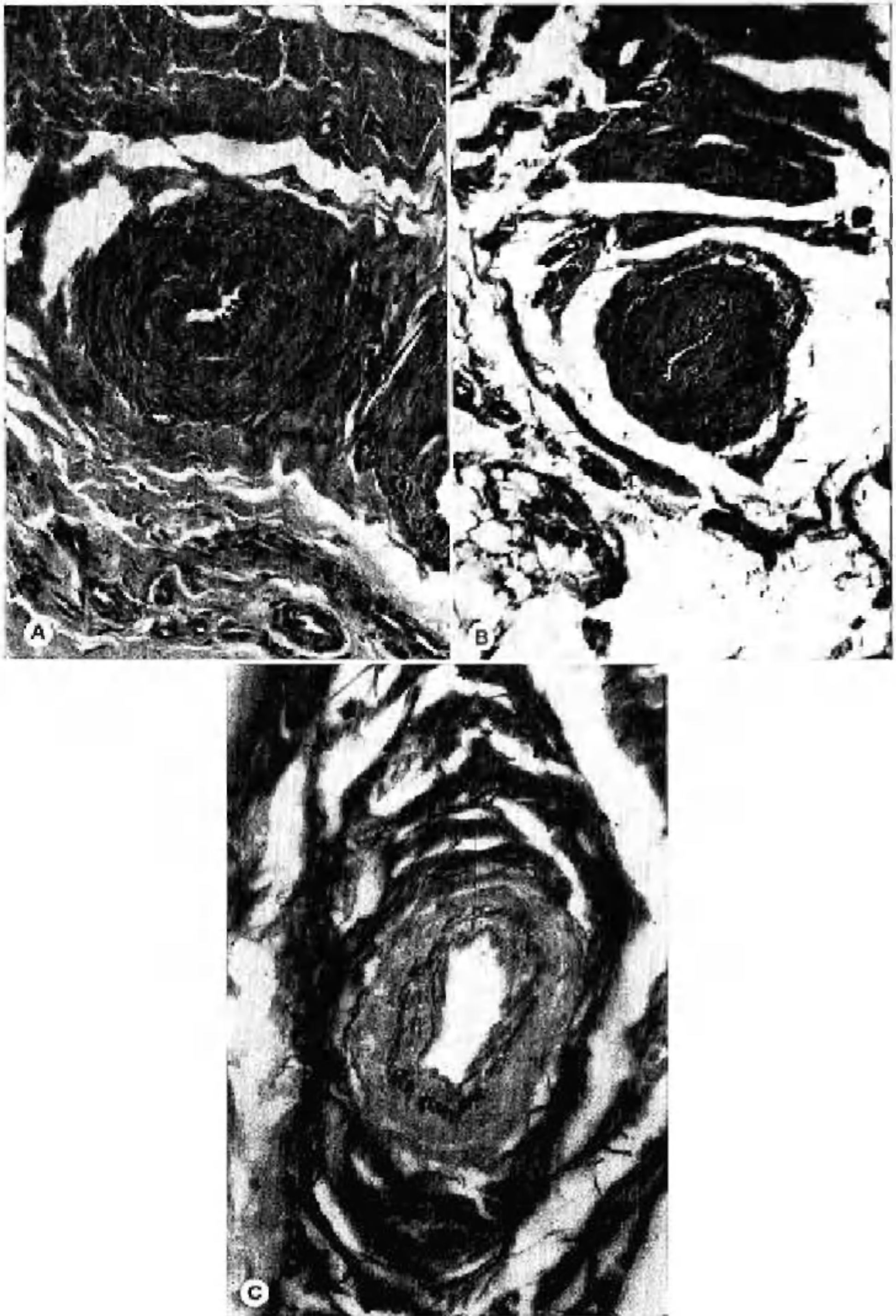


FIG. 15A-C.

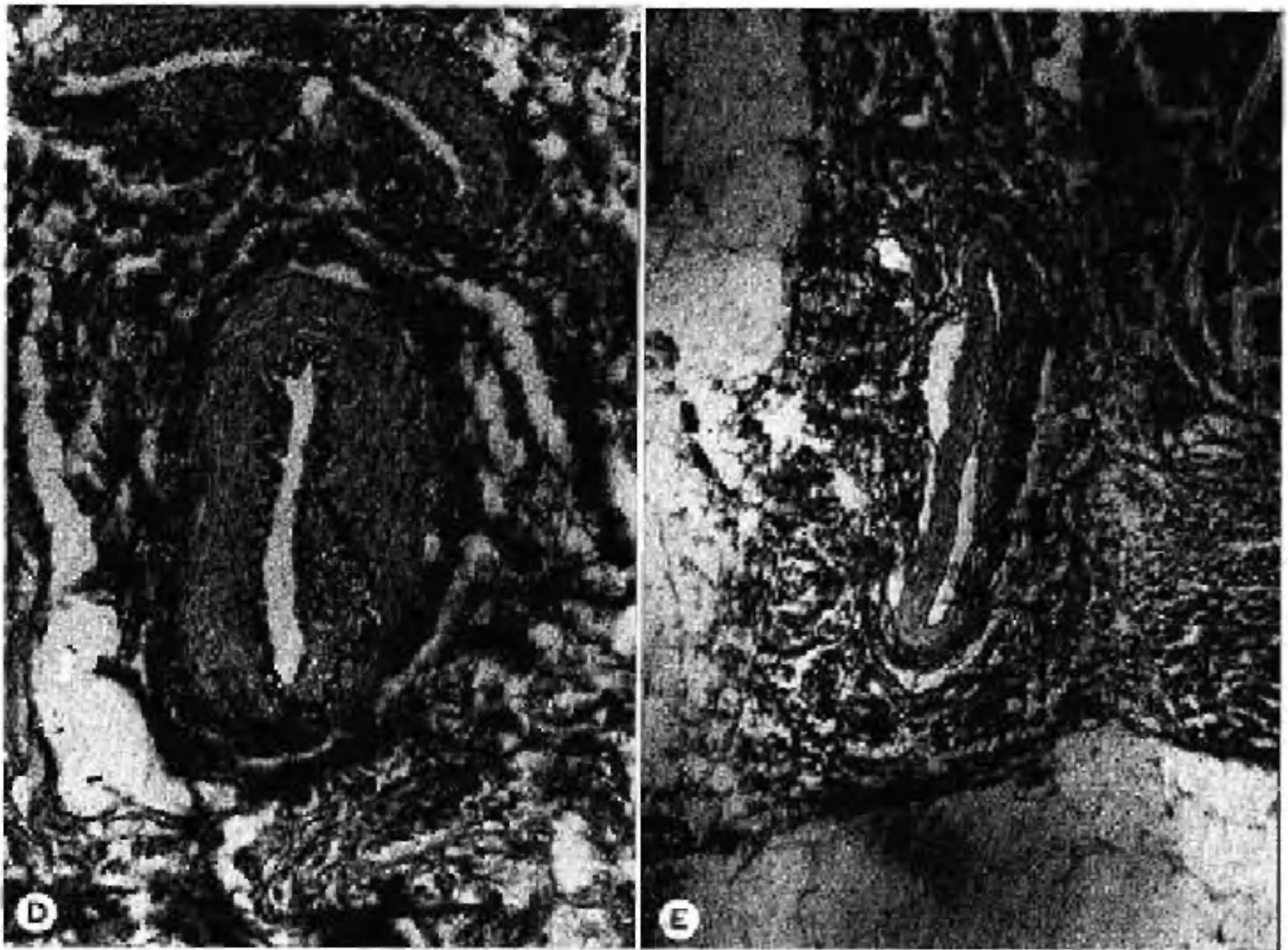


FIG. 15. *A*, hypertrophy of the arteriolar wall. *B*, hypertrophy of the wall. *C*, hyalinosis of the wall. *D* and *E*, sclerosis.

PATHOGENESIS

These findings tend to form a theory and we now conceive pathogenesis as follows: There is an *anatomical predisposition*, which produces a sluggish circulation in the ulnar artery, especially where the distal flexion crease crosses the ring finger ray. In these individuals, the *precipitating* factor is a vasoconstriction in the trophic region of the ulnar nerve. The stellate ganglion receives stimuli from the heart, mediastinum and central nervous system and projects them through the stellobrachial fibers to the lowest trunk of the plexus, *i.e.*, the ulnar. This trunk is liable to suffer the influence of pressure and irritation while passing through the scaleniform tunnel. The trophic fibers follow the course of the ulnar nerve and produce a vasoconstriction in the "locus minoris resistentia," that is to say, the predisposed palm (fig. 17). This vasoconstriction, plus the slow circulation, effects some vessel that perforates the superficial palmar fascia and causes the *minimal initial lesion*: a small artery thrombosis (fig. 18). There is perivascular edema and infiltration that in a rigid fibrous canal (palmar fascia) immediately produces the syndrome of strangulation and forms the *primitive nodule*. There is compression of the trophic nerve fiber up to death and circulation is interrupted. This is subclinical (fig. 19). With the initial infiltration, a vicious circle begins: the edema can

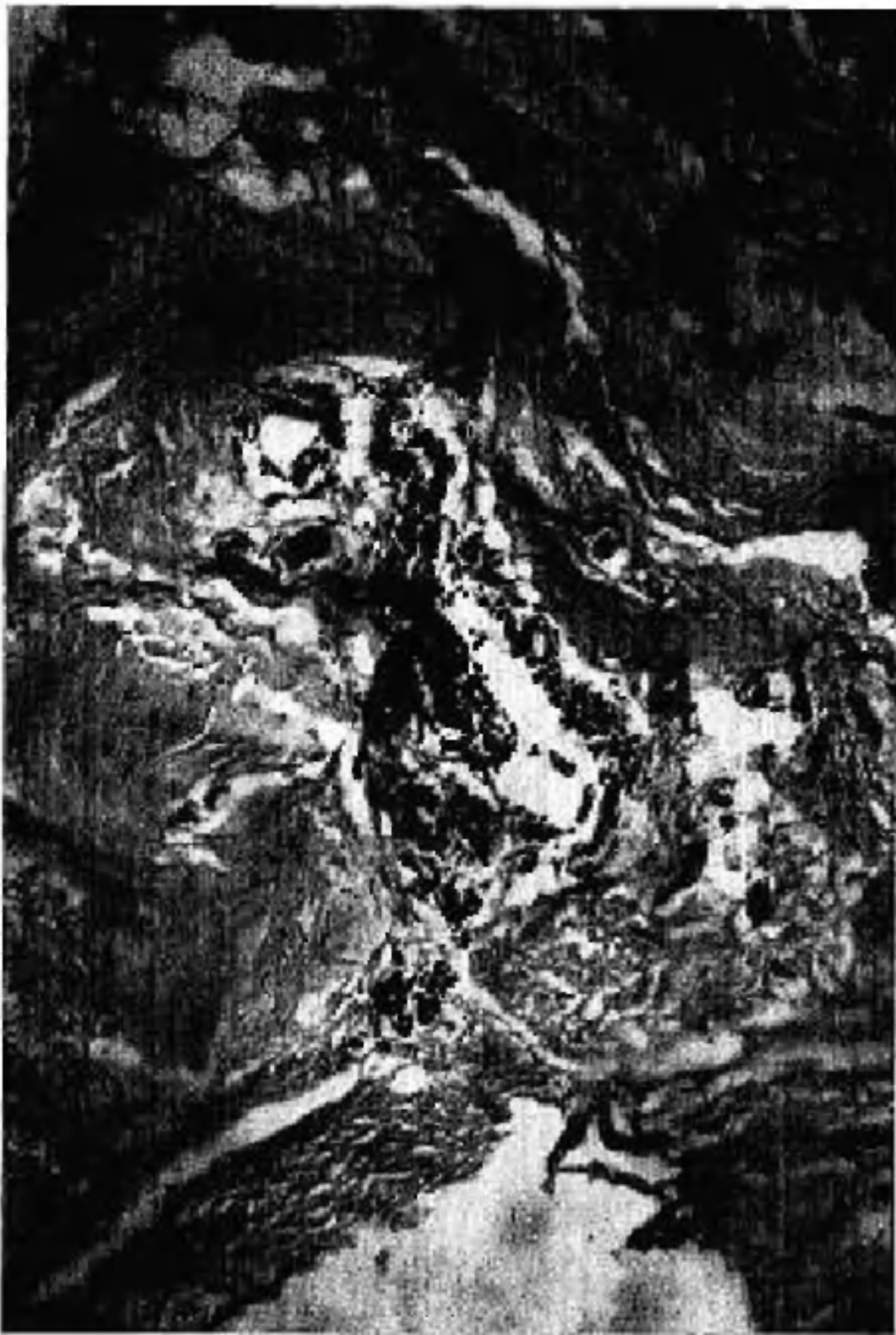


FIG. 16. Vessels surrounded by lymphocytic infiltration and enmeshed in nerves

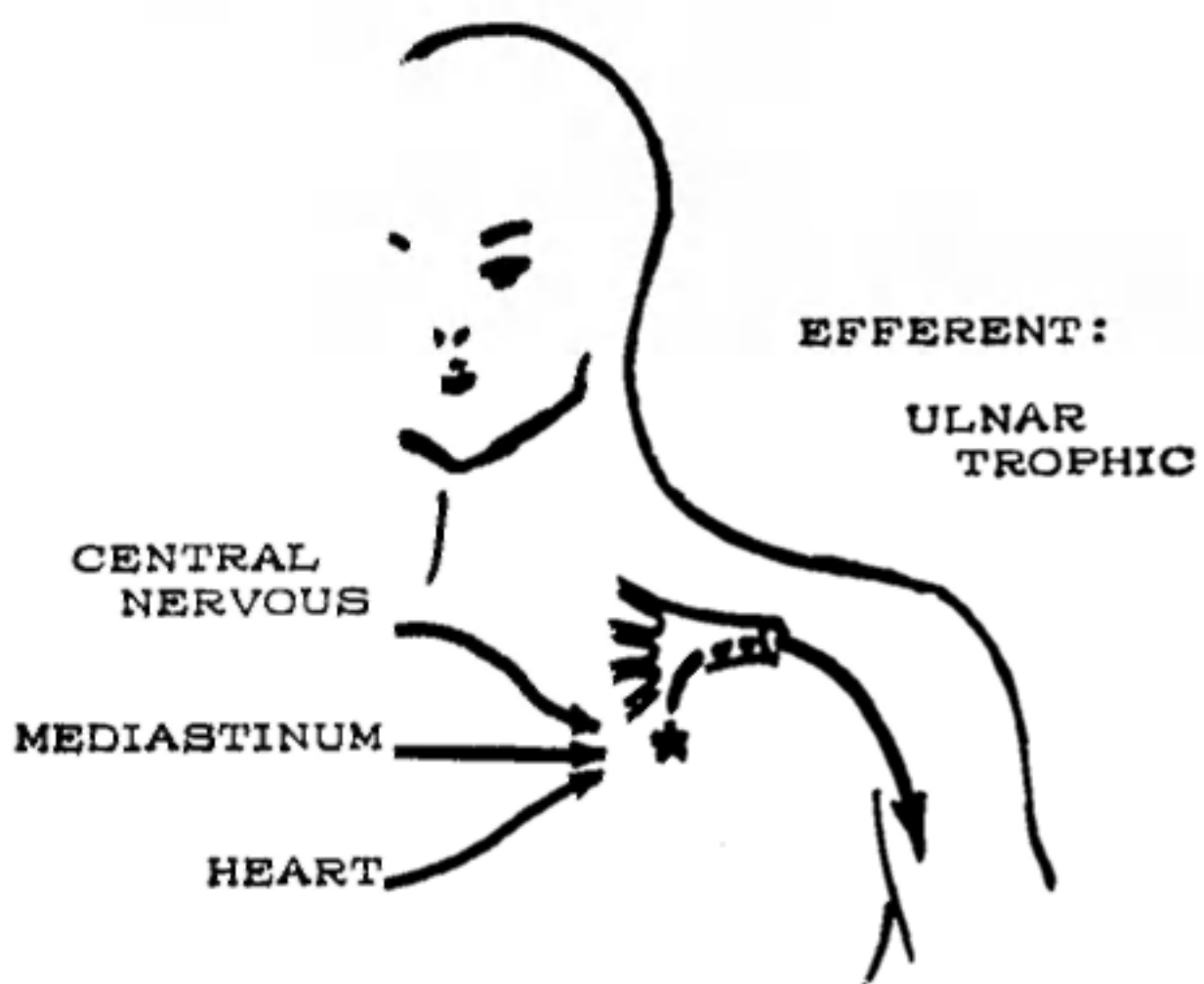


FIG. 17. The course of trophic fibers producing vasoconstriction in the palm

affect other arterioles and gives rise to more regions of infiltration. This dissects the fibrous tissue along its planes of cleavage, first in the layers of the superficial palmar fascia and then in the septa that extend to bone and skin, repeating the same process over again. But the edema that breads through to soft tissue is not compressed and enters rapidly into resolution without sequel. The affected septa go fixing skin and fat. Altogether, this stage may be grossly observed as a *nodule in progress* (fig. 20).

The edema subsides, but on being blocked in the rigid and inextensible fibrous tube it is invaded and replaced by young and immature connective tissue of richly cellular fibroblasts. Then collagen fibers develop in keeping with the plastic law, according to the stress and strain to which this tissue is submitted, and the nodule prolongs its fibers distally and proximally in the direc-

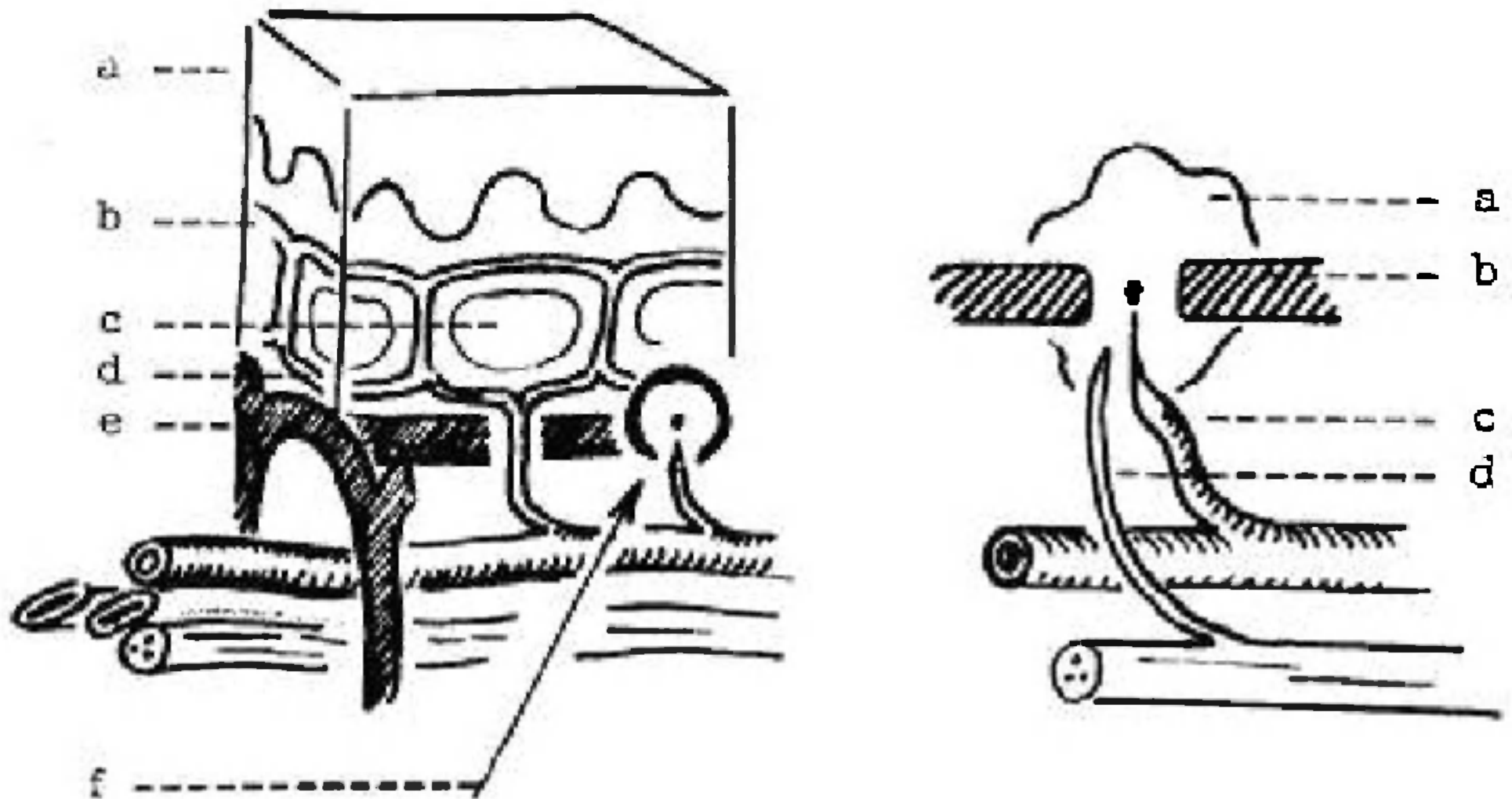


FIG. 18 (left). A small artery thrombosis: *a*, skin; *b*, subpapillary network; *c*, fat; *d*, subdermal network; *e*, fascia; and *f*, thrombosis.

FIG. 19 (right). The primitive nodule: *a*, infiltration; *b*, fascia; *c*, arteriole; and *d*, trophic nerve fiber.

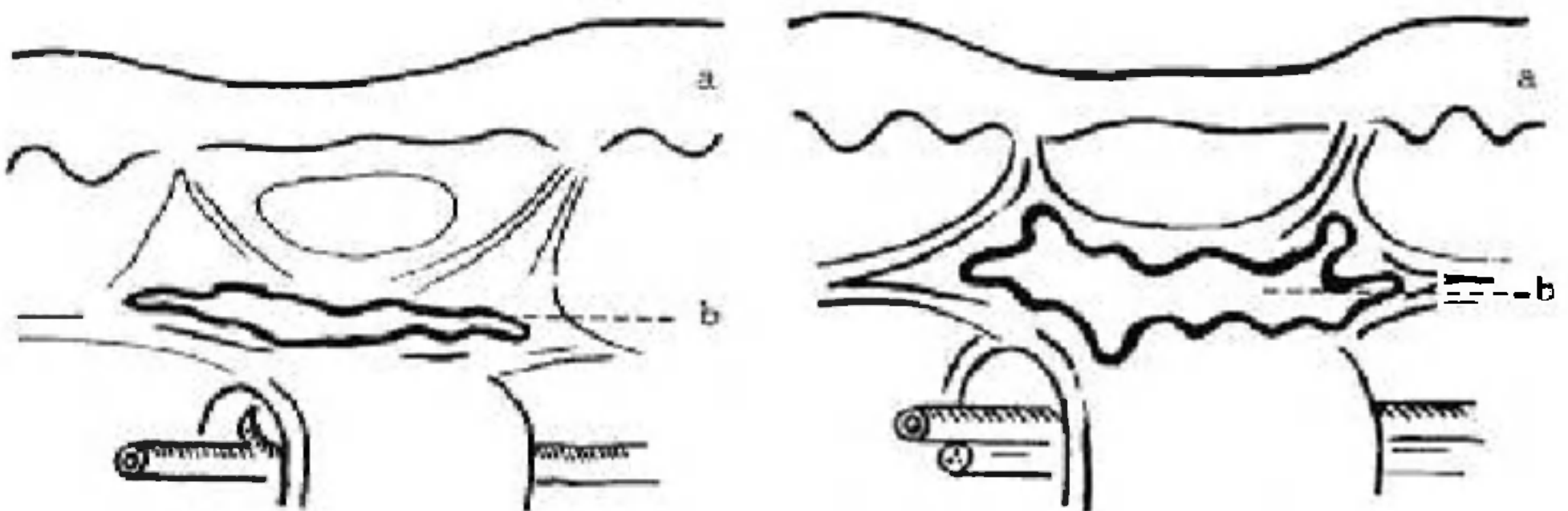


FIG. 20 (left). A nodule in progress: *a*, skin; and *b*, infiltration of fascia

FIG. 21 (right). A nodule in progress with a band: *a*, skin; and *b*, infiltration dissecting along the fascia.

tion of flexion and extension of the fingers. Clinically, this is a *nodule in progress with band* (fig. 21).

Finally, the young connective tissue becomes mature, retractile and no longer progresses. Nodules and infiltration are slowly reabsorbed. This is the *residual band*. During the process the vessels that cross the palmar fascia have become functionally severed. This is a positive delay, with development of the subpapillary vascular network in compensation. The trophic nerves are also cut and the loss of supply to the skin will produce atrophy of the superficial structures (fig. 22).

In the predisposed region, however, nodules can reappear and the process is repeated over again and the new fibrous tissue becomes fused with the old.

This theory can explain: (1) why the contracture appears only in the palm and the sole, with the characteristic distribution, for only here can the vicious circle take place; (2) hereditary traits, and symmetry, due to familial and symmetrical vascular predisposing conditions; (3) age and sex frequency, because the man between 40 and 50 years is most subject to neurovascular stress; (4) the chronic course with acute "poussés," recurrence and extension also depend on neurovascular disturbance and new foci production, depending on reinnervation, vasoconstriction, and thrombosis; (5) acute contractures, associated with Raynaud's disease and cardiac infarct, have a common precipitating origin in the stellate ganglion; (6) the spontaneous improvement in the rare cases of young patients because their youth can revascularize the region; (7) thenar and finger involvement, when local fascia acts as that of the palm to produce the vicious circle; (8) direction of the bands, in keeping with strain and stress of finger flexion-extension and transverse in the webs from intrinsic tension; (9) pain and tenderness, when the trophic nerve is suffering; (10) atrophy and loss of skin sweat, due to trophic nerve section; (11) why the subpapillary vascular network is developed by delay, permitting the extraordinary viability of the finest flaps and the excellent potential of second intention healing; (12) edema of the Paccinian bodies, due to infiltration coursing along the nerve sheath and collecting within the perineuron of the

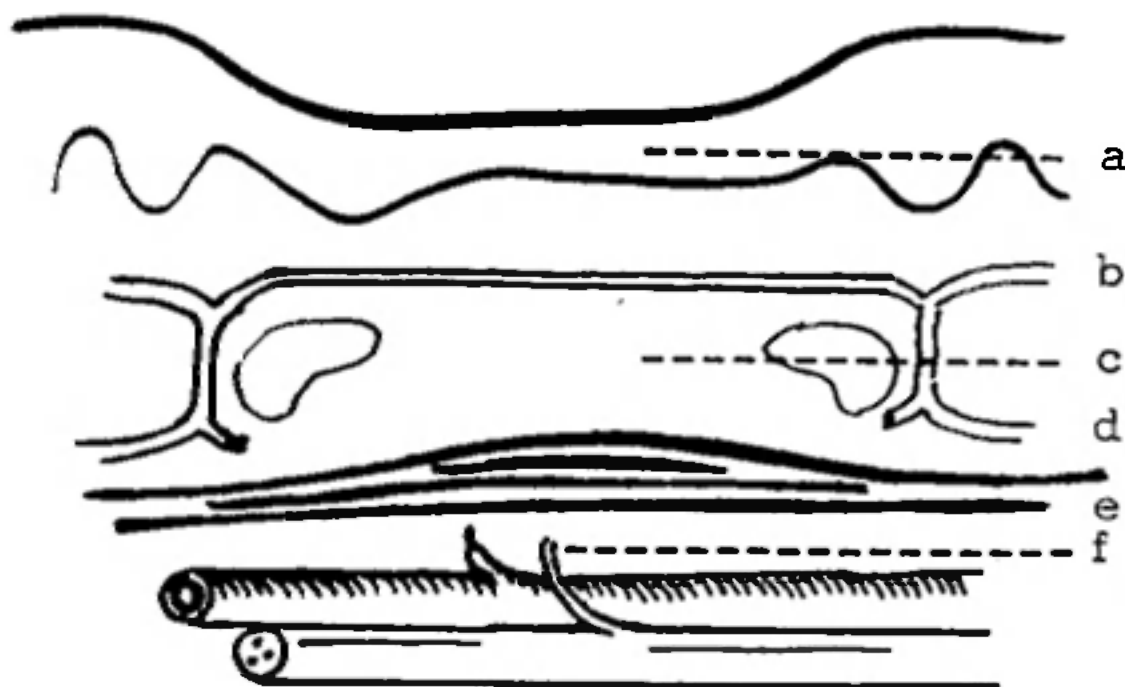


FIG. 22. The residual band: *a*, skin; *b*, hypertrophy of the subpapillary network; *c*, atrophy of fat; *d*, interruption of subdermal network; *e*, fascia; and *f*, physiologic amputation of both arteriole and nerve.

corpuseles; (13) why tendon, bundle and lumbrical sheaths and the pulley are healthy, because their circulation is independent; (14) why keloids are so rare, because these two "fibroplastic" conditions are histologically different and when both appear in the same individual the clinical characteristics and progress are entirely independent; (15) the appearance of perivascular infiltration and hemosiderin deposits, as complications of thrombosis; (16) the multifocal origin; (17) why sympathetic block and chain removal are useful for recanalizing the precapillary network and also for improving the associated ulnar conditions; (18) where and why fasciectomy should be performed; (19) the debated legal position, studied so far only with statistics. It can be defined as follows: "these individuals are predisposed to complication and when this produces a sequel (contracture) progress is speeded by repeated microtrauma (manual labor)."

SURGERY

The second point in Dupuytren's contracture is the lack of surgical statistical experience. The largest published statistics are: Luck, 206 hands; McIndoe and Beare, 200 hands; and Hueston, 166 fasciectomies. These figures are small when compared with other spheres of surgery and not enough to allow statistical conclusions. It is curious that these three largest series favor different treatments (fasciotomy, total and limited fasciectomy respectively).

Skin

Approaches through the skin have been tabled by Skoog³⁰⁸ and by Webster.³⁵³ Recent contributions should be added, as the finger "fillet" mentioned by Bunnell³⁶ and redescribed by Conway⁵⁰ and a vascular island flap taken from the lateral aspect of the finger and brought into the palm, by Hector Ardao.¹⁴ In direct access for limited excision, the staggered line has been well revised by Hueston¹⁴²⁻¹⁴⁵ and others. We have added yet another to the list, which associated with a Z-plasty at the palmar-digital crease after Iselin,¹⁵⁰ has been performed in 128 operations (fig. 23). This approach has the advantage of easy visualization of the ulnar artery and nerve in the palm and allows excellent access to the point of maximum nerve deviation (palmar-digital crease), which is the trickiest place of dissection.

Transverse incisions have been criticised because they involve dissecting under a bridge. This is a question of technical ability and the individual case. It is permissible as long as surgery is absolutely accurate and performed always under direct vision.

No incision for the interdigital web bands (natatory ligaments) has been mentioned in the literature. These, and especially the first web, can be well approached through an ample Z-plasty to allow radical excision of the bands below.

We feel that the plastic surgeon should be competent enough to treat the skin adequately and to balance it. Choice of approach should be eclectic and to

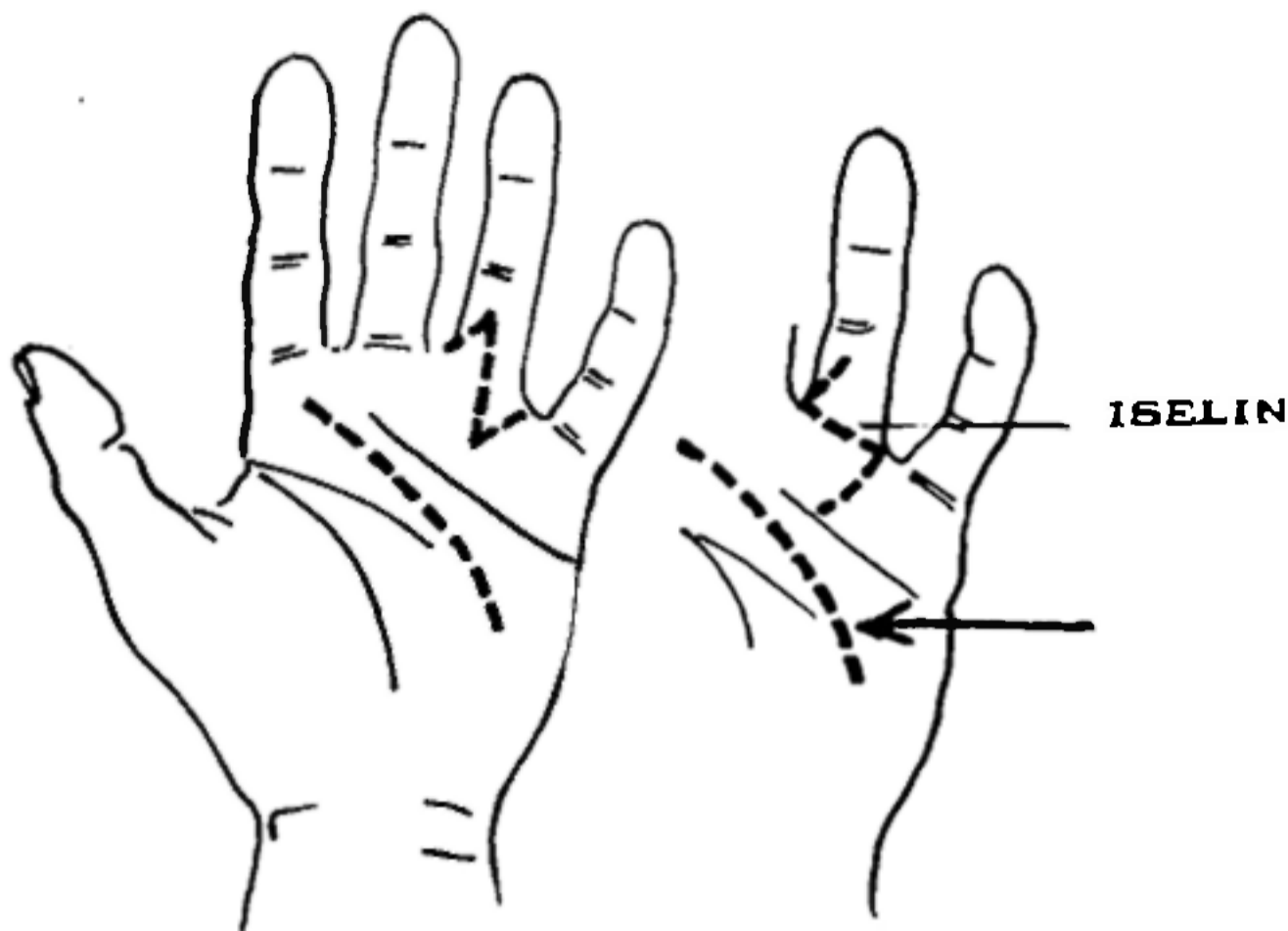


FIG. 23. Z-plasty at the palmar-digital crease after Iselin

suit the case. Incision principles must be rigorously kept to fall into the normal creases of the palm and the neutral lines of the fingers.

Fascia

Nodulectomy is unnecessary. Surgery is indicated for contracture. Excision of the band only, and fasciotomy, do not treat the pathology. Inadequate surgery can trigger progress. In blind fasciotomy there is always danger of severing a displaced nerve. These methods should be reserved only for the very occasional poor risk patient, where local anesthesia is mandatory to obtain transitory relief. In this category, it is debatable whether the operation should be performed at all. Severing the band prior to excision is pointless and only adds traumatic inflammation to the surgical site.

"Total," "complete" or "radical" fasciectomy consists of removing the superficial palmar fascia and the septa to the bone. "Limited" fasciectomy is described as excision of the band with some healthy tissue around it and septa in this region. If these two procedures are analysed more carefully, however, definition is not so clear. Where exactly do they begin and end? The fascias of the hand are so extensive and fused that radical removal can never be "total" or "complete." The superficial fascia stretches from the first to fifth metacarpal. Should all be sacrificed in the "radical" procedure? If the septa adhere not only to bone but other tissues, what exactly should be removed and what of the fingers in the radical criterium? If we are more conservative, where exactly do we stop in limited fasciectomy? These questions must be answered.

Our surgical series includes 242 hands. They have been submitted to the following procedures:

Radical:	126
Limited:	60
Sympathectomy:	8 (3 with radical fasciectomy)
Ulnar block:	51
	—
Total	242

Over-all early results were better in limited fasciectomy, but late in radical excision. This was due to more frequent recurrence or extension or both in the first category. In the last 51 cases, however, we have changed our attitude entirely. All diseased tissue has been removed, but no more. Extent of excision has been based on the ulnar nerve test. Limit of excision has been equal to the boundary of the test. In practice this is about 1 cm. outside the grossly thickened fascia, but on microscopic examination all tissues excised were found to be diseased. Control slides taken outside this limit were normal. The amount removed varied in every case. It is important to note that excision included adjacent hypothenar fascia.

In contrast to all authors, we have never found the disease to invade the sheaths or pulley, there is a definite plane of cleavage and these structures are microscopically healthy. Septa were incised at bone level. Several authors have stated that marked flexion of the little finger is difficult to correct. We have observed that here the septa adhere grossly to the capsule and deep fascia and we have obtained good results by peeling the capsule clean and radically removing the deep fascia that has become involved, even around the interossei and abductor digiti minimi tendons.

As many authors have noted, collateral nerves were frequently displaced in the distal palm and had to be carefully dissected out under direct vision. In the finger, the bands were superficial to the neurovascular bundle and after retracting the skin flaps it was easier to incise the fibrous tissue down the midline of the finger to the sheath and separate the two fibrous borders to expose the bundles below. As these bundles may also be deviated in the finger, dissection must proceed carefully and all diseased tissue removed. Although the nerves should be completely freed of enveloping fibrous tissue, they should not be peeled clean and some vascular supply preserved. A "peeled" nerve will lose its function for an indefinite period. One collateral artery can be sacrificed without hesitation, but loss of blood supply from both volar digital arteries should be avoided. The web bands should not be removed in block, but cut straight across and both halves taken out independently. This will prevent many a damaged bundle.

After removing the fascia, we reached the all-important point: hemo and lymphostasis. *Control of bleeding must be absolute.* If it had taken 20 min. to remove the fascia, 1 hr. was spent on obtaining hemostasis. After releasing the tourniquet and initial compression, bleeding was patiently and meticulously controlled with the *finest point of the electrocautery*, vessel by vessel. Ligatures have been avoided. Every lodge and crevice should be perfectly dry. Normally, lymphatics collapse easily with compression, but in the fibrous septa they remain gaping open. So each *septum stump was lightly burnt* along its entire length. This ensured closure of the multiple open lymphatics which travel through the septa.

In spite of this care, it was necessary to drain for 48 hr. A small drain, through a stab wound at a distance from the incision, was adequate. Good sites for the stab were the transverse palmar-digital and the longitudinal hypothenar-thenar creases.

Bandaging must provide uniform, delicate and constant pressure over the operated site. This was best achieved by a layer of cotton-wool on the skin and a molded rubber sponge over it to keep even pressure on the concavity of the palm. Attention was stressed on the palm because the fingers usually heal well with less care and may even be left outside the bandage. The bandaging should tend to straighten the fingers very gently. Passive stretching and plaster casts are useless and defeat their own purpose. Patients were kept with their hands rigorously raised up high at all times for 14 days. Two weeks postoperatively bandages and stitches were removed. A little rubber sponge was molded to continue gentle pressure on the concavity of the palm for another week. With these measures the palm should be slightly more depressed than the normal one. This sign of *deep concavity of the palm* is imperative throughout all the postoperative period. Its absence is an indication for reopening the wound and evacuating the hematoma. Active movement started as from the 15th day, very gently at first, but progressing rapidly.

The outstanding late postoperative complications were hard edema and stiffness of the joints. In our experience, the most important aid to healing has been a good psycho-hand relationship. This is a rather immeasurable factor. It is the confidence of the patient to move his hand actively (in spite of swelling, stiffness and pain) and his determination and perseverance to continue doing so. We feel that there is a direct psychological influence on wound healing and progress, rather than merely the advantage of active movement. The most useful treatment has been frequent and long term control by the surgeon, with all the psychotherapeutic measures at his disposal (reeducation, suggestion, hypnosis). Ultrasonic wave, bubble vibrating baths, corticoid medication and stellate blocking have been the most useful local aids in the different types of wound progress. x-ray therapy (600 to 700r) has controlled most of the tiny painful skin neuromata, which appear about a month postoperatively.

Women progressed better than men. The padded, calloused and potentially arthrotic hand of the elderly laborer was usually the worst case; the delicate, thin hand of the young woman the best. The degree of postoperative edema as related to physical constitution variants, as observed by Barclay,²¹ holds true, but is by no means absolute and this is applicable to all hand surgery and not only to Dupuytren's contracture.

However, occasional cases progressed poorly in spite of careful local surgery and aftercare, as has been stressed by Clarkson.⁴⁵ It is important to realise that the *contracture is the sequel to a neurovascular disease* and we are treating the sequel and not the "maladie." We suggest that cervicodorsal sympathectomy, from C4 to D2, be considered for severe cases (recurrence and/or extension), with or without further local surgery. There is no such thing as prophylactic fasciectomy. The misnomer, "recurrence," will depend on progress of the disease itself with new vascular channel formation, new trophic nerve pathways and further complication, rather than the type of surgery. Any type of surgery, as local trauma, can trigger a reflex.

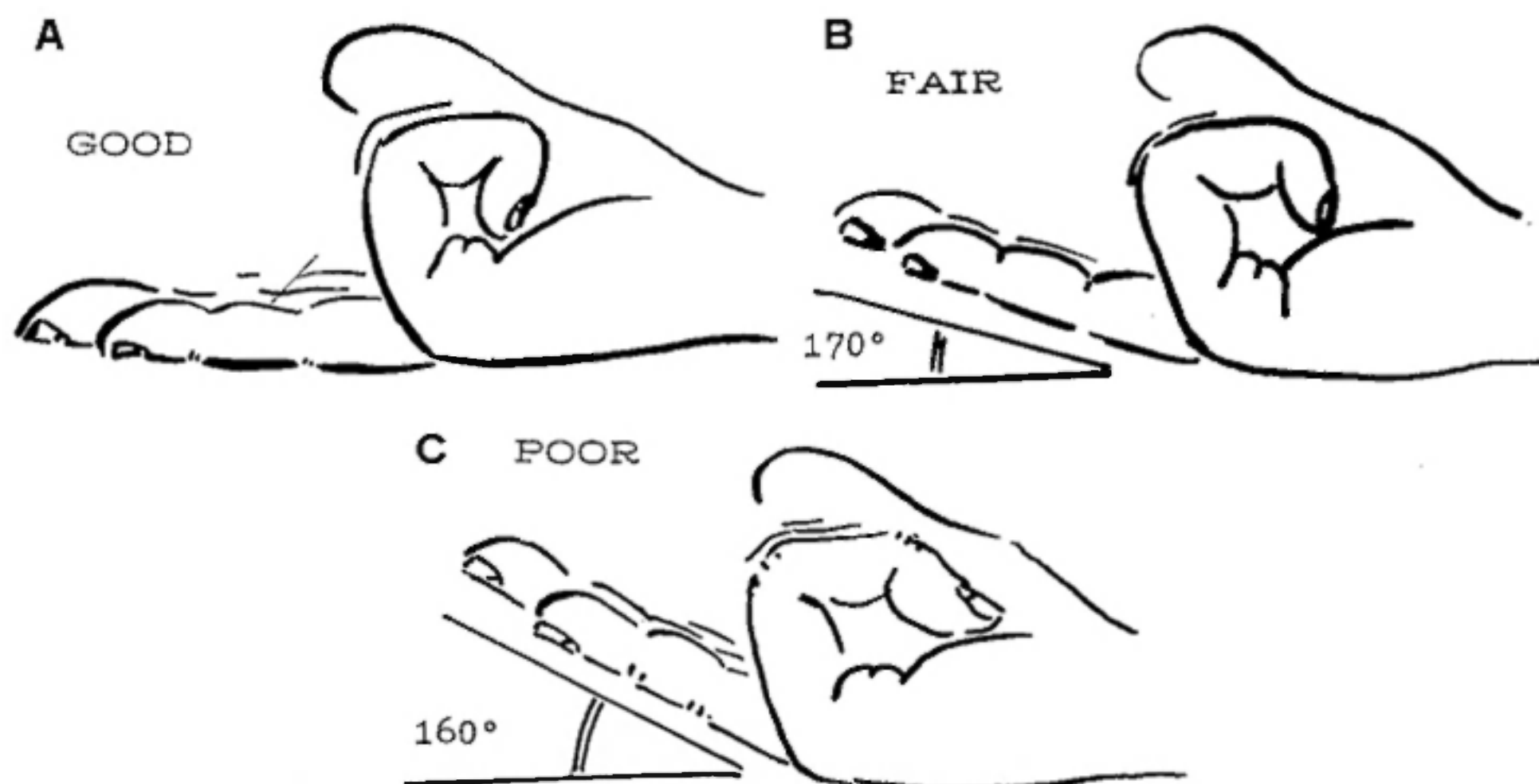


FIG. 24. A, B, and C, measurement of postoperative progress

The four group classification of McIndoe and Beare,²²⁹ and repeated by others with minor variations, can be useful for pigeonholing the preoperative condition, but not for progress. It is necessary to define a measurement for evaluating results. We insist that these should be established at 1 month for surgery. Progress from 30 days to 1 year will depend on the healing potential of the patient rather than surgery and later results should be recorded at 6 and 12 months. We have classified results in terms of total hand function, as follows: *Good* (fig. 24.A): full active movement, with nails flexing to the distal palmar crease and extending to 180°. No edema. Full use of hand. *Fair* (fig. 24.B): subtotal active movement, with nails spreading from midpalm to 170°. No edema. Full use of hand. *Poor* (fig. 24.C): fingertips extending from the heel of the palm to 160°. Slight edema. Hand not recovered, but can be used for all light duty. *Bad*: anything less or with complications.

Before and after these principles we had:

(%)	1 Month				6 Months			
	Good	Fair	Poor	Bad	(%)Good	Fair	Poor	Bad
Radical.....	13	19	31	37	38	22	18	22
Limited.....	32	30	16	22	42	14	14	30
Ulnar block, etc.....	38	32	18	12	54	26	12	8

These figures have a relative value because the severity of the cases varied, and progress of the disease was so erratic. There are too many factors in the make-up of this pathology to pin-point every patient. Also, this series is over 15 years and our technique has changed with time. However, the last group defined by ulnar block has been far superior to previous groups. A patient can now be advised that he has a 70 per cent chance of being fit for all duty in less than a month. As we have become more confident, six patients have had both hands

operated upon simultaneously and they have all been back at full work well before the scheduled time.

Two selected cases are shown to illustrate true average results at this stage in our work. They were both poor surgical candidates (cases 1 and 2).

SUMMARY

1. Three basic investigations have been performed. All have shown definite new findings in Dupuytren's contracture. They were: (a) circulation with arteriography and angiocinematography (40 hands); (b) trophic nerve supply with ulnar block (42 hands); (c) histopathology, with serial skin to sheath parallel sections (74 hands).

2. Eight decompressive scalenotomies (7 with sympathectomy, 1 with subclavian arteriectomy) have been carried out, and results reported. They are the only ones on record so far for the treatment of Dupuytren's contracture.

3. A theory is presented, which explains the pathology, answers the questions that have been a mystery so far and we now allow ourselves to call it a "disease."

4. Three physical signs are described: "atrophic skin triangle," "pale wave" and "palm concavity."

5. The largest surgical statistics published to date are presented, with the comparative statistics between the basic methods of treatment.

6. Technical details are described, which are particular for surgery of Dupuytren's contracture and not of other hand surgery. Two new incisions are proposed. Definition is established where and why the fascia should be removed, how this characteristic wound should be treated, and the best aftercare in our hands. This is a localized sequel, primarily involving the palmar fascia and septa and limited by the trophic ulnar nerve region. We believe surgical excision should include only and all the disease tissue, neither more nor less.

7. Results are classified and the improvement we have obtained after the application of the findings of our investigations is reported.

CONCLUSION

An initiative has been made to establish a working pathogenesis for the "maladie de Dupuytren," which has enabled us to obtain better results in the largest surgical series to be published so far by one team.

Acknowledgments. Merit is due to the members of units under my direction who have enthusiastically participated in this project. They are Drs. P. Pereyra, O. Guarino, G. Bosch, R. Fernandez Garay and A. M. Marín.

I am indebted to Prof. S. Di Rienzo, Dr. E. Olcese and Dr. F. Ploszaj for their assistance in solving many a radiologic problem and to Prof. J. Monserrat, Dr. A. Murray and very especially Dr. J. Monserrat, Jr. who have so generously helped, controlled and criticized our micropathologic findings.

...and to the patients themselves, who have collaborated in more ways than one.

*Corrientes 456
Buenos Aires, Argentina*

CASE REPORTS

Case 1. This 56-year-old sailor had his other hand operated upon 5 years ago for a symmetrical condition. He was 2½ months before returning to work. A shows the preoperative of the second hand. It was thick, padded, and calloused and with a three-finger involvement. The equivalent of a radical excision was performed, but with the surgical details mentioned

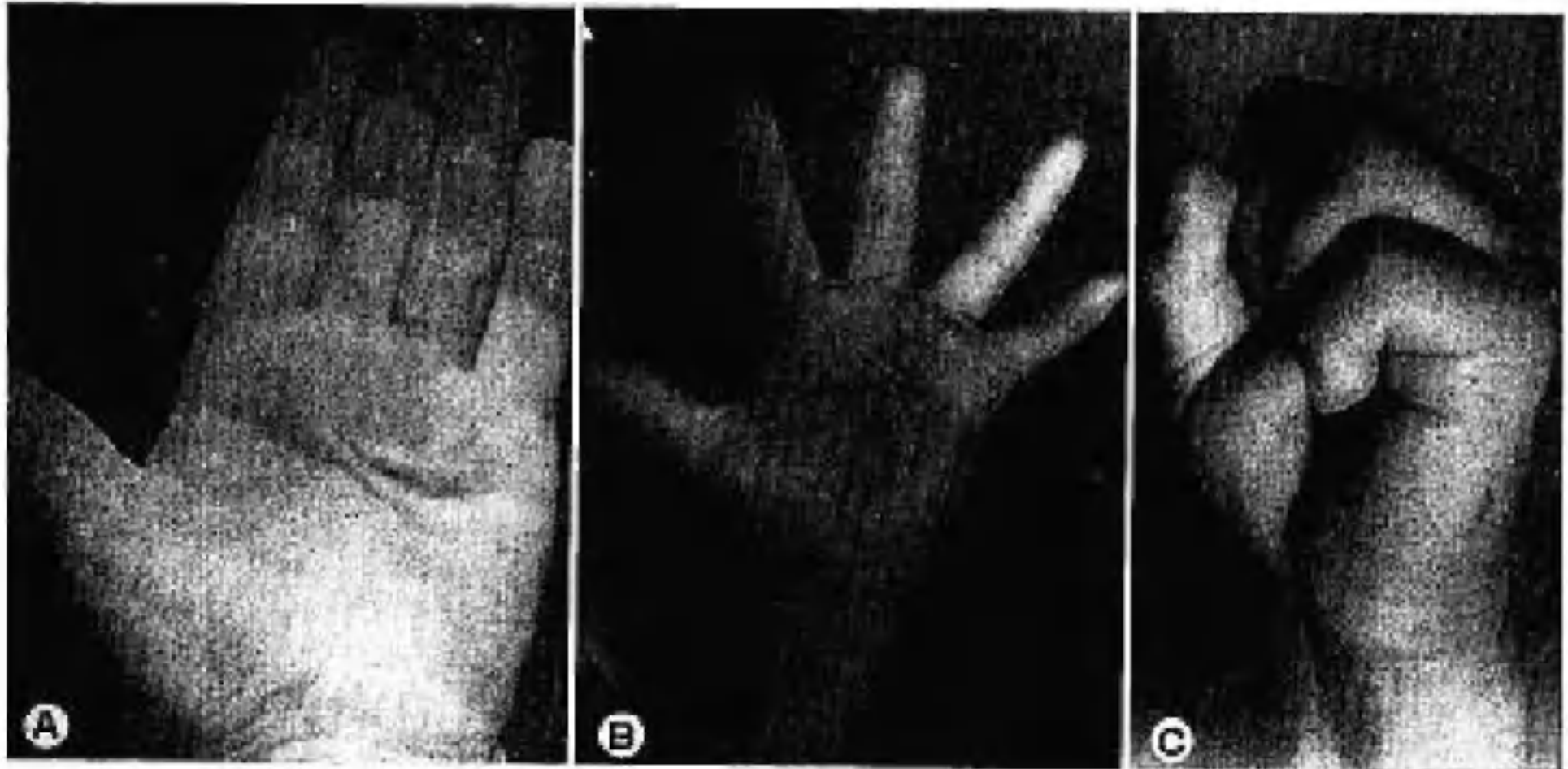


FIG. 1. Case 1

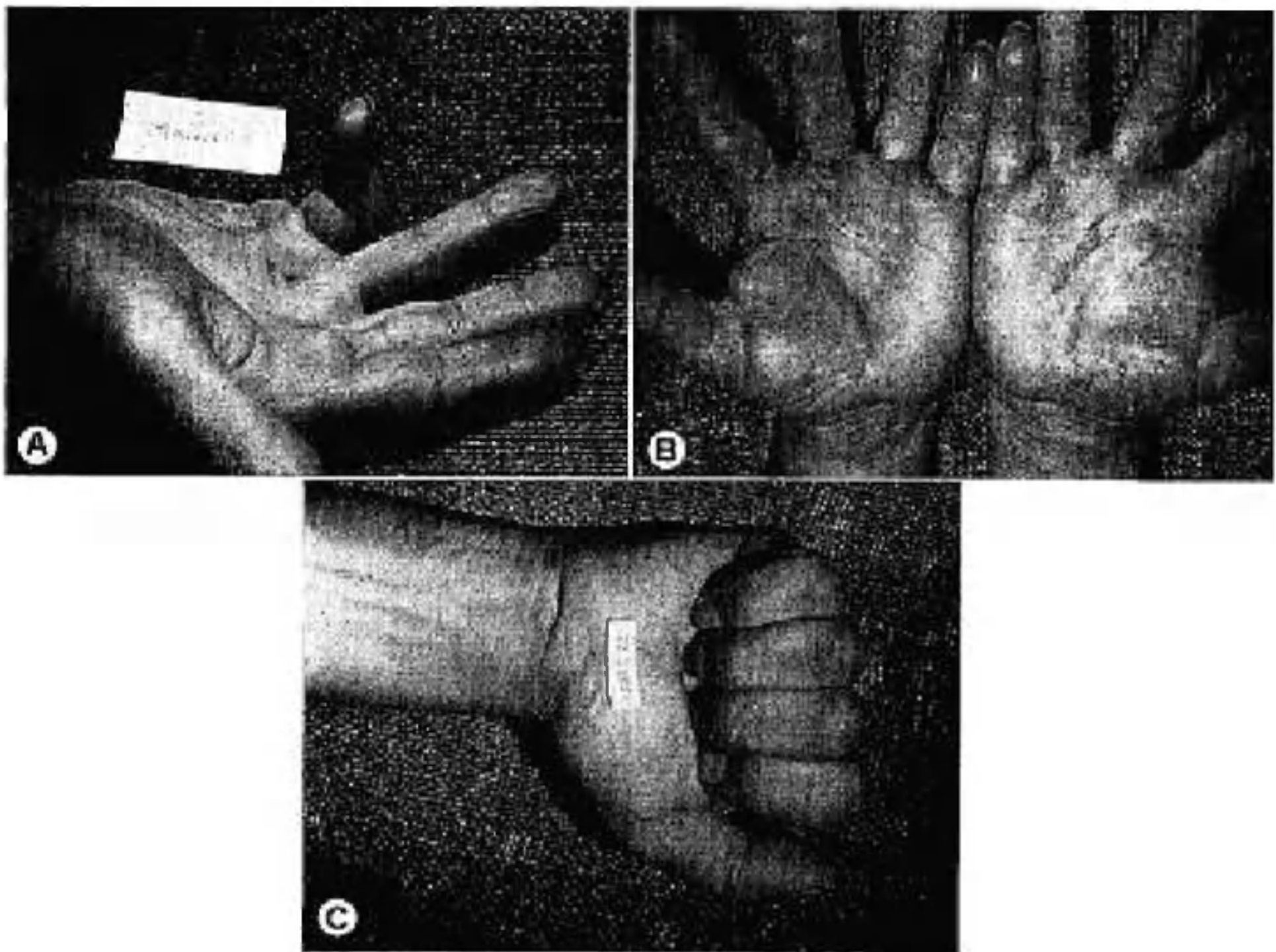


FIG. 2. Case 2

in the paper. *B* and *C* illustrate the result at 14 days postoperatively. At 16 days postoperatively he was doing full duty on deck.

Case 2. This 39-year-old epileptic had a bilateral involvement of both hands and they were operated upon simultaneously. He collaborated poorly in the postoperative and was afraid to use his hands. *A* shows the preoperative condition of the worst hand and the little finger retraction can be recognized as one of the difficult problems to correct. *B* and *C* illustrate the postoperative at 22 days and at 24 days postoperative he was typing 8 hr. a day at work.

REFERENCES

1. Abbé, R.: Dupuytren's finger contraction. Further remarks on the theory of its nervous origin. *Med. Rec.*, 33: 236, 1888.
2. Adams, H. D.: Dupuytren's contracture. *Lahey Clin. Bull.*, 2: 75, 1941.
3. Adams, H. D.: Dupuytren's contracture. *Surg. Clin. N. Am.*, 22: 899, 1942.
4. Adams, W.: Contracture of the fingers (Dupuytren's contracture) and its successful treatment by subcutaneous divisions of the palmar fascia and immediate extension. *Brit. Med. J.*: 928, 1878.
5. Adams, W.: *Observations on Contraction of the Fingers (Dupuytren's Contracture) and Its Successful Treatment by Subcutaneous Divisions of the Palmar Fascia and Immediate Extension; Also on the Obliteration of Depressed Cicatrices after Glandular Abscesses; or Exfoliation of Bone by a Subcutaneous Operation.* J. & A. Churchill, London, 1879.
6. Adams, W.: On congenital contraction of the fingers and its association with hammer toes: its pathology and treatment. *Lancet*, 11: 1272, 1890.
7. Adams, W.: Further observation on the treatment of Dupuytren's finger contraction. *Tr. M. Soc. Lond.*, 13: 336, 1889-90. Abstract, *Brit. M. J.*, 1: 722, 1890.
8. Adams, W.: On congenital contraction of the fingers and its association with hammer toe: its pathology and treatment. *Lancet*, 11: 165, 1891.
9. Adams, W., and Noble-Smith.: Cited by S. A. Wyeth, 1908.
10. Abraham, S.: Virus Isolierungsversuche bei Dupuytrenkranken vorläufige Mitteilung. *Ztschr. ges. inn. Med.*, 12 (14): 716, 1957.
11. Amat, C.: De la maladie de Dupuytren. *Gaz. méd. Paris*, 73, 111: 25, 1876.
12. Ardao, A. R.: Tratamiento de la contractura palmar, con referencia especial a la aponeurectomía palmar total. *An. Fac. med. Montevideo*, 39: 133, 1954.
13. Ardao, H. A., and Knaibl, P.: Tratamiento de la retracción palmar de Dupuytren. *Bol. Soc. Cir. Uruguay*, 18 (2): 224, 1947.
14. Ardao, H. A.: Personal communication.
15. Anderson, W.: *The Deformities of the Fingers and Toes.* J. & A. Churchill, London, 1897.
16. Asboe, H. G.: Fibroplasia and brain lesions. *Acta dermat.-venereol.*, 41: 224, 1961.
17. Ashley, F. L.: Two stage operation for Dupuytren's contracture. *Plast. & Reconstruct. Surg.*, 12: 79, 1953.
18. Askey, J. M.: Dupuytren's contracture. *Am. Health J.*, 22: 1, 1941.
19. Ayre, W. B.: Report of 64 cases among Veteran's Guard of Canada of Dupuytren's contracture. *J. Canad. M. Service*, 3: 57, 1945. Also *Canad. M. A. J.*, 57: 158, 1946.
20. Baarheim: Cited by Webster, 1905.
21. Barclay, T. L.: Edema following operation for Dupuytren's Contracture. *Plast. & Reconstruct. Surg.*, 23 (4): 348, 1959.
22. Baxter, H., Schiller, C., Johnson, L., Whiteside, J., and Randall, R.: Cortisone therapy in Dupuytren's Contracture. *Plast. & Reconstruct. Surg.*, 9: 261, 1952.
23. Bier, Braun, and Kummell: *Chirurgische Operationslehre*, edited by von Johann Ambrosius Barth. Leipzig, 1933.
24. Black, K.: Dupuytren's Contracture. *Brit. M. J.*, 1: 326, 1915.
25. Blair, V. P.: The full-thickness graft. *Ann. Surg.*, 29: 298, 1924.
26. Blair, V. P.: Influence of mechanical pressure on wound healing. *Illinois M. J.*, 16: 249, 1924.
27. Blair, V. P., and Brown, J. B.: *Textbook of Surgery*, edited by Christopher Frederick. W. B. Saunders Co., Philadelphia and London, 1936.
28. Bohler, J.: Die Fingerknöchelposter, eine Sonderform der Dupuytren'schen Kontraktur. *Chirurg*, 28 (5): 218, 1957.
29. Boyes, J. H.: Dupuytren's Contracture; age at onset and relationship to handedness. *Am. J. Surg.*, 88: 147, 1954.
30. Brewer, G. E.: *Textbook of Surgery.* Lea Bros & Co., Philadelphia, 1956.
31. Briantsera, L. N.: Kroposu o razrezakh i pokazanicakh & Kozhnoiplastike pri operatsiiakh po porodu Diupytrenovskoi Kontraktury. *Khiringiia, Moskva*, 34 (2): 134, 1958.

32. Bruner, J. M.: The use of dorsal skin flap for coverage of palmar defects after aponeurectomy for Dupuytren's Contracture. *Plast. & Reconstruct. Surg.*, 4: 559, 1949.
33. Bryant, T. A.: *Manual for the Practice of Surgery*. London, 1870.
34. Buff, H. U.: Indikation, Gefahren und Technik der operativen Behandlung der Dupuytren'schen Kontraktur. *Ther. Umschau. Bern.*, 15 (8): 238, 1958.
35. Bunch, J. L.: Hereditary Dupuytren's Contracture. *Brit. J. Dermat.*, 25: 279, 1913.
36. Bunnell, S.: *Surgery of the Hand*. J. B. Lippincott Co., Philadelphia, 1956.
37. Busch: Cited by Webster, 1875.
38. Byford, W. H.: The pathogenesis of Dupuytren's contraction of the palmar fascia. *M. Rec.*, 100: 487, 1921.
39. Callander, C. L.: Dupuytren's Contracture. In *Surgical Anatomy*. W. E. Saunders Co., Philadelphia and London, 1941.
40. Candiollo, L.: Anatomía studies of configuration and structure of the palmar aponeurosis. *Ztschr. Anat.*, 119: 500, 1956.
41. Carreras, A.: Dupuytren's Contracture with positive Frei reaction: new cases. *Actas dermo-sif.*, 36: 388, 1945.
42. Celikoglu, S.: Palm contractures observed in diabetic subjects (Dupuytren's Contracture). *Turk. tip. cem. mec.*, 25: 266, 1959.
43. Chernavskii, V. A., and Pavlova, Z. N.: Dupuytren's Contracture of the hand and its surgical treatment. *Ortop. travm. protez.*, 23: 57, 1962.
44. Clarkson, P.: Discussion of Oldfield, M. C.: Dupuytren's contracture. *Proc. Roy. Soc. Med.*, 47: 361, 1954.
45. Clarkson, P.: The radical fasciectomy operation for Dupuytren's disease: a condemnation. *Brit. J. Plast. Surg.*, 3: 273, 1963.
46. Clarkson, P., and Pelly, A.: *The General and Plastic Surgery of the Hand*. Blackwell Scientific Publications, Oxford, 1962.
47. Coenen, H.: Die Dupuytren'sche Fingerkontraktur. *Ergebn. Chir. u. Orthrop.*, 10: 1170, 1918.
48. Coenen, H.: Zür Frage der Dupuytren'schen Fingerkontraktur nach Verletzung des Ellen-nerven. *Klin. Wchnschr.*, 4: 419, 1918.
49. Collis, E. L., and Eatock, R.: Dupuytren's Contracture. *Report of an Enquiry on Dupuytren's Contracture as a Disease of Occupation, with Special Reference to Its Occurrence among Minders of Lace Machines*. H. M. Stationery Office, Darling & Son. London, 1912.
50. Conway, H.: Dupuytren's contracture. *Am. J. Surg.*, 87: 101, 1954.
51. Conway, H., and Fleury, A. F.: Indications for skin grafting in the primary treatment of Dupuytren's Contracture. *Plast. and Reconstruct. Surg.*, 16: 264-275, 1955.
52. Conway, H., and Stark, R. B.: Arterial vascularization of the soft tissues of the palm. *J. Bone & Joint Surg.*, 36 (A): 670-671, 1954.
53. Conway, H., and Stark, R. B., and Cano, G. N.: Vascularización arterial de los colgajos. *Rev. Lat. Am.*, 1: 22, 1953.
54. Cordrey, L. J.: Management of Dupuytren's contracture. *Geriatrics*, 11: 440, 1956.
55. Cooper, A.: *A Treatise on Dislocations and Fractures of the Joints*. Longmans, Hurst, Rees, Dome & Browne, London, 1822.
56. Corletti, S. C.: Enfermedad de Dupuytren: a propósito de un caso raro en un adolescente. *Semana méd.*, 119: 1135, 1961.
57. Cunningham, D. J.: *Textbook of Anatomy*. W. Wood & Co., New York, 1923.
58. Davis, A. A.: The treatment of Dupuytren's contracture. A review of 31 cases, with an assessment of the comparative value of different methods of treatment. *Brit. J. Surg.*, 19: 539, 1932.
59. Davis, J. S.: The use of free grafts of whole thickness skin for the relief of contractures. *Surg., Gynec. & Obst.*, 25: 1, 1917.
60. Davis, J. S., and Finesilver, E. M.: Dupuytren's contracture, with a note on the incidence of the contractions in diabetes. *Arch. Surg.*, 24: 933, 1932.
61. De Dominicis, G.: Silicosis asociada con poliartritis crónica primaria y con enfermedad de Dupuytren: contribución clínica. *Minerva Med.*, 51: 1890, 1960.
62. Del Carril, M., and Perez, C.: Contractura de Dupuytren: etiología a propósito de un caso. *Rev. méd. Hosp. de la Plata*, 1: 21, 1944.
63. De Size, S., and Jurmand, S. H.: Dupuytren's contracture following herpes zoster, favourable effects of procaine hydrochloride infiltration of the stellate ganglion. *Rev. Theim.*, 14: 125, 1947.
64. De Size, S., and Jurmand, S. H.: Results of prolonged treatment with stellate ganglion infiltration for Dupuytren's contracture. *Rev. neurol.*, 78: 604, 1946.
65. Desplas, B., and Meillere, J.: Maladie de Dupuytren. *Bull. et mém. Soc. nat. chir.*, 58: 24, 1932.
66. Desplas, B., and Tostivint, R.: Etude à propos de 150 cas de maladie de Dupuytren. *Brem. Acad. Chir.*, 71: 373, 1945.

67. Demers, R., and Blais, J. A.: The familial and hereditary character of Dupuytren's contracture. *Union méd. Canada*, 89: 1238, 1960.
68. Deming, E. G.: Y-V advancement pedicles in surgery for Dupuytren's contracture. *Plast. & Reconstruct. Surg.*, 29: 581, 1962.
69. Di Porto, A.: Del rapporto causale tra morbo di Dupuytren e trauma. *Folia med.*, 41: 1075, 958.
70. Doane, A.: *Sidney Clinical Lectures on Surgery, Delivered at Hotel Dieu, 1832, by Baron Dupuytren*. Published by an association of physicians and translated from the French. Collins & Hannay, New York, 1833.
71. Dueben, H.: Our procedure in Dupuytren's contracture. *Chirurg*, 31: 343, 1960.
72. Dupuytren, G.: Permanent retraction of the fingers produced by an affection of the palmar fascia. *Lancet*, 2: 222, 1834.
73. Dupuytren, G.: Permanent retraction of the fingers produced by an affection of the palmar fascia. *Med. Classics*, 4: 142, 1939.
74. Dupuytren, G.: *Lecons orales de clinique chirurgicale faites a l'Hotel Dieu de Paris*. Vol. I, Chap. 1. Germer Bailliere, Paris, 1832.
75. Dupuytren, G.: Fascicule d'observations sur la retraction des doigts. *J. Univ. Hebd. méd. chir. prat. Paris*, 6: 67, 1832.
76. Dupuytren, G.: De la retraction des doigts par suite d'une affection de l'aponeurose palmaire; operation chirurgicale qui convient dans ce cas. *Gaz. Méd. Paris*, 111: 41, 1832.
77. Dupuytren, G.: Op. cit. See also *J. Univ. Hebd. méd. Chir. Prat.*, 5: 348, 1932.
78. Dupuytren, G.: Translated from the French in *J. Med. & Surg.*, 1: 266-268, 1832.
79. Dupuytren's contracture. *Lancet*, 1: 97, 1961.
80. Durel, L.: *Essai sur la Maladie de Dupuytren*. These, Paris, 1887.
81. Early, P. F.: Population studies in Dupuytren's Contracture. *J. Bone & Joint Surg.*, 44: 602, 1962.
82. Ebstein, W.: Zür Aetiologie der Dupuytren'schen Kontraktur. *Duetsches Arch. klin. Med.*, 103: 201, 1911.
83. El Banharoy, A.: Dupuytren's disease of the foot (fibroenostosis of the plantar fascia). *J. Egypt. M. A.*, 43: 378, 1960.
84. Ely, L. W.: Dupuytren's Contracture. *S. Clin. North America*, 6: 421, 1926.
85. Einarsson, F.: Treatment of Dupuytren's Contracture. *Acta chir. scandinav.*, 93: 1, 1946.
86. Erichsen, J. E.: *The Science and the Art of Surgery*. London, 1877.
87. Exner, G.: Dupuytren's Contracture: successful therapy. *München med. Wehnschr.*, 92: 261, 1950.
88. Fawteux, M., and Ripstein, C. E.: Dupuytren's contracture associated with coronary disease. *Canad. M. A. J.*, 58: 502, 1948.
89. Ferguson, W.: *A System of Practical Surgery*. Blanchard & Lea, Philadelphia, 1853.
90. Fernandez-Rojas, F.: La contractura de Dupuytren con relacion a la ley 9688 casos. *Prensa méd. argent.*, 34: 1043, 1947.
91. Ferrari, A.: Clinical and etiopathogenetic study of two rare cases of Dupuytren's contracture. *Minerva med.*, 2: 230, 1945.
92. Ferrarim, M.: Dupuytren's contracture. *Arch. ital. chir.*, 1: 57, 1939.
93. Finney, R.: Dupuytren's contracture, a radiotherapeutic approach. *Lancet*, 2: 1064, 1953.
94. Finney, R.: Dupuytren's contracture. *Brit. J. Radiol.*, 28: 610, 1955.
95. Fowler, G. R.: *A Treatise on Surgery*. W. B. Saunders & Co., 1906.
96. Franchini, C.: Dupuytren's contracture, vitamin E therapy, case. *Ross. studi psichiat.*, 41: 59, 1952.
97. French, H. S.: *An Index of Differential Diagnosis of Main Symptoms by Various Authors*. W. Wood & Co., New York, 1919.
98. Furlong, R.: Dupuytren's contracture. *Practitioner*, 130: 498, 1958.
99. Gallardo, F. A.: Contractura de Dupuytren. *Repert. med. cir.*, 2: 424, 1947.
100. Galletti, G.: Therapy by means of subtotal aponeurectomy and excision of superfluous skin and tubed grafts. *Arch. ital. chir.*, 72: 345, 1949.
101. Gant, F. J.: *The Science and Practice of Surgery*. London, 1878.
102. Garrod, A. E.: Concerning pads upon the finger joints and their clinical relationships. *Brit. M. J.*, 1: 665, 1875.
103. Geck, A. O.: Ueber die Dupuytren'sche Fingerkontraktur. Inaugural dissertation, Bonn, 1889.
104. Gelfab, M., and Michaelides, P.: Plantar fibromatosis. *Acta Dermat. (Chic)*, 85: 278, 1962.
105. Gilbert, M.: Sur un mémoire de M. Leopold Levi, concernant la retraction de l'aponeurose palmaire et le traitement thyroïdien. *Bull. Acad. Med.*, 99: 23, 1913.
106. Girdwood, R.: An unusual cause of Dupuytren's Contraction. *Brit. M. J.*, 11: 650, 1916.

107. Goetzee, A. E., and Williams, H. O.: Dupuytren's contracture, case involving hand and foot in a child. *Brit. J. Surg.*, 42: 417, 1955.
108. Gordon, S. D.: Dupuytren's contracture. *Canad. M. A. J.*, 58: 543, 1948.
109. Gordon, S. D.: Address at meeting of American Society of Plastic and Reconstructive Surgery, Galveston, Texas, 1954.
110. Gordon, S. D.: Dupuytren's contracture: recurrence and extension following surgical treatment. *Brit. J. Plast. Surg.*, 9(4): 286, 1956.
111. Gordon, S. D.: Significance of factors in etiology of Dupuytren's contracture. *Ann. Surg.*, 140: 683, 1954.
112. Gordon, S. D.: Dupuytren's contracture: hereditary as an etiological factor. *Canad. J. Surg.*, 2 (4): 421, 1959.
113. Gordon, S. D., and Anderson, W.: Dupuytren's contracture following injury. *Brit. J. Plast. Surg.*, 14: 129, 1961.
114. Gosset, J.: Surgical therapy of Dupuytren's contracture (McIndoe technique). *Semaine hôp. Paris*, 27: 2330, 1951.
115. Gosset, J.: Therapy of Dupuytren's disease by means of McIndoe method. *Mém. Acad. Chir.*, 77: 312, 1951.
116. Gosset, J., and Leroux, M.: On the treatment of Dupuytren's disease. *Ann. Chir.*, 13: 989, 1959.
117. Golding, J. S. R.: Dupuytren's contracture. *Postgrad. M. J.*, 27: 463, 1951.
118. Goyrand, G.: Sur la retraction permanente des doigts. *Mém. Acad. méd. Paris*, 111: 489, 1833.
119. Grdovic, M.: Dupuytrenova Kontraktura. *Acta Chirurg.*, 1: 51, 1950.
120. Graubard, D. J.: Dupuytren's contracture: etiologic study. *J. Internat. Coll. Surgeons*, 21: 15, 1954.
121. Gutzeit, K.: Rheumatic and trophoneurotic clinical pictures in relation to vertebral symptoms, vertebral body, Dupuytren's contracture, vertebral localization effect. *Medizinische*, 1343, 1954.
122. Gray, G. A., and Tarnowsky, G. O.: Dupuytren's contracture: two cases. *U.S. Armed Forces M. J.*, 1: 49, 1950.
123. Hadji-Dimo, A., and Scouras, P.: Dupuytren's contracture. *P. Rev. Neurol.*, 79: 680, 1947.
124. Hamlin, E.: Limited excision for Dupuytren's contracture. *Ann. Surg.*, 135: 94, 1952.
125. Hamlin, E.: Limited excision of Dupuytren's contracture: a follow-up study. *Ann. Surg.*, 155: 454, 1962.
126. Hammond, G., and Dotter, W. E.: Quadrilateral contracture, case. *Guthrie Clin. Bull.*, 18: 34, 1948.
127. Hampl, K.: Dupuytren's contracture in engine drivers. *Pracov Lek.*, 12: 358, 1960.
128. Hartley, F. K.: Deformity of the hand. An unusual case of Dupuytren's contracture. *J. Kansas M. Soc.*, 63: 193, 1962.
129. Hartmann and Okinczie: Cited by G. Labey, *Enciclopedia de Ciencias Médicas*, 1906.
130. Harding, H. E.: Dupuytren's contracture of hands and feet. *Proc. Roy. Soc. Med.*, 48: 64, 1955.
131. Heim, W., and Buchberger, H. G.: Zür Aetiologia und Pathogenese der Dupuytren'schen Kontraktur. *Chirurg*, 30 (5): 212, 1959.
132. Heim, W., and Buchberger, H. G.: On the therapy of Dupuytren's contracture. *Chirurg*, 31: 339, 1960.
133. Henry, C.: Coexistence of ophthalmic migraine and retraction of palmar aponeurosis of Dupuytren's type in two individuals of the same family: favorable effects of vitamin E. *Bull. Soc. opht. France*, pp. 93-94, 1954.
134. Herzog, E. G.: Etiology of Dupuytren's contracture, in relation to work. *Lancet*, 1: 1305, 1951.
135. Heyse, W. E.: Dupuytren's contracture and its surgical treatment. Clinical study of a local resection method. *J. A. M. A.*, 174: 1945, 1960.
136. Hill: Cited by Webster, 1956.
137. Hines, R. A.: Peripheral neuritis following isoniaziol therapy, appearance of Dupuytren's contracture and Raymond phenomenon. *J. A. M. A.*, 159: 1197, 1955.
138. Hofmeister: Die Fingerknöchelpolster, eine Sonderform der Dupuytren'schen Kontraktur. *Chirurg*, 28 (1): 35, 1957.
139. Hollander, L., Adloff, M., and Siffer, I.: Réflexions à propos de 26 cas de maladie de Dupuytren. *Strasbourg med.*, 8 (3): 181, 1957.
140. Horand, R.: A propos de la camtodactylie ou inflexion permanente du petit doigt, et parfois des doigts voisins d'origine tuberculeuse. *Gaz. Hôp.*, 31: 231, 1908.
141. Horwitz, T.: Dupuytren's contracture: a consideration of the anatomy of the fibrous structures of the hand in relation to this condition with an interpretation of the histology. *Arch. Surg.*, 44: 687, 1942.

142. Hueston, J. T.: The incidence of Dupuytren's contracture. *M. J. Australia*, 47 (2): 999, 1960.
143. Hueston, J. T.: Limited fasciectomy for Dupuytren's contracture. *Plast. & Reconstruct. Surg.*, 27: 569, 1961.
144. Hueston, J. T.: Digital Wolfe grafts in recurrent Dupuytren's contracture. *Plast. & Reconstruct. Surg.*, 29: 342, 1962.
145. Hueston, J. T.: Further studies on the incidence of Dupuytren's contracture. *M. J. Australia*, 49 (1): 586, 1962.
146. Huffstadt, A. J. C.: Surgical therapy of Dupuytren's contracture. *Nederl. tijdschr. geneesk.*, 96: 2483, 1952.
147. Huffstadt, A. J. C.: Chirurgische behandeling van de contractuur van Dupuytren. *Ned. tsschr. geneesk.*, 101 (24): 1150, 1957.
148. Hutchinson, J.: Dupuytren's contraction of the palmar fascia. *Lancet*, 1: 285, 1917.
149. Ikle, C.: Dupuytren's contraction. *Deutsch. Ztschr. Chir.*, 106: 212, 1928.
150. Iselin, M., and Dieckmann, D. G.: Therapy by means of complete Z-shaped plastic surgery. *Presse méd.*, 59: 1394, 1951.
151. Iselin, M., and Dieckmann, D. G.: Therapy of Dupuytren's contracture. *Mém. Acad. chir.*, 77: 251, 1951.
152. Iverson: Cited by Webster, 1909.
153. Jaerisch, M.: Ueber Dupuytren'sche Fingerkontrakturen. Inaugural dissertation, Halle a.s., 1898.
154. James, J. I. P., and Tubiana, R.: La maladie de Dupuytren. *Rev. Chir. Orthop.*, 38: 352, 1952.
155. Janssen, P.: Zür Lehre von der Dupuytren'schen Fingerkontraktur. *Arch. klin. Chir.*, 67: 761, 1902.
156. Johnson, A. C.: Dupuytren's contracture. *Ann. Int. Med.*, 19: 433, 1943.
157. Jolicoeur, A., and Vandeput, J.: Dupuytren's contracture. *Laval méd.*, 33: 261, 1962.
158. Jones, A. R.: Dupuytren's contracture. *Med. Press Circ.*, 14: 206, 1941.
159. Jones, R.: *Minutes of Evidence of Departmental Committee Appointed to Inquire and Report on Dupuytren's Contracture*. Eyre & Spottiswood, London, 1913.
160. Kanavel, A. B., Koch, S. L., and Mason, M. L.: Dupuytren's contracture, with a description of the palmar fascia. A review of the literature and a report of 29 surgically treated cases. *Surg. Gynec. & Obst.*, 48: 145, 1929.
161. Kaplan, E. B.: *Anatomía funcional y quirúrgica de la mano*. Ed. Artecnic, Buenos Aires, 1961.
162. Kartschikjan, S. I.: Dypuytren'sche Kontraktur under Erbllichkeit. *Ztschr. Orthop.*, 18: 36, 1927.
163. Keen, W. W.: The etiology and pathology of Dupuytren's contraction of the fingers. *M. Times*, 12: 370, 1881.
164. Keen, W. W.: *Buck's Reference Handbook of the Medical Sciences*. New York, 1886.
165. Keen, W. W.: *Surgery, Its Principles and Practice*. Philadelphia, 1909.
166. Keen, W. W.: A new method of operating on Dupuytren's contraction of the palmar fascia, together with the successful use of neural infiltration in such operations. *Am. J. M. Sc.*, 131: 23, 1906.
167. Kehl, K. G.: Dupuytren's contracture as a sequel to coronary artery disease and myocardial infarction. *Ann. Int. Med.*, 19: 213, 1943.
168. Kelly, A. P., and Clifford, R. H.: Subcutaneous fasciotomy in the treatment of Dupuytren's contracture. *Plast. & Reconstruct. Surg.*, 24: 505, 1959.
169. Kholevich, I. A., Paneva-Kholevich, E., and Matev, I.: Nashiat opit s lechenieto na Diupuytrenovata kontraktura po sposobite na Burian: Karfik. *Khirurgija*, Sofia, 9: 798, 1956.
170. King, R. A.: Vitamin E therapy in Dupuytren's contracture. Examination of the claim that vitamin E is successful. *J. Bone & Joint Surg.*, 31 (B): 443, 1949.
171. Kingsbury, G. C.: Dupuytren's contraction of the palmar fascia treated by hypnotism. *Brit. M. J.*, 1: 62, 1891.
172. Kirk, J. E., and Chieffi, M.: Tocopherol administration to patients with Dupuytren's contracture. Effect on plasma tocopherol levels and degree of contracture. *Proc. Soc. Exper. Biol. & Med.*, 80: 565, 1952.
173. Knaibl, P. V.: Tratamiento quirúrgico de la retracción palmar. *Congreso Latinoamericano de Cirugía Plást (Anales)*, 4: 406, 1949.
174. Koch, S.: The covering of raw surface with particular reference to the hand. *Surg. Gynec. & Obst.*, 13: 677, 1926.
175. Koch, S. L.: Dupuytren's contracture. *J. A. M. A.*, 100: 878, 1933.
176. Kocher, T.: Behandlung der Retraktion der Palmaraponeurose. *Zentralbl. Chir.*, 14: 481, 1887.
177. Kohler, C. J.: Observations on three Dupuytren's contractures of the palmar aponeurosis: with a contribution to the etiology of Dupuytren's contracture. *Ztschr. Orthop.*, 92: 118, 1959.

178. Kostia, J. A.: Dupuytren's contracture: family. *Ann. chir. et Gynaec. Fenniae*, 46 (3): 351, 1957.
179. Krogius, A.: Dupuytren's contracture. *Zentralbl. Chir.*, 47: 914, 1920.
180. Kramer, W., and Leten, J.: Dupuytren's contracture during epilepsy. *Nederl. tijdschr. geneesk.*, 95: 3023, 1951.
181. Laane, C. L.: Dupuytren's contracture, familial occurrence. *Nord. med.*, 45: 52, 1951.
182. Labey, G.: *Enciclopedia de Ciencias Medicas*, edited by S. A. Fernandez. Brissaud, Pinard, and Rechis, Madrid, 1906.
183. Lamphier, T. A., Wickman, W., Covino, J., and Long, N. G.: The clinical aspects of Dupuytren's contracture. *J. Internat. Coll. Surgeons*, 26 (2): 232, 1956.
184. Langenbeck: *Deutsche Arch. klin. Med.*, 50: 1863.
185. Langhans: Cited by Kocher. *Zentralbl. Chir.*, 14: 497, 1887.
186. Langier, R., and Rutishauser, E.: *Anatomie pathologique et pathogénie de la Maladie de Dupuytren*. Presse méd., 64: 1212, 1956.
187. Langston, R. G., and Badre, E. J.: Dupuytren's contracture. *Canad. M.A.J.*, 58: 57, 1948.
188. Langston, R. G., and Cowan, R. J.: Dupuytren's contracture, survey of cases 5 years after operation. *J. Internat. Coll. Surgeons*, 23: 710, 1955.
189. Lane, W.: About flexions of the fingers: Dupuytren's, etc. and some senile changes in joints. *Guy's Hosp. Rep.*, 28: 53, 1884.
190. Larsen, R. D., and Posch, J. L.: Dupuytren's contracture. *Surg. Gyn. & Obst.*, 115: 1, 1962.
191. Larsen, R. D., and Posch, J. L.: Dupuytren's contracture, with special reference to pathology. *J. Bone & Joint Surg.*, 40 (A): 773, 1958.
192. Larsen, R. D., Takagishi, U., and Posch, J. L.: The pathogenesis of Dupuytren's contracture. Experimental and further clinical observations. *J. Bone & Joint Surg.*, 42(A): 993, 1960.
193. Laufer, M.: Dupuytren's contracture involving all four limbs: case. *Casop. lék. česk.*, 92: 468, 1953.
194. Lawton, R. L., Conklin, R. A., and Brinall, E. S.: Dupuytren's contracture. *J. Iowa M. Soc.*, 51: 275, 1961.
195. Lechelle, P., Raruk, H., and Douady, D.: Association de sclérodémie et la maladie de Dupuytren chez spécifique. *Bull. et mém. Soc. méd. hôp. Paris*, 51: 622, 1927.
196. Le Chiton, M.: Traitement de la maladie de Dupuytren par téno-aponéurectomie anti-brachiale du petit palmaire. *Mém. Acad. chir.*, 83: 930, 1957.
197. Le Chiton, M.: Traitement de la maladie de Dupuytren par téno-aponéurectomie anti-brachiale du petit palmaire. *Rev. méd. nar. Paris*, 13: 131, 1958.
198. Ledoux, A., Magnin, P., Picard, M., Nicod, B., and Colord, M.: The association of pulmonary fibrosis and Dupuytren's disease. *Semaine hôp. Paris*, 37: 3348, 1961.
199. Ledderhose, G.: Die Aetiologie der Fasciitis palmaris (Dupuytren'sche Kontraktur). *München. med. Wchnschr.*, 27: 1254, 1920.
200. Leopold-Levi: Concernant la retraction de l'aponuerose palmaire et le traitement thyroïden. *Bull. Acad. nat. méd.*, 19: 23, 1913.
201. Lewis, G. R.: Dupuytren's contracture. *Clin. Med.*, 69, 73, 1962.
202. Lexer, E.: *General Reconstructive Surgery*. J. A. Barth, Leipzig, 1931.
203. Lievre, J. A.: Dupuytren's disease with trophic and vasomotor disorders of hands after angina pectoris: case. *Bull. et mém. Soc. méd. hôp. Paris*, 63: 866, 1947.
204. Little: *Holmes System of Surgery*, London, 1870.
205. Lima, E. V. De: Dupuytren's contracture as a manifestation of coronary insufficiency. *Brasil-méd.*, 67: 636, 1953.
206. Lithgow, F. W.: Dupuytren's contracture with report of a case. *Bol. Asoc. méd. Santiago*, 5: 226, 1947.
207. Loewy, J.: Ein Beitrag zur Heredität der Dupuytren'schen Kontraktur. *Zentralbl. inn. Med.*, 14: 51, 1923.
208. Lorenzen, J.: Cutaneous hydrocortisone solution in Dupuytren's contracture. *Nord. Med.*, 62: 1151, 1959.
209. Lorin, J.: Frequency of Dupuytren's disease in manual labourers, medico-social aspects. *Arch. mel. profess.*, 14: 71, 1953.
210. Luck, J. V.: Dupuytren's contracture: a new concept of the pathogenesis correlated with surgical management. *J. Bone & Joint Surg.*, 41 (A): 635, 1959.
211. Luck, J. V.: *Cyclopedia of Medicine, Surgery, and Specialties*. F. A. Davis & Co., Philadelphia, 1956.
212. Lund, M.: Dupuytren's contracture and epilepsy; the clinical connection between Dupuytren's contracture, fibroma plantare, periarthrites humeri, xeroderma, induratio penis plastica and epilepsy, with an attempt at pathological evaluation. *Acta. psychiat. et neurol.*, 16: 465, 1941.
213. MacCallum, P., and Hueston, J. T.: The pathology of Dupuytren's contracture. *Australian & New Zealand J. Surg.*, 31: 241, 1962.

214. MacMahon, H. E.: Baron Guillaume Dupuytren and the palmar contracture that bears his name. *Bull. Tufts New England M. Center*, 5: 2, 1959.
215. Madelung, O. W.: Die Aetiologia und die operative Bhandlung der Dupuytren'schen Fingerverkruemung. *Klin. Wehnschr.*, 12: 191, 1875.
216. Macready, J.: On the treatment of Dupuytren's contracture of the palmar fascia. *Brit. M. J.*, 1: 411, 1890.
217. Malgaigne, J. F.: *Leçons D'orthopedie Professées à la Faculté de Medicine de Paris: Docteurs Guyon et Panas*. A. Delahay, Paris, 1862.
218. Manson, J. S.: Dupuytren's contracture. *Brit. M. J.*, 2: 11, 1931.
219. Maranzana, P.: Question of trauma as sole cause of contracture of palmar aponeurosis: case. *Minerva medicoleg.*, 70: 174, 1950.
220. Mars, G., Morpurgo, M., and De Ponti, L.: Contributo clinico-tradiologico al problema dell'etiopatogenesi della malattia di Dupuytren. *Gior. Gerentol. Fir.*, 6: 486, 1958.
221. MacFarlane, R. M.: Use of continuous suction after operation for Dupuytren's contracture. *Brit. J. Plast. Surg.*, 11: 301, 1959.
222. Mason, M. L.: Dupuytren's contracture. *S. Clin. North America* 32: 233, 1952.
223. Mason, M. L.: Dupuytren's contracture. *Arch. Surg.*, 65: 457, 1952.
224. Matthews, D. N.: Dupuytren's contracture. *Practitioner*, 169: 641, 1952.
225. Mattioli-Foggia, C., and Fiorentino, M.: Congenital pseudo Dupuytren's contracture of Palm. *Riv. Anat. Pat. e Oncol.*, 7: 665, 1953.
226. Maurer, G.: Studies on Dupuytren's contracture of the palmar fascia and its treatment. *Deutsch. Ztschr. f. Chir.*, 246: 685, 1936.
227. May, H.: Repair of Dupuytren's contracture of the hand. *Plast. & Reconstruct. Surg.*, 3: 439, 1948.
228. Mayer, J. C., and Biriswanger, H. F.: Dupuytren's contracture. *Am. Heart J.*, 23: 715, 1942.
229. McIndoe, A., and Beare, R. L.: The surgical management of Dupuytren's contracture. *Am. J. Surg.*, 95: 197, 1958.
230. McQuenn, C.: Case of bilateral contracture occurring in association with spondylitis ankylopoietica. *M. J. Australia*, 1: 434, 1947.
231. Meacher, S. W.: The Dupuytren's contracture controversy. A presentation of facts. *J.A.M.A.*, 180: 140, 1962.
232. Meyerding, H. W.: Dupuytren's contracture. *Proc. Staff Meet. Mayo Clin.*, 10: 694, 1935.
233. Meyerding, H. W.: Dupuytren's contracture. *Am. J. Surg.*, 49: 94, 1940.
234. Meyerding, H. W.: Dupuytren's contracture. *Arch. Surg.*, 32: 32, 1936.
235. Meyerding, H. W., Black, J. R., and Broders, A. C.: The etiology and pathology of Dupuytren's contracture. *Surg. Gynec. & Obst.*, 72: 582, 1941.
236. Meyerding, H. W., and Krusen, F. H.: Dupuytren's contracture. *Physiotherapy Rev.*, 16: 42, 1936.
237. Montuori, R.: Su di un caso di malattia de Dupuytren. *Riforma Médica*, 70: 1157, 1956.
238. Moorhead, J. J.: Dupuytren's contracture, trauma and contracture. *Am. J. Surg.*, 85: 352, 1953.
239. Moorhead, J. J.: Dating the onset of Dupuytren's contracture. *Am. J. Surg.*, 92: 571, 1956.
240. Moorhead, J. J.: Dupuytren's contracture: review of the disputed etiology. *New York J. Med.*, 56: 3686, 1956.
241. Michaux, J., Lamache, A., and Picard, J.: La rétraction de l'aponeurose palmaire dans le saturnisme. *Bull. et mém. Soc. méd. hôp. Paris*, 19: 782, 1925.
242. Montesano, G.: Dupuytren's contracture following accident: case. *Med. lavoro*, 38: 338, 1947.
243. Moreno Blanco, E., and Monzonis Broch, F.: Dupuytren's contracture: cervical arthrosis as possible origin. *Rev. españ. reum.*, 6: 97, 1955.
244. Murinedu, A.: Therapy of retraction of palmar aponeurosis by means of vitamin A E (alfa-tocopherol). *Riforma méd.*, 67: 1139, 1953.
245. Neutra, W.: Beitrag zur Aetiologie der Dupuytren'schen Fingerkontraktur. *Wien. klin. Wehnschr.*, 14: 907, 1901.
246. Nezelhof, C., and Tubiana, R.: La maladie du Dupuytren: étude histologique. *Semaine hôp. Paris*, 34: 1102, 1958.
247. Nichols, J. B.: The histology of Dupuytren's contraction of the palmar fascia; report of the microscopical examination in two additional cases. *Med. News, New York*, 25: 491, 1899.
248. Niederlan, W.: Dupuytren's contracture. *Med. Welt.*, 7: 126, 1933.
249. Nippert: Dupuytren's contracture. *Deutsch Ztschr. f. Chir.*, 216: 289, 1929.
250. Noica, I., and Parvulesco, I. I.: Dupuytren's contracture. *Rev. san. med.*, 31: 3, 1932.
251. Noix, M.: Allythiuren in therapy of Dupuytren's contracture. *J. radiol. et d'electrol.*, 27: 476, 1946.

252. Oldfield, M. C.: Dupuytren's contracture. Proc. Roy. Soc. Med., 47: 361, 1954.
253. Ott, A.: Zur Röntgentherapie der Dupuytren'schen Krankheit. Wein klin. Wchnschr., 68: 608, 1956.
254. Oman, C. M.: *Dupuytren's Contracture, Minor Surgery*. Oxford University Press, London, New York, Toronto, 1942.
255. Padovani, P., and Lord, C.: Cervical arthrosis and Dupuytren's disease. Semaine hôp. Paris, 27: 1955, 1951.
256. Paeslack, V.: Dupuytren's contracture and diabetes mellitus. Schweiz. med. Wchnschr., 92: 349, 1962.
257. Paget, J.: On minor signs of gout in the hands and feet. Brit. M. J., 1: 665, 1875.
258. Paillard and Marx: Verbatim report of Dupuytren's lecture of Dec. 5, 1831. J. Univ. et Hebd.: 349, 1831.
259. Palmer, L. A., and Southworth, J. L.: Bridge operation. Am. J. Surg., 68: 351, 1945.
260. Parone, M., and Tregole, E.: On the surgical treatment of Dupuytren's disease. Rass. int. clin. ter., 41: 927, 1961.
261. Parrini, L., and Brunelli, G.: Considerations on the surgical therapy of Dupuytren's disease. Arch. ortop., 72: 1089, 1959.
262. Parsons, A. R.: Treatment of Dupuytren's contracture with massive doses of Vitamin E. Irish J. M. Sc., 272, 1948.
263. Pedersen, H. E.: Dupuytren's disease (fibromatosis of the plantar fascia) of foot. J. A. M. A., 154: 33, 1954.
264. Peiser, A.: Freie Fettransplantation bei der Behandlung der Dupuytren'schen Fingerkontraktur. Zentralbl. Chir., 14: 68, 1917.
265. Perusi, A.: Retraction of the plantar aponeurosis and periarthrits of the shoulder. Arch. ortop., 67: 83, 1954.
266. Pfandler, N.: Hereditary mechanism of Dupuytren's contracture. Acta geneti. med. et gemel., 4: 296, 1955.
267. Plater, F.: Observationem liber, 1: 140, 1614. Cited by Durel, *Essai sur la maladie de Dupuytren*. Thesis, Paris, 1887).
268. Pietrogrande, V., and Maiotti, A.: Retraction of the palmar aponeurosis. Ortop. e Traumatol., 23: 323, 1955.
269. Pirovano, A.: Modern orientation in therapy of Dupuytren's disease of palm. Chi. e Pat. Sper., 2: 848, 1954.
270. Powers, H.: Dupuytren's contraction. Am. J. Phys. Therap., 8: 239, 1931.
271. Powers, H.: A new theory of origin of Dupuytren's contracture. Arch. Neurol. and Psychiat., 28: 955, 1932.
272. Powers, H.: Dupuytren's contracture. J. Nerv. & Ment. Dis., 80: 386, 1934.
273. Rabboni, F.: Surgical therapy of Dupuytren's contracture. Riforma med., 65: 799, 1951.
274. Rasin, F., and Dvorak, V.: Our experiences with radium-irradiation of Dupuytren's contracture. Cesk. Roentgnol., 13: 393, 1959.
275. Reichel: Trophic nerves and Dupuytren's contracture. Chirurg, 18: 97-100, 1917.
276. Reifferscheid, M., and Matis, P.: Vitamin E in therapy of circulatory disorders, Dupuytren's contracture and thrombosis. Med. Welt., 20: 1168, 1951.
277. Renard Saraux, H., and Ganem, J.: Primary hand shaped opacity of the cornea and its associations à propos of a case associated hand shaped opacity and Dupuytren's disease. Bull. Soc. opht. France, 2: 56, 1960.
278. Rev, J.: Die orthopädische Behandlung de Hand und Fingerkontrakturen. Ztschr. Orthop., 18: 21, 1927.
279. Richards, H. J.: Dupuytren's contracture: surgical treatment. J. Bone & Joint Surg., 36(B): 90, 1954.
280. Richards, H. J.: Dupuytren's contracture treated with Vitamin E. Brit. M. J., 1: 1328, 1952.
281. Richards, H. J.: Dupuytren's contracture. Med. Illus., 7: 896, 1953.
282. Richer, P.: Rétraction de l'aponevrose palmaire. Proar. Med., 5: 369, 1877.
283. Ritchey, S. J.: Dupuytren's contracture and use of cortisone (adrenocortical preparation). U.S. Armed Forces M.J., 3: 811, 1952.
284. Riniker, P.: Dupuytren's contracture; pathogenesis. Schweiz. Ztschr. allg. Path., 17: 751, 1954.
285. Riordan, D. C.: Dupuytren's contracture. Southern M. J., 54: 1391, 1961.
286. Rosenauer, F.: Dupuytren'sche Kontraktur an allen 4 Extremitäten. Arch. Orthop. u. Unfall-Chir., 49 (1): 20, 1957.
287. Ross, J. A., and Annan, J. H.: Clinical review of Dupuytren's contracture. Ann. Surg., 134: 186, 1951.
288. Roodenburg, A. E.: Hyperplasia of the palmar aponeurosis (Dupuytren's contracture). A.M.A. Arch. Int. Med., 101: 551, 1958.
289. Routier: Cited by Labey, 1906, *Encyclopedia of Medical Sciences*.
290. Routier: Cited by Webster, 1908.

291. Rossi, B. C., and Gonzalez, V. J.: Angina pectoris y retracción digitopalmar de ambas manos. *Caso. Semana méd.*, 2: 1000, 1944.
292. Russ, R.: The surgical aspects of Dupuytren's contracture. *Am. J. M. Sc.*, 135: 856, 1908.
293. Salmon: Maladie de Dupuytren grave; aponevrectomie palmaire; allongement tendineux pour transposition des tendons fléchisseurs superficiels sur les profonds; greffe cutanée, résultat excellent, présentation de malade. *Marseille chir.*, 10 (4): 481, 1958.
294. San Martino, A.: Sul trattamento chirurgico della malattia di Dupuytren. *Minerva ortop.*, 8 (10): 538, 1957.
295. San Martino, A.: Lineamenti di patologia della malattia di Dupuytren; rilievi istologici, oscillografici, fotopletismografici. *Chir. org. movimento*, 45 (1): 59, 1957.
296. Schenck, E., and Bayer, H.: Electromyographic studies in contracture of the fingers. *Deutsche Ztschr. Nervenhe.*, 171: 102, 1953.
297. Schiller, H.: Dupuytren's contracture: medico-legal evaluation. *Zentralbl. Arbeitsmed. u. Arbeitsschutz*, 3: 89, 1953.
298. Schink, W.: Surgical treatment of Dupuytren's contracture. A report on 100 surgically treated hands. *Arch. klin. Chir.*, 299: 118, 1961.
299. Schlegel, J. J.: Resultate der operativen Behandlung der Dupuytren'schen Kontraktur. *Helvet. chir. acta*, 25 (4-5): 372, 1958.
300. Schiller, H.: Dupuytren's contracture; medico-legal evaluation. *Zentralbl. Arbeitsmed. u. Arbeitsschutz*, 3: 89, 1953.
301. Schulthess, O.: Ein Beitrag zur pathologischen Anatomie der Dupuytren'schen Palmarfascienkontraktur. Inaugural dissertation of Munich University, Noerdlingen, 1888.
302. Scholz, O.: Dupuytren's contracture; pathogenesis. *Zentralbl. Chir.*, 78: 104, 1953.
303. Sevestre, A.: Note sur un cas de rétraction permanents des doigts. *J. Anat. et. Physiol.*, 4: 250, 1867.
304. Shaw, M. H.: Treatment of Dupuytren's contracture. *Brit. J. Plast. Surg.*, 4: 218, 1951.
305. Shaw, M. H., and Barclay, T. L.: Results of Radical Fasciectomy. *Transactions of the International Society of Plastic Surgeons, First Congress*, edited by T. Skoog and R. H. Ivy. Williams & Wilkins Co., Baltimore, 1957.
306. Shinkarenko, I. N.: Kombinirovannoe lechenie kontraktur Dupuytren'a s. primenien qialuronidaznykh preparatov (Combined use of hyaluronidase preparations for treatment of Dupuytren's contracture). *Ortop. travm. protez. Moskva*, 20: 23, 1959.
307. Silva, F.: Doença de Dupuytren; em torno de un caso clinico. *Brasil-méd.*, 38: 269, 1924.
308. Skoog, T.: Dupuytren's contracture with special reference to etiology and improved surgical treatment; its occurrence in epileptics; note on knuckle pads. *Acta chir. scandinav.*, 96: 1, 1948.
309. Skoog, T.: Dupuytren's contracture. *Postgrad. Med.*, 21: 91, 1957.
310. Skoog, T.: The pathogenesis and etiology of Dupuytren's contracture. *Plast. & Reconstruct. Surg.*, 31: 258, 1963.
311. Smith, N.: Seventy cases of Dupuytren's contraction of the fingers. *Brit. M. J.*, 1: 603, 1884.
312. Smith, N.: Cited by J. A. Wyeth, 1908.
313. Smith, K. D., and Masters, W. E.: Dupuytren's contracture as an occupational disease. *J. Indust. Hygiene & Toxicol.*, 21: 233, 1939.
314. Snyder, C. C.: The contracture of Dupuytren. *Am. Surgeon*, 23: 487, 1957.
315. Soderberg, L.: Treatment of Dupuytren's contracture. *Acta orthop. scandinav.*, 20: 184, 1951.
316. Spadadora, A.: Apparatus for therapy. *Prensa méd. argent.*, 38: 1636, 1951.
317. Specklin, P., and Stoeber, R.: Rétraction des aponevroses palmaires et plantaires avec nevralgies; guérison par les radiations. *Presse méd.*, 30: 741, 1922.
318. Spina, G. M., and Tessari, L.: Some histochemical findings on Dupuytren's disease. *Arch. ortop.*, 73: 882, 1960.
319. Spiste, B.: Bilateral symmetrical contractures of the hand and phalanges. *Case. Ztschr. Orthop.*, 75: 33, 1944.
320. Spitzzy, H.: Behandlung von Hand und Fingerkontrakturen mit kuenstlicher Fettumscheidung. *Ztschr. Orthop. Chir.*, 35: 550, 1915.
321. Stahne, E.: Zür Behandlung der Dupuytren'schen Fingerkontraktur. *Zentralbl. Chir.*, 54: 2438, 1927.
322. Stein, A., Wang, M. K., Newcomber, W. B., Rajfalk, and Heffenan, A.: Dupuytren's contracture: a new philogenic evaluation of the pathogenesis. *Am. Surgeon*, 161: 577, 1960.
323. Steinberg, C. L.: Tocopherol in treatment of primary fibrositis. *A.M.A. Arch. Surg.*, 63: 824, 1951.
324. Steinberg, C. L.: A new method of treatment (Vit. A) of Dupuytren's contracture form of fibrositis. *M. Clin. North America*, 30: 221, 1946.

325. Steinberg, C. L.: Fibrositis (muscular rheumatism) including Dupuytren's contracture: a new method of treatment. *New York J. Med.*, 47: 1679, 1947.
326. Stern, E. L.: Dupuytren's contracture. *Am. J. Surg.*, 54: 711, 1941.
327. Suber, W. J.: Dupuytren's contracture in the foot: case report. *J. Am. Pediat. A.*, 52: 756, 1962.
328. Teleky, L.: Dupuytren's contracture as an occupational disease. *J. Indust. Hygiene & Toxicol.*, 21: 97, 1939.
329. Teschendorf, W., and Enfinger, H.: Uber die Dupuytren'sche Kontraktur. *Med. Klin. Berl.*, 53: 760, 1958.
330. Teschemaker: Ueber das Vorkommen der Dupuytren'sche Fingerkontraktur bei Diabetes Mellitus. *Deutsche med. Wchnschr.*, 30: 604, 1904.
331. Tessari, L., and Parrini, L.: Biochemical observations on Dupuytren's disease. *Arch. ortop.*, 72: 435, 1959.
332. Thomas, A.: Vascular spasm and Dupuytren's disease. *Presse med.*, 61: 274, 1953.
333. Thomsen, W.: Dupuytren's contracture: technic of therapy. *Chirurg.*, 21: 359, 1950.
334. Thomson, G. R.: Treatment of Dupuytren's contracture with vitamin E. *Brit. M. J.*, 2: 1382, 1949.
335. Tanzer, R. C.: Dupuytren's contracture, with note on the use of "compression suture." *New England J. Med.*, 246: 807, 1952.
336. Tilley, A. R., and McDonald, G.: Dupuytren's contracture, cortisone (adrenocortical preparation) in treatment. *Treat. Serv. Bull.*, 8: 60, 1953.
337. Touzard, J.: A propos de la maladie de Dupuytren. *Lyon chir.*, 55: 298, 1959.
338. Tubiana, R.: Dupuytren's contracture. *J. Bone & Joint Surg.*, 37: 1955.
339. Turey, A. H.: Dupuytren's contracture of the palmar fascia and some deformities. *Practitioner*, 110: 214, 1923.
340. Van Den Bosch, J.: Hereditary Dupuytren contractures. *Nederl. tijdschr. geneesk.*, 99: 267, 1955.
341. Vorob'ev, U. N.: Surgical treatment of Dupuytren's contracture. *Vestnik khir.*, 79: 41, 1957.
342. Vorob'ev, V.: Dupuytren's contracture with multiple locations. *Vestnik. khir.*, 83: 141, 1959.
343. Volkman, J.: Dupuytren's contracture in all 4 extremities, induratio penis plastica, peri-arthritis humero-scapularis, keloids and pads on the finger knuckles. *Chirurg.*, 31: 337, 1960.
344. Venturini, G.: Etiopathogenic considerations and results of treatment of Dupuytren's disease. *Acta chir. ital.*, 16: 615, 1960.
345. Van Dermark, R. E.: Dupuytren's contracture of the hand. *South Dakota J. Med. & Pharm.*, 12: 461, 1959.
346. Von Seemen, H.: Zur Operation der Palmar Kontraktur. *Deutsch Ztschr. Chir.*, 246: 693, 1936.
347. Von Stapeimohr: Cited by Webster, 1947.
348. Wakefield, A. R.: Dupuytren's contracture. *S. Clin. North America*, 40: 483, 1960.
349. Wasserburger, K.: Zur Therapie Dupuytren'schen Kontraktur. *Strahlentherapie*, 100: 546, 1956.
350. Warren, R. F.: Pathology of Dupuytren's contracture. *Brit. J. Plast. Surg.*, 16: 224, 1953.
351. Waller, J. I., and Dreese, W. C.: Dupuytren's contracture associated with Peyronie's disease. *J. Urol.*, 68: 623, 1952.
352. Walthers, J. H., and Zahra, A.: The etiology of Dupuytren's contracture in Eastern Nigeria. *Tr. R. Soc. Trop. Med. & Hyg.*, 51: 346, 1957.
353. Webster, G. V.: A useful incision in Dupuytren's contracture. *Plast. & Reconstruct. Surg.*, 19: 514, 1957.
354. Webster, G. V.: Reappraisal of radical fasciectomy for Dupuytren's contracture. *Am. J. Surg.*, 100: 372, 1960.
355. Weber, F. P.: Camptodactylia (Landouzy) and Dupuytren's contracture. *Med. Press*, 217: 453-454, 1947.
356. Weese, K.: Die Dupuytren'sche Kontraktur. *Deutsche Gesundheitsw.*, 14: 563, 1959.
357. Weese, K.: On surgery of Dupuytren's contracture. *Brun's Beitr. klin. Chir.*, 203: 57, 1961.
358. Wegmann, T.: Parotid hypertrophy and Dupuytren's contracture in liver cirrhosis. *München. med. Wchnschr.*, 102: 1926, 1960.
359. Wegmann, T., and Geiser, W.: Frequent occurrence of Dupuytren's contracture in chronic alcoholism. *Schweiz. med. Wchnschr.*, 91: 719, 1961.
360. Wenzl, M.: Results of complete removal of palmar aponeurosis. *Wein. klin. Wchnschr.*, 62: 352, 1950.
361. Wielingia, W. J.: Dupuytren's contracture. *Nederl. tijdschr. geneesk.*, 106: 960, 1962.
362. Wilfert, F.: Therapy of Dupuytren's contracture. *Zentralbl. Chir.*, 77: 2160, 1952.

363. Wilson, J. N.: Correction of Dupuytren's contracture. *Plast. & Reconstruct. Surg.*, 29: 332, 1962.
364. White, W. H.: On pads of the finger joints. *Quart. J. Med.*, 1: 479, 1907.
365. Wolfe, S. L., Summerskill, W. H., and Davidson, C.: Thickening and contracture of the palmar fascia (Dupuytren's contracture) associated with alcoholism and hepatic cirrhosis. *New England J. Med.*, 255: 559, 1956.
366. Wyeth, J. A.: In *Surgery*, edited by M. Sims. Wyeth and Co., New York, 1908.
367. Yost, J., Winters, T., and Fett, H. C.: Dupuytren's contracture: statistical study. *Am. J. Surg.*, 90: 568, 1955.
368. Zachariae, L., and Zachariae, F.: Hydrocortisone acetate (adrenocortical preparation) in treatment of Dupuytren's contracture and allied conditions. *Acta chir. scandinav.*, 109: 421, 1955.

ADDITIONAL REFERENCES

369. Markee, J. E., and Wray, J. B.: Circulation of the hand, injection corrosive studies. *J. Bone & Joint. Surg.*, 41: 673, 1959.
370. Markee, J. E.: Personal communication.
371. Otero, F. B.: Personal communication.