

## Dermofasciectomy for Dupuytren's Disease

JOHN TURNER HUESTON, M.D.

*Summary: The empirical observation that skin replacement by free skin grafts prevents recurrence of Dupuytren's disease is applied here to the treatment of recurrent Dupuytren's disease. In young patients with a strong "Dupuytren's diathesis," this technique of skin excision along with the fascia is used prophylactically as the primary treatment.*

KNOWING Dr. Kaplan's interest in the evolution of ideas, I may be allowed to introduce this paper by relating a case of historical importance in the evolution of my philosophy of Dupuytren's disease: the first dermofasciectomy.

In 1954, on completion of my training with Sir Archibald McIndoe, I returned to succeed B. K. Rank and A. R. Wakefield as consulting plastic surgeon at Heidelberg Repatriation Hospital in Melbourne. My training with these three doyens of hand surgery led me to advise amputation of a little finger in a 32-year-old ex-serviceman whose Dupuytren's contracture had recurred twice within six months after fasciectomy by my predecessors in the previous three years. However, the patient pointed out that I had been able to completely correct a burn scar flexion deformity on the finger of another patient by using a full thickness skin graft, and he requested that I try the same technique on his severely flexed, recurrent Dupuytren's contracture before he consented to amputation.

Skeptically, and with considerable technical difficulty, I corrected the patient's little finger—incompletely but to a useable degree—and applied a Wolfe graft. Since the previous recurrences had taken place within six months of the fasciectomy, it was with mounting wonder that I found the grafted finger free of recurrence over the next four years. At that time the patient presented with moderate flexion deformity of the adjacent ring finger due to extension of the Dupuytren's contracture process (Fig. 1).

Missing the obvious lesson to be learned from the little finger, I corrected the ring finger by means of a standard fasciectomy and Z plasty

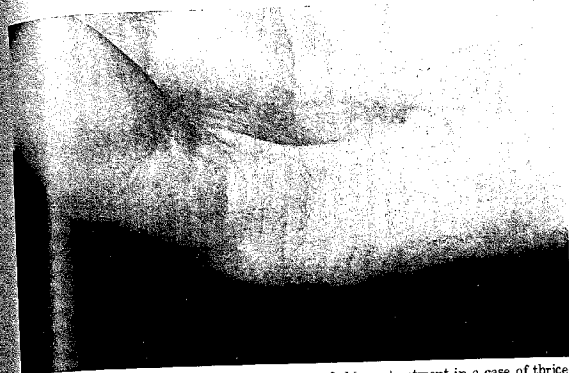


FIG. 1. Four years after the planned excision of skin as treatment in a case of three-recurrent Dupuytren's disease, there is no further recurrence. The full-thickness (Wolfe) graft on the little finger has prevented recurrence. Early extension of new disease is present in the ring finger.

When the disease recurred in this finger within six months, both the patient and I realized that skin graft resurfacing of this digit was required if further recurrence was to be avoided. Needless to say, when within the next four years the ring and little finger on the other hand developed Dupuytren's contracture, the skin was deliberately discarded on both digits at the time of fasciectomy (hence the term dermofasciectomy), and they were both resurfaced by Wolfe grafts as a primary procedure. Amputation was never discussed again. There had been no recurrence in any of this patient's four grafted fingers at the time of his death in a motor-car accident 16 years later. Long before this, however, the concept of control of aggressive Dupuytren's contracture by skin replacement had become established.<sup>1</sup>

The use of skin grafting in Dupuytren's contracture is not new. It was used by Lexer on the basis of the analogy to the correction of burn scars, by Piulachs and Mir y Mir, and by Gordon who also noted that the grafted defect remained clear of recurrence.<sup>2-4</sup> However, these pioneers had used skin replacement to repair skin defects rather than to prevent recurrence. Gonzales, using skin incision and grafting rather than skin excision and grafting, confirmed this method of managing Dupuytren's contracture.<sup>5</sup>

My concept of controlling the Dupuytren's contracture by prophylac-

Dr. Hueston is Consultant Plastic Surgeon at Royal Melbourne Hospital in Australia and Hunterian Professor of the Royal College of Surgeons of England. Reprint requests: J. J. Hueston, M.D., 89 Royal Parade, Parkville, Victoria, 3052, Australia.

tically changing the skin (dermofasciectomy) has been advocated now for more than a quarter of a century and has been used in more than 300 fingers without recurrence within the grafted areas. Iselin has confirmed this therapeutic approach in a large series awaiting publication, and a recent review from Varian's unit in Derby, England, showed no recurrence beneath Wolfe grafts used in 41 of a series of 123 fasciectomies.

Nevertheless some skepticism, mainly directed to the need for skin replacement, still exists among conventional hand surgeons. Two factors may be involved. First, a vast range of difference exists in the incidence and severity of Dupuytren's contracture in different areas of the world. Inevitably this has produced great differences in the experience of hand surgeons in the management of the disease. Second, the extent of the surgery involved in dermofasciectomy deters some surgeons who lack confidence in the techniques of extensive skin grafting from attempting this procedure.

The incidence of Dupuytren's contracture reportedly is highest among Anglo-Saxons and least frequent in the populations of the countries bordering the Mediterranean basin (although a few blue-eyed Sicilian patients remind us of the Celtic excursions that reached that far south). The risk of recurrence, and hence the need for control by dermofasciectomy, is therefore less likely in the latter countries. That one-third of Varian's series required skin grafts reflects the strong Anglo-Saxon diathesis to Dupuytren's contracture. The disease traveled to Australia with the early colonists from Great Britain.

In view of the present state of hand surgery training, the increased technical difficulty involved in this procedure is not an acceptable reason for resistance to it. Plastic surgeons only entered hand surgery after the demonstrations by Blair and Brown in the United States and Gillies and McIndoe in England of the effectiveness of extensive skin grafting in burned hands during World War II. However, recognition of the principles of skin grafting in the hand—preparation of the wound bed, selection of the best type of graft, tailoring of the graft, proper dressing techniques and postoperative care—should by now be well incorporated into the repertoire of all hand surgeons, and fear that such extensive grafts may not take successfully should not be a deterrent to their use when they are indicated. Yet this concept of grafting in the hand prophylactically has been difficult for many surgeons to accept. Grafts forced upon them by skin loss—from trauma, burns, or ischemic necrosis—are not of their own choosing. It is necessary, however, for surgeons operating in those areas with a high incidence of Dupuytren's contracture, to assess their recurrence rates and to be prepared to advise changing the skin to prevent recurrences. The aim of dermofasciectomy is to prevent amputation.

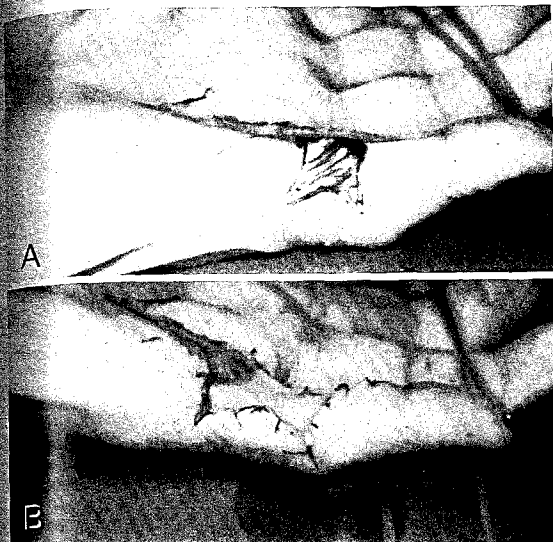


FIG. 2. (A) Recurrent Dupuytren's disease in a 45-year-old female. (B) Dermofasciectomy with full-thickness (Wolfe) graft resurfacing of proximal segment of finger.

#### PATIENT SELECTION

The sole indication for this deliberate excision of volar skin along with the Dupuytren's tissue is to prevent the recurrence of Dupuytren's contracture. Why this provides prophylaxis against recurrence is not yet known, but that should not prevent acceptance of the empirical observation that a technique exists to prevent it.

Not all patients will develop a recurrence after an adequate fasciectomy, but those who do will probably have a recurrence again after a repeat fasciectomy.<sup>3</sup> For that reason, some introduction of new skin is advisable, even as a transverse "firebreak" to prevent the linking of proximal and distal recurrences, when operating for an already established recurrence (Fig. 2A and B).

It is possible to construct a profile of those patients likely to have a recurrence by studying those who already have had one. That a Dupuy-

tren's diathesis exists and can be assessed fairly well for each patient was first expounded 20 years ago and summarized as the "prognostic factors" to look for in selecting the type of surgery for each case.<sup>10</sup> In an Anglo-Saxon patient such factors as early age of onset, the presence of ectopic deposits on knuckles or soles, diffuse skin involvement in the digits, alcoholism, and a strong family history are all indications that there may be recurrence. Dermofasciectomy then may be advised as a primary prophylaxis, or at least discussed as the secondary procedure of choice if there is a recurrence.

#### TECHNIQUE

Cross finger flaps are contraindicated in this situation, for it is precisely that young patient with an aggressive form of Dupuytren's contracture that extension of the disease can be expected. This occurred in the case of the first dermofasciectomy related at the outset of this paper. If extension—that is, the appearance of new Dupuytren's deposits in areas not previously operated upon—should occur later in the adjacent finger but the dorsal integument of that finger has already been transferred to resurface a dermofasciectomy defect on its neighbor, there is a great risk of major circulatory impairment in the newly involved digit. There is far less risk if volar fasciectomy alone is planned, let alone a curative dermofasciectomy. Remote flap procedures—cross arm or inguinal—can be avoided by careful preservation of the wound bed. Full thickness free grafts are the rule. The use of split skin grafts on the volar aspect of the digit in the correction of flexion deformities is, of course, to be avoided.

Because of the need for full thickness free skin grafts, it is essential to preserve intact a layer of viable tissue over the flexor tendons. Only from such a bed can a free graft be expected to regain an adequate circulatory flow.

When performing a *primary* dermofasciectomy, there is no problem in preserving the fibrous flexor sheath intact, for it is never directly involved in the fibroplastic process of Dupuytren's contracture primarily, and full extension to the limits imposed by interphalangeal joint fixation can be obtained. The relative ease of the dissection of a virgin finger compared with that of a recurred finger lends weight to the value of seeking out those patients for primary dermofasciectomy.

In contrast, a *secondary* dermofasciectomy for recurrent Dupuytren's disease can be among the most tedious procedures in surgery. Longitudinal exposure allows safe identification of the neurovascular bundles in the palm where the nerve always lies along the anterior border of the lumbrical muscle. On entering the fingers, however, even using magnification, the utmost difficulty can be encountered in trying to preserve the

digital nerves intact, and even more so the digital arteries which are quite obvious in a virgin primary dissection. The fibrous flexor sheath is often directly involved by the Dupuytren's tissue in recurrent cases as a consequence of its exposure during the first fasciectomy. Extreme care is required to avoid exposing the flexor tendons. Indeed, it is preferable to leave a thin layer of recurrent Dupuytren's tissue over the flexor tendons than to attempt to free skin graft directly onto exposed tendons. This need to retain an adequate bed may limit the degree of correction obtained, but if slightly more skin is introduced than is necessary for the operation defect, subsequent improvement in interphalangeal joint extension can be expected.

A major sheath defect can be covered by a local flap of the digital integument, which is not discarded immediately along with the fascia but retained until it is clear that it will not be needed for this purpose. An example of such a local flap and Wolfe graft combination can be seen in Figure 3.



FIG. 3. A small transposition flap has been used to close exposed flexor tendons at PIP level in combination with more extensive Wolfe graft resurfacing for recurrent Dupuytren's contracture.

The lateral margins of the skin excision, and hence of the graft, should be extended to the midlateral "stationary" line of the finger to prevent subsequent scar contraction anterior to the axis of the interphalangeal joints, producing further flexion deformity. This can mimic recurrence (Fig. 4). Additional technical details for this procedure can be found in previous publications on this subject.<sup>7,11-13</sup>

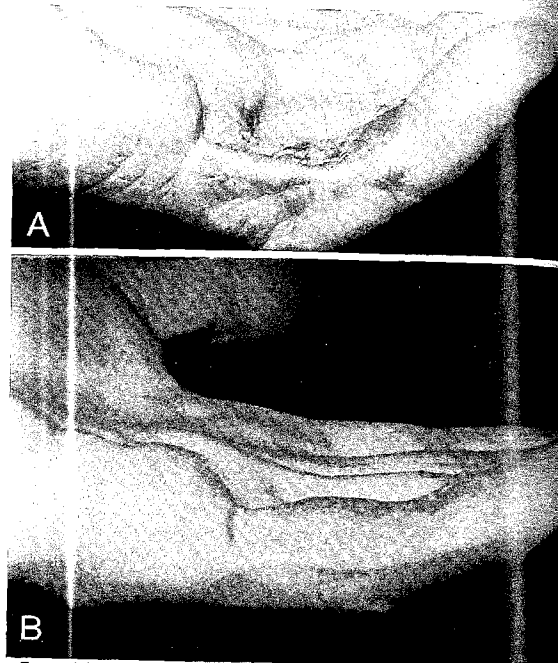


FIG. 4. (A) Marginal scar contracture and true recurrence below retained lateral digital skin. There is no recurrence beneath the Wolfe graft (showing unusual hair growth). (B) Better planning to place the graft margin more posteriorly would have both prevented scar flexion contracture and removed the lateral skin beneath which the recurrence has appeared (another case).

The results of a properly selected and performed dermofasciectomy should include the retention of a digit otherwise threatened by amputation, freedom of recurrence in the grafted area, interphalangeal joint mobility equal at least to preoperative flexion, and skin cover of the same quality as that of the donor site selected. Two to three months is required for the recovery of protective sensation. However, this quality, although permanently less than that of the normal volar digital skin, will improve over a period of one year. Frictional changes of thickening, although not true callosities, also will develop with use. Pigmentation and fissuring of the grafted areas occur as they do in any other well-used volar skin grafts, but seem to be less when inner upper-arm skin is used rather than abdominal skin. Abdominal skin also is more likely to grow hair.

Finally, my observation that free grafts will take successfully even over a thin layer of obviously involved Dupuytren's tissue can be extended to the observation that such retained and overgrafted Dupuytren's tissue not only does not progress, but actually regresses. It is for that reason that the controlling role of the skin overlying Dupuytren's disease assumes all the excitement of the late stages of a mystery novel.<sup>14</sup> Rudolph's work suggests that the final unveiling of the culprit causing the contracture is close.<sup>15,16</sup>

#### REFERENCES

- HUESTON, JT: Digital Wolfe grafts for recurrent Dupuytren's contracture, *Plast Reconstr Surg* 29:342, 1962.
- LEXER, E: Die Gesamte Wiederherstellungschirurgie Zugleich, 2nd ed, Vol. 2. Leipzig, Barth, 1931.
- PULACHS, P, MIR Y MIR, L: Consideraciones sobre la enfermedad da Dupuytren. *Folia Clinica Internat* (Barcelona) 2:8, 1952.
- GORDON, S: Dupuytren's contracture, the use of free skin grafts in treatment. In Transactions of the Third International Congress of Plastic Surgery, 1963, Washington DC. Amsterdam, Excerpta Medica Foundation, 1964.
- GONZALES, R: Open fasciotomy and full-thickness skin graft. In Hueston, JT, Tubiana, R (eds), Dupuytren's Disease. Edinburgh, London, Churchill Livingstone, 1974.
- TONKIN, MA, BURKE, FD, VARIAN, JPW: Dupuytren's contracture, a comparative study of fasciectomy and dermofasciectomy in one hundred patients. *J Hand Surg* 9B:156-162, 1984.
- HUESTON, JT: Dupuytren's Contracture. In Flynn, JE (ed), Hand Surgery, 3rd ed. Baltimore, Williams & Wilkins, 1981.
- HUESTON, JT: Recurrent Dupuytren's contracture. *Plast Reconstr Surg* 31:66, 1963.
- HUESTON, JT: Dupuytren's Contracture. Edinburgh, E & S Livingstone, 1963.
- HUESTON, JT: Prognosis as a guide to the timing and extent of surgery in Dupuytren's contracture. In Maladie de Dupuytren. Paris, Exposition Scientifique Française, 1966.
- HUESTON, JT: The control of recurrent Dupuytren's contracture by skin replacement. *Br J Plast Surg* 22:152-156, 1969.
- HUESTON, JT: Dupuytren's contracture. In Pulvertaft, R (ed), Operative Surgery, 3rd ed, Vol. 7. London, Butterworth, 1977.

13. HUESTON, J.T.: Dupuytren's contracture. In Converse, JM (ed), *Plastic and Reconstructive Surgery*. Baltimore, WB Saunders, 1979.
14. HUESTON, J.T.: Management of Dupuytren's disease. In Boswick, J (ed), *Current Concepts in Hand Surgery*. Philadelphia, Lea & Febiger, 1983.
15. RUDOLPH, R.: Inhibition of myofibroblasts by skin grafts. *Plast Reconstr Surg* 63:478, 1979.
16. VANDE BERG, JS, RUDOLPH, R, GELBERMAN, R, ET AL: Ultrastructural relationship of skin to nodule and cord in Dupuytren's contracture. *Plast Reconstr Surg* 69:835, 1982.

## Resection Arthroplasty with Swanson's Implant for Posttraumatic Stiffness of Proximal Interphalangeal Joints

FRANÇOIS ISELIN, M.D., AND GERARD PRADET, M.D.

*Summary: Proximal interphalangeal joint resection arthroplasty with Swanson's implant should be considered as a simplified new hinge joint with a simplified shorter but isometric extensor system which will work if the flexor system is intact. The procedure is indicated in cases of severe, ill-tolerated, fixed joint contractures. Functional improvement with restoration of some range of motion can be expected. Patients should be aware that they will not regain a complete range of motion at the PIP joint, there will be limited involvement of the distal interphalangeal joint, and there may be some discomfort in cold weather. The procedure is not recommended for patients with a high risk of postoperative dystrophy, on workmen's compensation, or unable to understand the goals and limitations of a joint resection arthroplasty.*

THE USUAL solution to proximal interphalangeal (PIP) joint fixed stiffness is either to ignore it if the position is acceptable, or to restore a better position by means of an arthrodesis. Actually, since except for the index finger no position of PIP arthrodesis is really satisfying, we always attempt to restore some mobility in these problem cases.<sup>1</sup>

We have found our attempts at joint release (arthrolysis) to be ineffective as a means of treating fixed stiffness. Posttraumatic stiff joints are always fibrotic, and even extensive arthrolysis cannot recreate soft structures from scar tissue.<sup>2,3</sup> Only bone resection can restore mobility. Stability should be obtained from the existing connective tissue to the extent that it can resist lateral forces while at the same time allowing the necessary flexion-extension mobility.

Swanson's "silastic" implants are a mandatory part of a joint resection because they mechanically keep apart and align the bone ends. Moreover, biologically, the silicone induces around the implant a new joint capsule

*Dr. François Iselin is Director of Hand Surgery Service, Hôpital de Nanterre, and Western Paris Hand Emergency Service, Paris, France. Dr. Gerard Pradet is Attending Surgeon, Hand Surgery Service, Hôpital de Nanterre, and Western Paris Hand Emergency Service, Paris, France. Reprint requests: Dr. François Iselin, 1, rue Auguste Vacquerie, 75116 Paris, France.*