

Rheumatoid Arthritis and Dupuytren's Contracture

Ghazi M. Rayan, M.D.

Oklahoma City, Okla.

Of four patients with rheumatoid arthritis and Dupuytren's contracture, two were not aware of the presence of Dupuytren's contracture. When both diseases coexist, the presence of rheumatoid hand deformities, especially flexion and ulnar deviation of the metacarpophalangeal joints, may mask the flexion deformity caused by Dupuytren's contracture. Careful clinical examination should rule out the presence of a pathologic fascial cord. When reconstructive surgery is indicated for the rheumatoid hand in the presence of advanced Dupuytren's contracture, staged surgery would be appropriate and reconstruction of Dupuytren's contracture should precede other surgery.

The coexistence of rheumatoid arthritis and Dupuytren's contracture is not common. In a reported series of 100 consecutive patients with Dupuytren's contracture by McFarlane and Jamieson,⁴ there were only four patients with rheumatoid arthritis. In the presence of rheumatoid hand deformities, early or even active stage Dupuytren's contracture may be missed. The purpose of this paper is to report four patients with rheumatoid arthritis and Dupuytren's contracture. Two of these patients were not aware of the presence of Dupuytren's contracture.

CASE REPORTS

Case 1

A 75-year-old white diabetic woman with a 3-year history of rheumatoid arthritis presented with rapid onset of deformities of both hands and swelling and pain in the metacarpophalangeal (MP) joints of the index, long, ring, and little fingers which interfered with her activities of daily living. There was no triggering of the fingers. On examination, she had marked ulnar deviation and mild flexion deformity of the metacarpophalangeal joints of all fingers (Fig. 1, *left*). Radiographic examination revealed volar subluxa-

tion of the metacarpophalangeal joints, narrowing of the interphalangeal joint spaces, and marginal erosions plus collapse deformity of both thumbs. Resection implant arthroplasty of the right index, long, ring, and little fingers and arthrodesis of the thumb metacarpophalangeal joint were performed. Postoperatively, the patient's hand function has improved and she had correction of her ulnar drift and flexion deformities at the metacarpophalangeal joints except for residual flexion deformity of the metacarpophalangeal joint of the ring finger of about 10 degrees. Careful examination revealed the presence of a small pretendinous cord in the palm extending to the base of the ring finger (Fig. 1, *right*). It was explained to the patient that partial fasciectomy may be indicated later if the flexion deformity increased.

Case 2

A 69-year-old white woman with a 4-year history of rheumatoid arthritis was seen in the hand clinic because of a severe flexion contracture of the left ring finger that progressed over several years. Physical examination revealed a markedly flexed ring finger that was fixed in 90 degrees of flexion at the metacarpophalangeal joint and 90 degrees of flexion at the proximal interphalangeal (PIP) joint. The pulp of the finger was resting against the palm, and passive extension of the finger hyperextended the pulp at the distal interphalangeal joint (Fig. 2). A thick pretendinous fascial cord could be palpated in the palm. Skin maceration was present on the palmar aspect of the finger. Mild flexion and ulnar deviation deformities of the metacarpophalangeal joints of both hands were observed.

A staged reconstructive surgery was carried out. The first stage was subcutaneous fasciotomy and release of the cord using local anesthetic followed by a program of therapy and splinting. This improved the deformity partially. Two months later, limited fasciectomy with excision of pathologically proven pretendinous and central cords was carried out, release of the proximal interphalangeal joint contracture, and Z-lengthening of the shortened flexor digitorum superficialis at the wrist were necessary to improve the deformity. Postoperatively, the patient had residual flexion of 45 degrees at the proximal interphalangeal joint and 35 degrees at the metacarpophalangeal joint.

From the Section of Hand Surgery, Orthopedic Surgery Department, at the University of Oklahoma Health Sciences Center and Hand/Microsurgery Center of Baptist Hospital. Received for publication January 5, 1987; revised February 2, 1987.

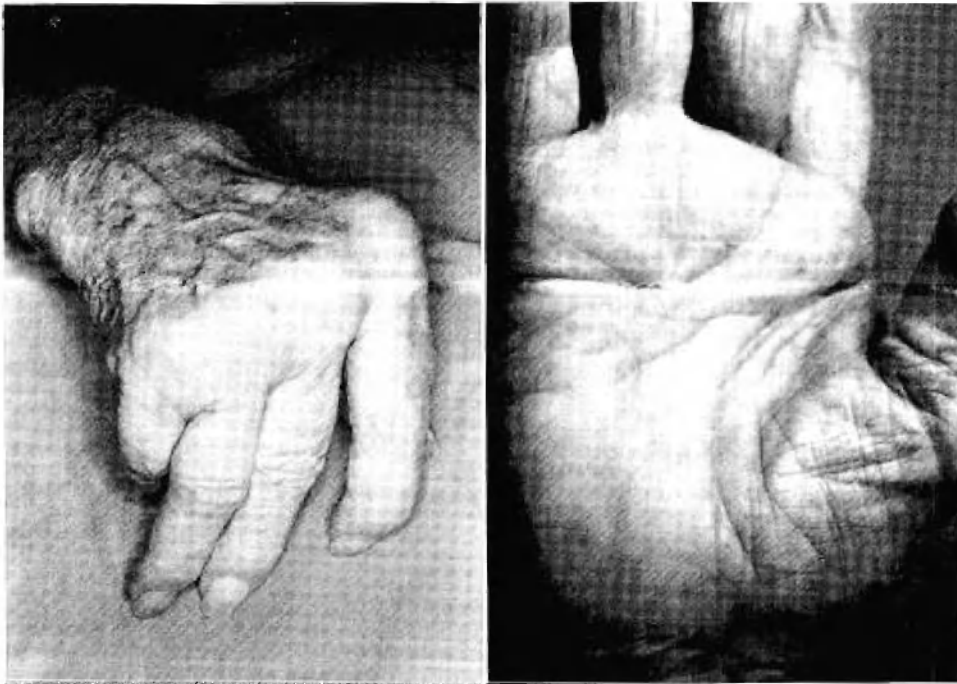


FIG. 1. The appearance of the right hand before (*left*) and following (*right*) resection implant arthroplasty of the fingers. Dimpling of the skin overlying a pretendinous cord that is connected to the base of the ring finger is seen.

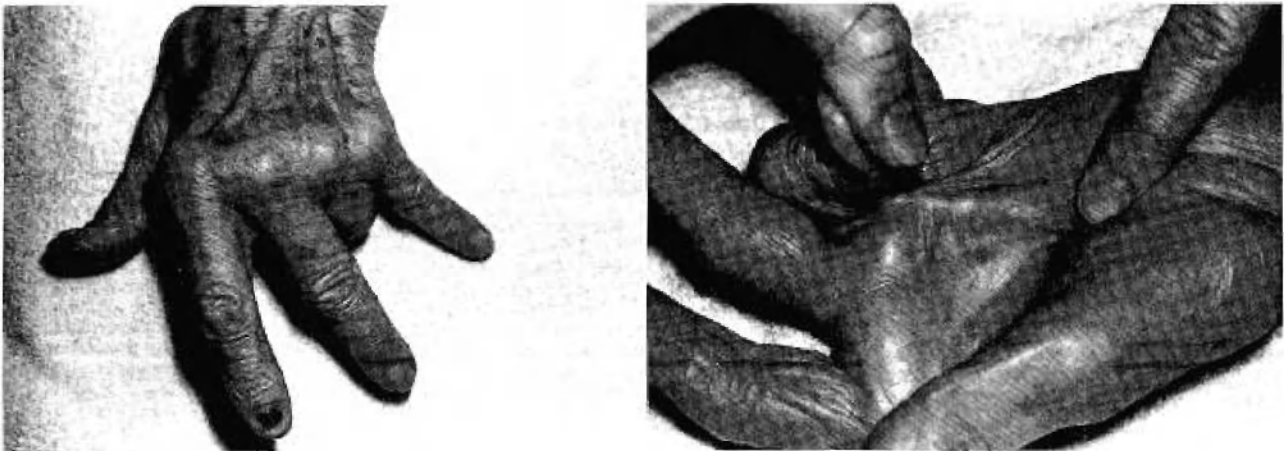


FIG. 2. The left hand showing ulnar deviation of the fingers at the metacarpophalangeal joints and marked flexion deformity of the ring finger at the metacarpophalangeal and interphalangeal joints due to a pretendinous and central cords.

Case 3

A 74-year-old man was referred by the arthritis clinic because of progressive Dupuytren's contracture of both hands for the last 2 years with more involvement and pain in the left hand, especially with ambulation. The past history was remarkable for rheumatoid arthritis, rheumatoid pulmonary nodule, diabetes, and left traumatic below-knee amputation. The patient could not tolerate his below-knee prosthesis and often used crutches and occasionally a wheelchair for ambulation. Physical examination revealed mild ulnar deviation of the metacarpophalangeal joints of both hands with more involvement of the left ring and little fingers. Two palpable palmar cords were identified extend-

ing to the bases of the ring and little fingers (Fig. 3). Rheumatoid nodules were present over the extensor surfaces of both elbows. Because of the pain in the palm during ambulation with crutches, partial fasciectomy with excision of pretendinous cords was performed. Pathologic examination confirms the diagnosis of Dupuytren's diseased fascia with no evidence of rheumatoid nodules in the specimen.

Case 4

A 70-year-old man was seen for deformities in both hands with functional impairment secondary to rheumatoid disease. The past history was remarkable for chronic emphysema and total-knee arthroplasty. Physical examination re-

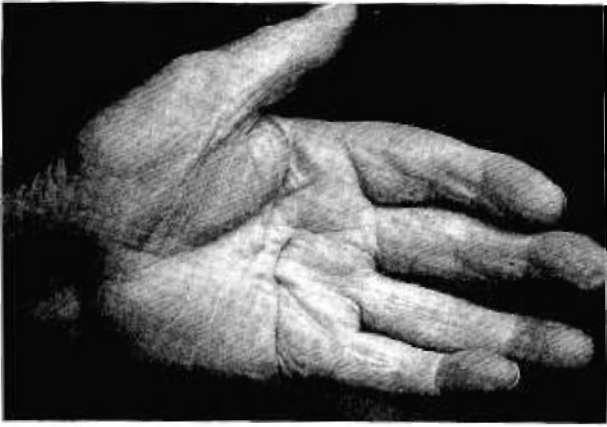

FIG. 3. The left hand showing mild ulnar deviation of the fingers. On examination, nodular thickening of the palmar fascia with two palpable palmar cords were observed.

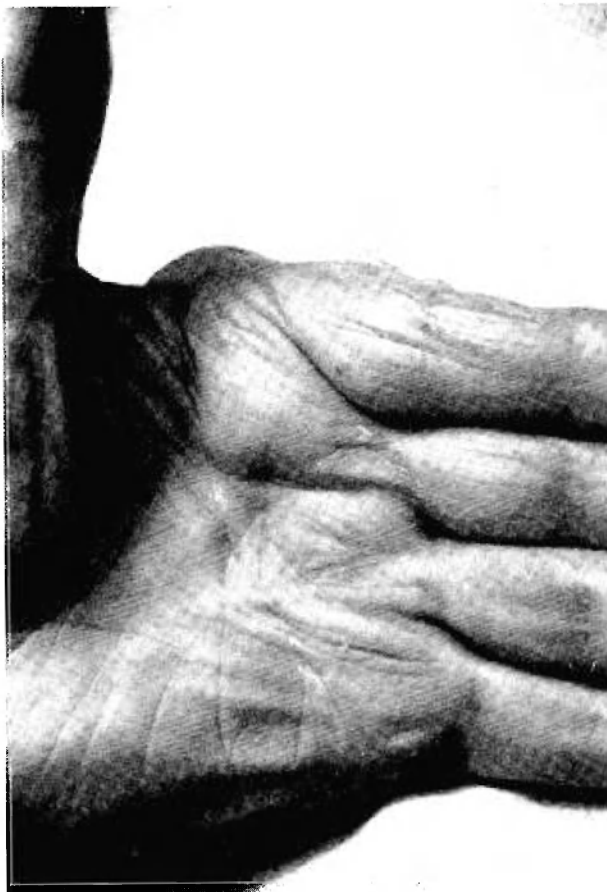

FIG. 4. Ulnar deviation of the fingers at the metacarpophalangeal joints is shown along with a palmar pretendinous cord involving the left ring finger.

vealed ulnar deviation deformity of the metacarpophalangeal joints of both hands. Limitation of passive extension was present especially in the left ring finger metacarpophalangeal joint. Careful examination of the palm revealed the presence of a pretendinous cord on the left side (Fig. 4) and a nodule in the palmar fascia of the right hand. Radiographic

examination revealed compressive erosions at the bases of the proximal phalanges with palmar dislocation and narrowing of the joint spaces at the proximal interphalangeal joints. Partial fasciectomy including the pretendinous cord was performed. Pathologic examination confirmed the diagnosis of Dupuytren's fascia. Full passive extension of the ring finger metacarpophalangeal joint was achieved. Eight weeks later, resection implant arthroplasty of the index, long, ring, and little fingers with soft-tissue reconstruction was performed. The patient's deformities and hand function have improved postoperatively.

DISCUSSION

Rheumatoid arthritis is more common in females than in males, whereas Dupuytren's contracture occurs 9 to 10 times more frequently in males than in females. Two of the four patients in this report are females. Perhaps in the presence of Dupuytren's contracture and rheumatoid arthritis more females are affected than in Dupuytren's contracture alone. Two of the patients were not aware of the coexistence of Dupuytren's contracture. This was masked by the rheumatoid flexion deformity and ulnar drift of the metacarpophalangeal joints. One patient's contracture was manifested following rheumatoid reconstructive surgery as a result of the residual mild flexion of the involved digit caused by the palmar cord. The other patient's contracture was detected during the initial visit.

Dupuytren's palmar nodules, when present in such cases, should be differentiated from rheumatoid nodules of the flexor tendon in the palm and from secondary reactionary nodules, which were described by Flatt.² Rheumatoid nodules may be associated with triggering of the finger or restriction of active flexion. Palpation of the palm between the distal palmar crease and the middle of the proximal phalanx helps to identify whether the nodule lies in the area of the palm or in the area of the superficial tendon decussation.³ Dupuytren's nodules occur most frequently at the normal sites of fascial adherence to the skin, i.e., just distal to the metacarpophalangeal and proximal interphalangeal joints.⁴ The presence of trigger finger, on the other hand, may be associated incidentally with the palmar nodule of Dupuytren's contracture without rheumatoid arthritis. Seven of 38 patients in Chiu and McFarlane's series were in this category.¹

In order to minimize postoperative complications, Nissenbaum and Kleinert⁵ advised against surgically treating Dupuytren's contracture and releasing the carpal tunnel at the same time when Dupuytren's contracture and compression neuropathy of the median nerve coexist. Instead,

they recommended treating Dupuytren's contracture first. However, when the symptoms of carpal tunnel syndrome are severe, they recommended releasing the carpal tunnel first. None of the four patients in McFarlane's series who had Dupuytren's contracture and rheumatoid arthritis was treated surgically because of either early contracture or because the general condition contraindicated any treatment. However, when rheumatoid arthritis and advanced Dupuytren's contracture coexist and surgical treatment is required for both, staging the treatment would be appropriate. The treatment of Dupuytren's contracture should precede any rheumatoid reconstructive surgery, especially metacarpophalangeal arthroplasty. If rheumatoid arthritis is treated first, residual flexion contracture by the pathologic cord may occur and interfere with rehabilitation of the hand. On the other hand, when Dupuytren's contracture is not severe, rheumatoid reconstructive surgery and Dupuytren's cord resection can be performed under the same anesthesia.

In summary, when both diseases coexist, the presence of rheumatoid hand deformities, espe-

cially flexion and ulnar deviation of the metacarpophalangeal joints, may mask the flexion deformity caused by Dupuytren's contracture. Hence, the latter disease may be missed. Careful clinical examination of patients with rheumatoid arthritis should rule out the presence of Dupuytren's contracture.

Ghazi M. Rayan, M.D.

3433 NW 56th

Suite 850

Oklahoma City, Okla. 73112

REFERENCES

1. Chiu, H. F., and McFarlane, R. M. Pathogenesis of Dupuytren's contracture: A correlative clinical-pathological study. *J. Hand Surg.* 3: 1, 1978.
2. Flatt, A. E. *Care of the Arthritic Hand*, 4th Ed. St. Louis: Mosby, 1983. P. 106.
3. Flatt, A. E. Correction of Arthritic Deformities of the Hand. In D. J. McCarthy (Ed.), *Arthritis and Allied Conditions: A Textbook of Rheumatology*, 3d Ed. Philadelphia: Lea & Febiger, 1985. P. 728.
4. McFarlane, R. M., and Jamieson, W. G. Dupuytren's contracture. *J. Bone Joint Surg.* 48A: 1095, 1966.
5. Nissenbaum, M., and Kleinert, H. Treatment considerations in carpal tunnel syndrome with coexisting Dupuytren's contracture. *J. Hand Surg.* 5: 544, 1980.