

The TEC treatment (continuous extension technique) for severe Dupuytren's contracture of the fingers

A. MESSINA, J. MESSINA

SUMMARY : TEC used for 2 weeks preoperatively has eliminated finger amputation in severe cases of Dupuytren's disease. It must be continuous to be effective. The apparatus and technique are described.

Ann Hand Surg, 1991, 10, n° 3, 247-250.

KEY-WORDS : Dupuytren's Disease. — Continuous Extension Technique (T.E.C.) in severe Dupuytren's contracture.

« The patient produces the disease ; the Surgeon attempts to control it » J. Hueston (1966).

A technique is presented to correct pre-operatively severe, often recurrent, flexion deformities in Dupuytren's disease. The need to amputate has thus been radically reduced, almost eliminated.

The principle of TEC is the use of *continuous* passive traction sustained over 2, 3 or 4 weeks at a slow rate, quite painlessly, until the MP and IP flexion deformities are corrected. Fasciectomy is then performed in the usual way, but much more easily. The TEC is a preoperative procedure to facilitate the fasciectomy.

TECHNIQUE

Two self-drilling threaded pins are inserted into the ulnar border of the hand to penetrate *both* the fourth and fifth metacarpals transversally (fig. 1 a and b). This is checked by-X-ray. A strong Kirschner wire is then inserted across the distal

third of the proximal or middle phalanx and is bent to form a traction loop. This in turn is connected to a long threaded screw. These three fixed skeletal metal insertions are then attached to the TEC frame (fig. 2). There is a small turnbuckle on the long screw to the phalanx and it is by daily turning of this turnbuckle that traction into extension is transmitted to the flexed digit (fig. 3 a, b, c). Before leaving hospital the next day, the patient is instructed how to turn the turnbuckle with a small spanner. One millimeter each day is gained in extension, but after 3 or 4 days this can be increased to 2 or 3 millimeters of extension each day, provided there is no pain.

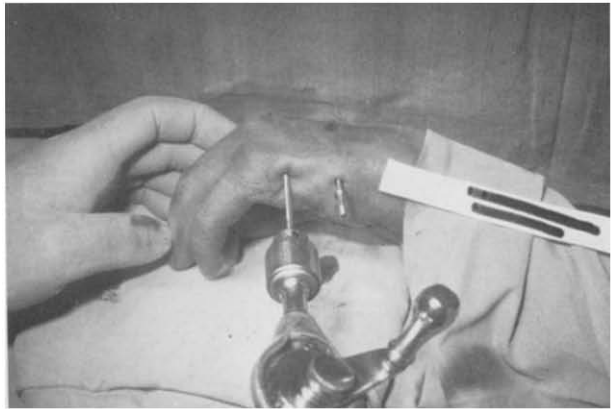
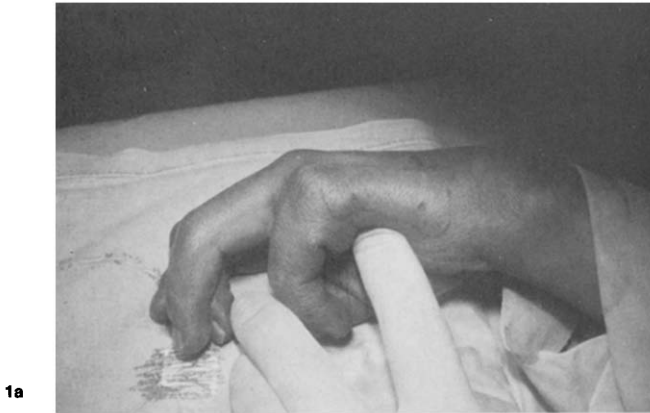

Fig. 1. — a) By flexing the little and the ring fingers, we stabilize and line up the 4th and 5th metacarpal bones, which represent the mobile ulnar section of the hand. b) The self-drilling pins are inserted transversely through both the metacarpal shafts. In this way a stable and painless support for the setting-up of the TEC device is obtained.

Fig. 1 — a) En maintenant l'annulaire et l'auriculaire en flexion, on stabilise et on aligne les 4^e et 5^e métacarpiens, qui représentent la portion ulnaire mobile de la main. b) Les broches auto-taraudeuses sont insérées transversalement à travers les deux diaphyses métacarpiennes. On obtient ainsi un support stable et indolore pour la mise en place du dispositif TEC.

Fig. 1. — a) Manteniendo el anular y el meñique en flexión, se estabiliza y alinea el cuarto y quinto metacarpianos, que representan la porción cubital móvil de la mano. b) Los broches auto-tarrajantes se posicionan transversalmente a través de las dos diáfisis metacarpianas. Obteniéndose así un soporte estable e indoloro para la colocación del dispositivo TEC.




Fig. 2. — Last prototype (190 g) to extend retracted fingers in severe Dupuytren contracture by TEC (Continuous Extension Technique).

Fig. 2. — Le dernier prototype (190 g) utilisé pour étendre des doigts rétractés par une forme grave de maladie de Dupuytren (TEC).

Fig. 2. — El último prototipo (190 g) utilizado para extender los dedos retractados por una forma severa de la enfermedad de Dupuytren (TEC).

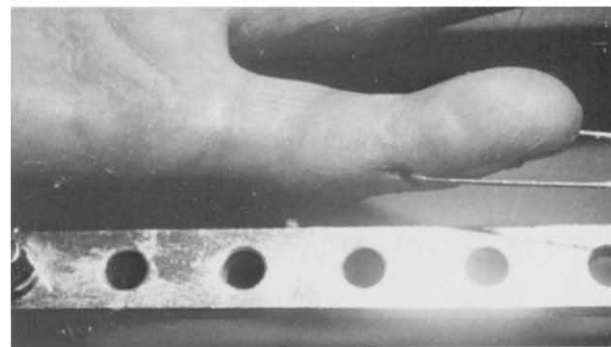
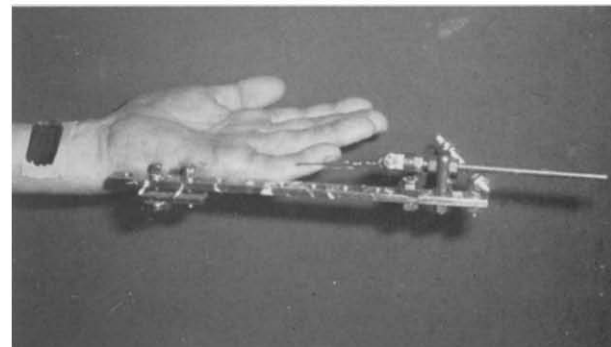
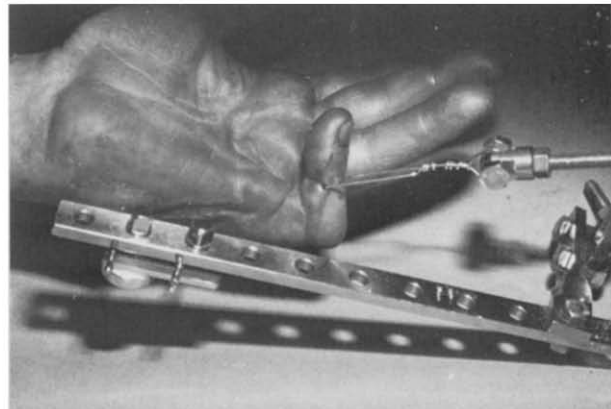


Fig. 3 a, b, c. — A 40-year old man whose left little finger has primary unoperated Dupuytren disease; I.P.P. joint retracted in flexion contracture at 100°. T.E.C. by continuous traction (2 mm distributed 4 times a day : 8 a.m. ; 12 p.m. ; 4 p.m. ; 8 p.m.) produced full clinical correction in 3 weeks.


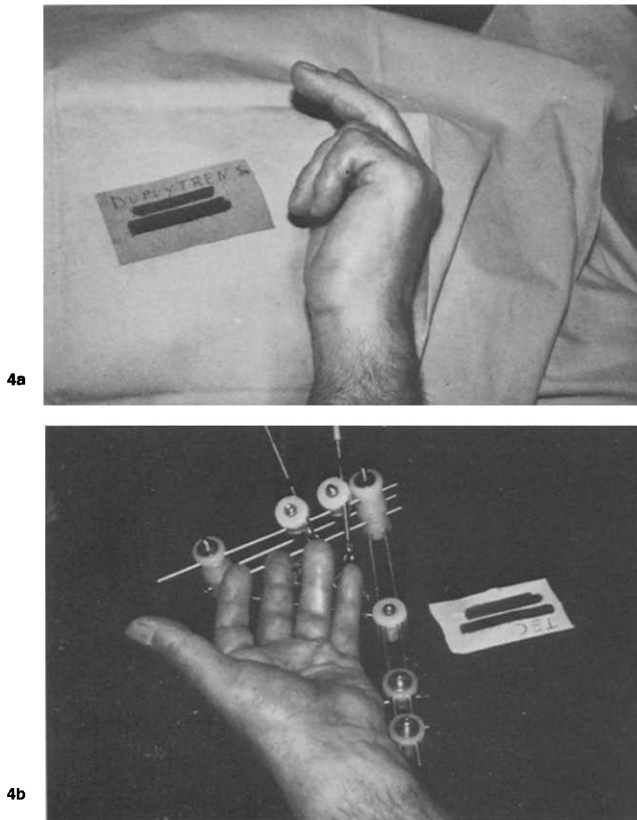


Fig. 4. — a) A very severe recurrence of Dupuytren's disease of the 4th and 5th fingers of the right hand two years after an operation in another hospital. Severe contracture of the fingers and interdigital mycotic intertrigo. The patient asked for amputation. b) Incomplete finger extension obtained by T.E.C. which was then followed by partial digito-fasciectomy without skin plastic surgery or joint release. c, d) Active flexion and extension of the fingers after 5 months.

Fig. 4. — a) Rediciva severa de una enfermedad de Dupuytren del 4º y 5º dedo de la mano derecha, dos años después de una intervención efectuada en otro centro. Retracción severa de los dedos e intertrigo micótico interdigital. El paciente solicitó la amputación. b) Extensión incompleta de los dedos obtenida mediante TEC, completada por una fasciotomía digital parcial sin plastia cutánea, ni artroólisis. c, d) Flexión y extensión activas de los dedos, a 5 meses.

Fig. 4. — a) Récidive grave de maladie de Dupuytren des 4^e et 5^e doigts de la main droite, à deux ans d'une intervention effectuée ailleurs. Rétracción importante des doigts et intertrigo mycotique interdigital. Le patient a réclaté l'amputation. b) Extension incomplète des doigts obtenue par TEC, complétée par une fascièctomie digitale partielle sans plastie cutanée, ni arthrolyse. c, d) Flexion et extension actives des doigts, à 5 mois.

Over the next 2 or 3 weeks the patient attends for assessment of the progressive IP extension, any necessary adjustment of apparatus and to confirm absence of infection. Usually, complete or almost complete extension is painlessly achieved in 2 or 3 weeks. The apparatus is then discarded, the pins removed, and surgical fasciectomy is performed.




Fig. 3 a, b, c. — Patient de 40 ans dont l'auriculaire gauche présente une rétraction de Dupuytren non opérée. L'articulation IPP est en flexion à 100°. Grâce à la TEC par traction continue (2 mm répartis en 4 fois par jour : 8 h, 12 h, 16 h, et 20 h) une correction clinique totale a été obtenue en 3 semaines.

Fig. 3 a, b, c. — Paciente de 40 años cuyo meñique izquierdo presenta una retracción de Dupuytren no operada. La articulación IFP presenta una flexión de 100°. Gracias a la TEC mediante tracción continua (2 mm distribuidos 4 veces por día : 8 h, 12 h, 16 h, 24 h) se obtuvo una corrección clínica total en 3 semanas.

DISCUSSION

At present it is not possible to explain the precise biological mechanism by which the contraction process is thus reversed by TEC. There is no macroscopic evidence of tissue rupture or haemorrhages at operation. The previous firm prominent Dupuytren's bands are found to be reduced to soft fibrous ribbons which are removed at fasciectomy. If operation is delayed one or two weeks the bands begin to show again and the contraction begins to

recur very rapidly. This is why physiotherapy for restoring joint flexion is now postponed until just after the fasciectomy operation.

In 5 years we have treated 30 hands including severe recurrent Dupuytren's disease (fig. 4 a,b) with generally good results (fig. 4 c,d). We realize this is a revolutionary technique and we have restricted its use to only severe deformities. The slow traction eliminates the risk of digital artery traction injury in a sudden surgical straightening. The often macerated skin and intertrigo has cleared up before surgery, lessening infection.

The interphalangeal joints are not touched, just stretched. Reduced full final flexion is not uncommon and one volar plate rupture occurred. But these joint sequelae are deemed far more acceptable than amputation.

PS. — Article edited and summarized by J. Hueston.

REFERENCES

1. MESSINA A. — La TEC (Tecnica di Estensione Continua) nel Morbo di Dupuytren grave. Dall'amputazione alla ricostruzione. *Riv di Chirurgia della Mano*, 1989, 26, 253-257.
2. HUESTON J.T. — La Maladie de Dupuytren. In: *Tubiana R.* Monographie du G.E.M., Ed. Paris, Expansion Scientifique Française 1966.

MESSINA A. — Traitement par TEC (technique d'extension continue). Dans les formes graves de maladie de Dupuytren.

Ann Hand Surg, 1991, 10, n° 3, 247-250.

RÉSUMÉ : La TEC utilisée pendant les deux semaines qui précèdent l'intervention a permis d'éviter l'amputation des doigts dans des cas graves de Maladie de Dupuytren. Cette technique doit être appliquée de façon continue pour être efficace. Une description de l'appareillage et de la technique est fournie.

MOTS-CLÉS : Maladie de Dupuytren. — La TEC (Technique d'Extension Continue) dans la Maladie de Dupuytren grave.

MESSINA A. — Tratamiento mediante TEC (técnica de extensión continua) en las formas severas de la enfermedad de Dupuytren.

Ann Hand Surg, 1991, 10, n° 3, 247-250.

RESUMEN : La TEC utilizada durante las 2 semanas previas a la intervención ha permitido evitar la amputación de los dedos en la forma severa de la enfermedad de Dupuytren. Esta técnica se debe aplicar permanentemente para ser eficaz. Se da una descripción de la técnica y del aparato.

PALABRAS CLAVE : Enfermedad de Dupuytren. — Técnica de extensión en la enfermedad de Dupuytren.

