

Journal of Hand Surgery (British and European Volume)

<http://jhs.sagepub.com/>

Injury to the Distal Radius as a Trigger to the Onset of Dupuytren's Disease

S. A. KELLY, F. D. BURKE and D. ELLIOT

J Hand Surg [Br] 1992 17: 225

DOI: 10.1016/0266-7681(92)90096-K

The online version of this article can be found at:

<http://jhs.sagepub.com/content/17/2/225>

Published by:



<http://www.sagepublications.com>

On behalf of:

[British Society for Surgery of the Hand](#)



[Federation of the European Societies for Surgery of the Hand](#)



Additional services and information for *Journal of Hand Surgery (British and European Volume)* can be found at:

Email Alerts: <http://jhs.sagepub.com/cgi/alerts>

Subscriptions: <http://jhs.sagepub.com/subscriptions>

Reprints: <http://www.sagepub.com/journalsReprints.nav>

Permissions: <http://www.sagepub.com/journalsPermissions.nav>

Citations: <http://jhs.sagepub.com/content/17/2/225.refs.html>

>> [Version of Record](#) - Apr 1, 1992

[What is This?](#)

INJURY TO THE DISTAL RADIUS AS A TRIGGER TO THE ONSET OF DUPUYTREN'S DISEASE

S. A. KELLY, F. D. BURKE and D. ELLIOT

From the Derbyshire Royal Infirmary, Derby and The Royal Victoria Infirmary, Newcastle-upon-Tyne

Journal of Hand Surgery (British Volume 1992) 17B: 225-229

In 1833, Goyrand presented his first paper on Dupuytren's disease to the Académie Royale de Médecine. He described and illustrated the cadaveric findings in both hands of a man who had suffered from Dupuytren's disease (Fig. 1). This paper is recognized as one of the most significant early works on the management of Dupuytren's disease. It includes a description of his variation of the palmar fasciotomy operation, already

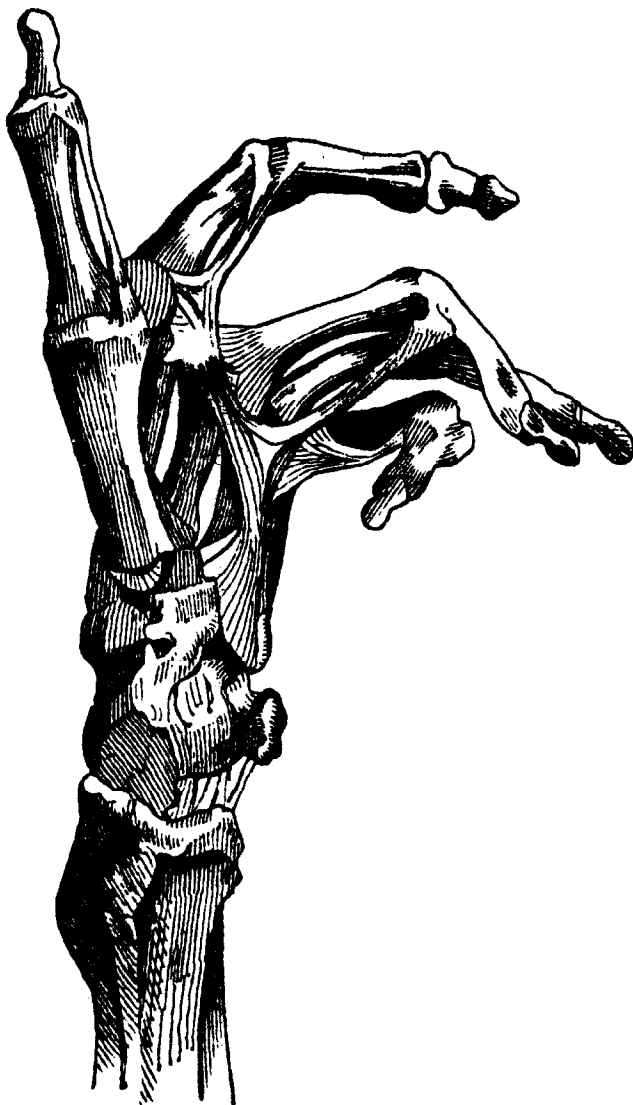

Fig. 1 Illustration of the dissection specimen presented to the Académie Royale de Médecine by Goyrand in 1833 (from Vogt, 1868).

well-known in England but recently introduced to Paris by Dupuytren (1831).

A less well-publicized, but probably more significant, contribution was made by Goyrand in the *Gazette Médicale de Paris* in 1835. He had formulated his ideas on the disease more clearly by this time. While much of this paper is concerned with the differences of opinion between Dupuytren and himself, there is a discussion of the various factors, including local hand conditions, which he considered to act as triggers to the onset of the disease (Fig. 2). He believed this condition to be partly hereditary and partly caused by work, the onset of disease being related to various triggering events, among which he included fracture of the forearm, particularly of the distal end of the radius. Goyrand pointed out that both the cadaver specimens which he had presented in his first paper to the Académie Royale had fractures of the distal radius. He apologized for the omission in not pointing this out in his first paper, excusing himself by saying that he had not been aware of this association at that time. The only remaining evidence of Goyrand's preparations is a lithograph of one of them included in a paper later in the nineteenth century (Vogt, 1868) which not only illustrates the Dupuytren's disease in the hand but also shows a deformity of the wrist indicative of a healed Colles' fracture (Fig. 1).

We now report 12 patients who developed Dupuytren's disease following Colles' fracture and present a new manifestation of this phenomenon: the development of Dupuytren's disease after the harvesting of a free vascularized radial forearm flap with bone.

Patients

In a series of 235 Colles' fractures presenting to the Derbyshire Royal Infirmary, 20 patients with 22 fractures developed Dupuytren's disease (Fig. 3). These patients were reviewed between 15 and 27 months (mean 20.7 months) after injury. The results have been reported previously (Stewart et al., 1985).

The patients included 19 women and one man and their ages ranged from 47 to 79 years (mean 67.3 years). All were Caucasian and various predisposing factors were noted: three patients had a family history of Dupuytren's disease, one was taking anticonvulsants and five patients admitted to a moderately large alcohol intake.

We attempted to recall all these patients, to examine the association between Colles' fracture and Dupuytren's disease over a longer period of follow-up. Seven patients

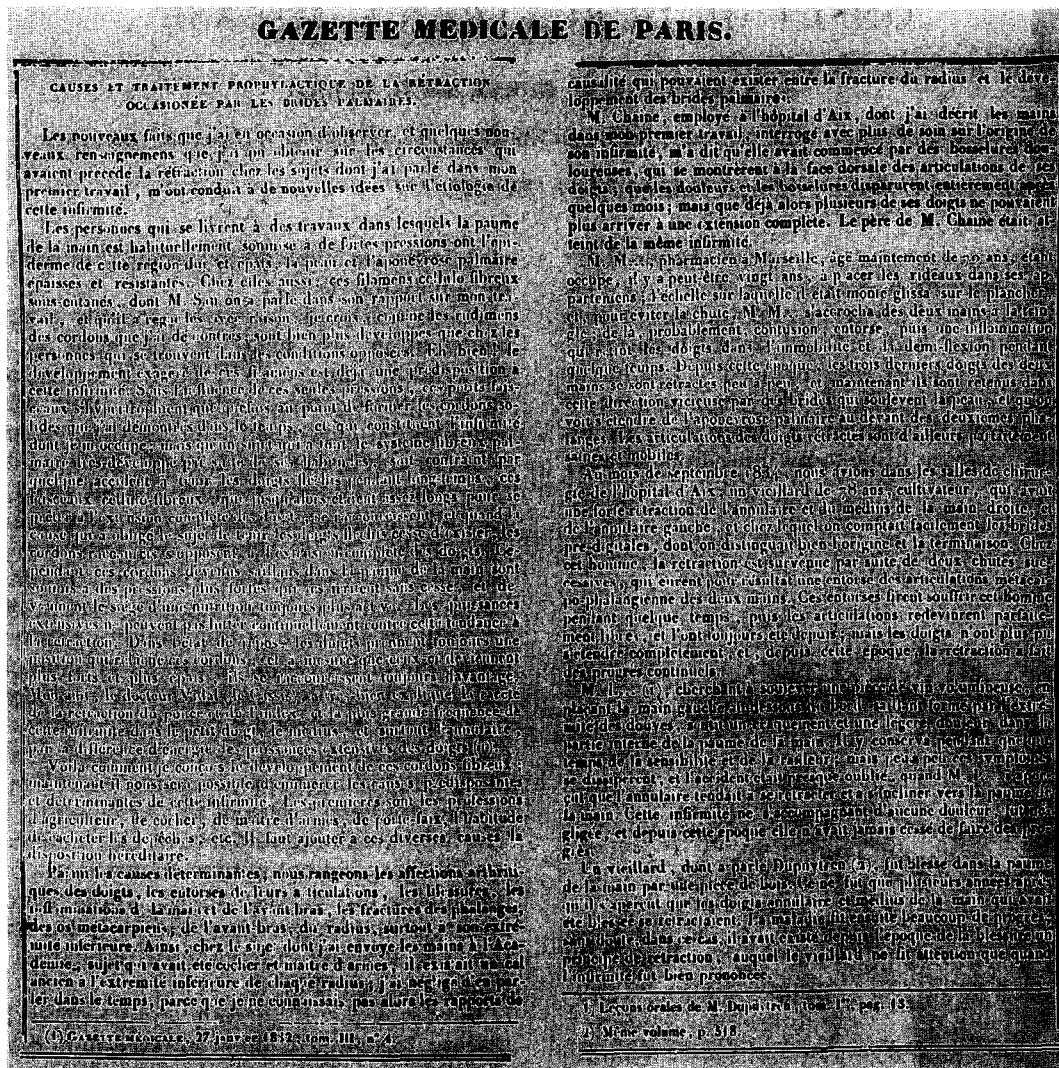


Fig. 2 Goyrand's article of 1835 from the Gazette Médicale de Paris. (The highlighted paragraphs refer to the association of Dupuytren's contracture and fracture of the distal radius.)

had died; one had moved and was unavailable for follow-up. 12 were recalled, between 84 and 98 months (mean 91 months) after the fracture. In the earlier study, two patients who had Dupuytren's disease before breaking their wrists were noted to have developed progression of the disease within months of the fracture. These patients are not included in this follow-up study.

Results

In the first study, the pathology in the hand was described in terms of palmar thickening (palpable but not visible), visible skin pits/nodules/cords and joint contractures. The distribution of the disease is shown in Table 1 and the frequency of the various manifestations of the disease in Table 2. Joint contracture occurred in five patients (25%), none of whom required surgery. 11 patients (55%)

Table 1—Distribution of disease

	No. of hands
First web	1
Palm over third ray	12
Palm over fourth ray	15
Palm over fifth ray	2
Middle finger	1
Ring finger	2
Little finger	0

had knuckle pads over the dorsum of the P.I.P. joints. None had plantar nodules.

These findings were confirmed in the 12 patients recalled for the second study. In most, the disease had been static between the first and second review. Only one patient had noticed progression of the disease. However,

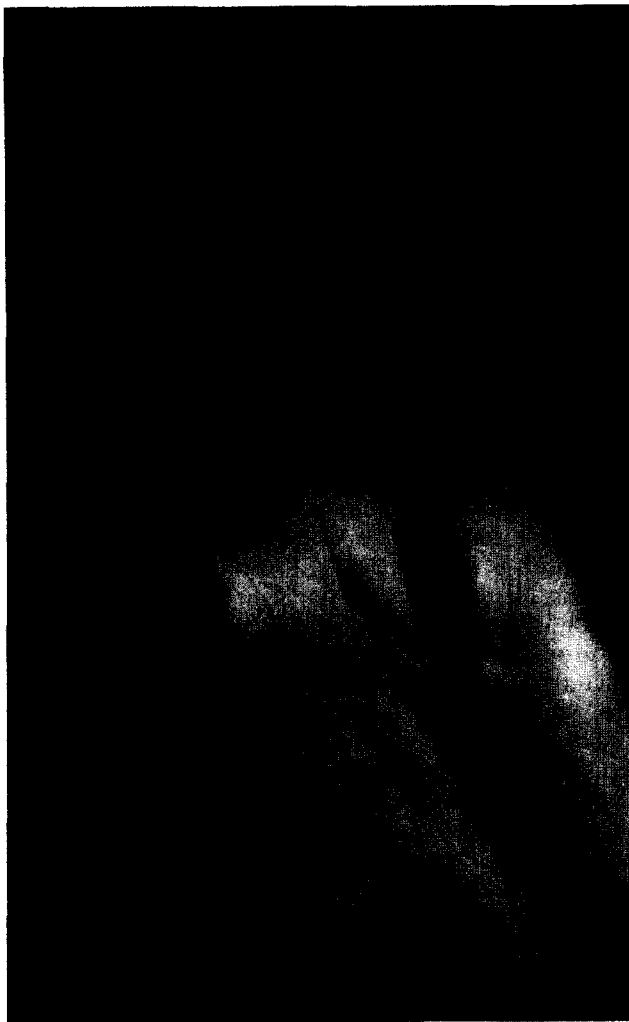

Fig. 3 Dupuytren's disease 89 months after a Colles' fracture.

seven patients with unilateral fractures, who at the time of the first review only had disease in the injured hand, had developed evidence of Dupuytren's disease in the other hand at the second review. All seven had first noticed the development of disease in the contra-lateral hand between 12 and 89 months (mean 52 months) after its appearance in the injured limb.

Case report

A 55-year-old man underwent excision by Mr T. A.

Table 2—Nature of disease

	<i>No. of hands</i>
Skin pits	10
Thickening	3
Nodules	17
Cords	4
Joint contracture	5

Piggot, of a squamous cell carcinoma from the floor of the mouth. The specimen included the central portion of the mandible. The intra-oral defect was reconstructed with a free vascularized radial forearm flap, which included a partial-thickness section of the radius to reconstitute the excised mandible. Six weeks after transfer of the flap, he was noticed to have developed a palmar cord in the line of the fourth ray (Fig. 4). This had not been present before the operation.

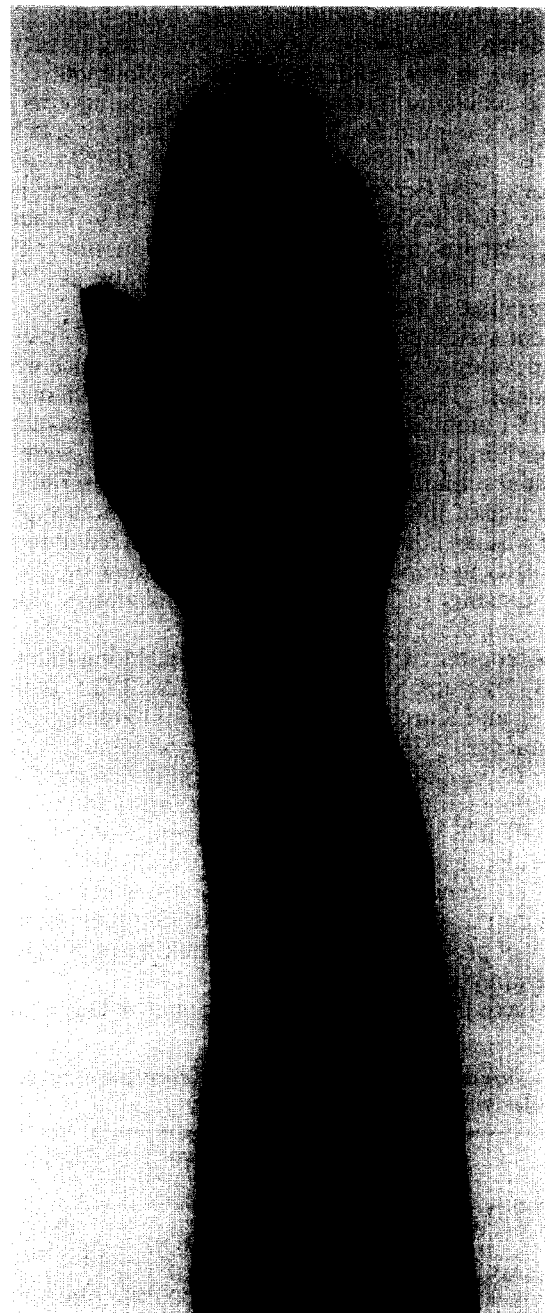

Fig. 4 Dupuytren's disease (palmar band indicated by arrows) four years after harvesting of a radial forearm osteocutaneous free flap.

Though the cord was easily palpable, there was no associated contracture of the M.P. joint of the ring finger and there has been no progression of the disease in the following four years.

Discussion

The role of acute trauma in the aetiology of Dupuytren's disease has been a subject of debate since the time of Goyrand (Skoog, 1948; Clarkson, 1961). The development of Dupuytren's disease after acute trauma was considered a separate entity and discussed as such by Anderson in 1891 and 1897. The development of the disease following fracture of the distal radius was first noted by Goyrand in 1835. Since this time, it has been reported sporadically in the literature (Rinne, 1888; Nichols, 1899; Féré and Demanche, 1903; Iversen, 1909; Scholle, 1930; Kohlmayer, 1937; Maurer, 1936; Schaefer, 1936; Bacorn and Kurtzke, 1953; Hueston, 1963; Castaing, 1964; Smaill, 1965; Cooney et al., 1980; Stewart et al., 1985; de Bruijn, 1987).

In our series of patients who suffered Colles' fracture, 9.3% developed evidence of Dupuytren's disease within six months. This was still evident after 84 to 98 months (mean 91 months) in all the patients who were available for further review. Nodules and skin pits were the commonest findings, most disease occurring in the palm in the line of the fourth ray. Flexion contracture of the finger was not common and the disease tended to remain static after its appearance. The second follow-up showed some patients to have developed Dupuytren's disease later in the other hand.

The reported incidence of palmar thickening following Colles' fracture varies from 0.2% of 2,123 patients (Bacorn and Kurtzke, 1953) to 5.4% of 110 male patients (Kohlmayer, 1935). In our study, the incidence is much higher (9.3%) and represents the largest reported series of patients with this complication of injury to the distal radius (Table 3). Other published papers do not examine the incidence of Dupuytren's disease in a series of Colles' fractures; some simply report a case or number of cases in which the association is made, while others report a history of previous Colles' fracture in a series of patients with Dupuytren's disease.

We have also observed the development of Dupuytren's

disease following harvesting of a free, vascularized radial forearm flap with bone for mandibular and intra-oral reconstruction in one patient. We believe that this is the first report of such a complication of this relatively new reconstructive technique.

The mechanism by which injury to the upper extremity may lead to the development of Dupuytren's disease has not been elucidated. Decreased hand activity and oedema following the trauma may be implicated. Hueston (1963) suggested that immobilization may be an important contributory factor in the progression of contracture in patients with established Dupuytren's disease. He described 20 patients in a series of 200 treated by himself who had progression of Dupuytren's disease following a period of decreased hand activity. In all 20, this was due to factors other than acute hand injury: the causes of immobility included change of occupation, prolonged bed rest due to illness or injury and peripheral neuropathy.

Goyrand implicated a variety of traumatic events in the onset of Dupuytren's disease in the hands of individuals already predisposed to its development by hereditary factors and occupation (Fig. 2). He included arthritis and inflammations of the hand and forearm and fractures of the fingers, metacarpals and of the forearm. He suggested that the resting, flexed position of the fingers of an injured arm offered no resistance to the tendency of the abnormal fibres of the palmar aponeurosis to contract. While the other associations have not been supported by surgeons since his time, the association of injury to the distal radius and Dupuytren's disease has been noted repeatedly over the ensuing 150 years. Although the cause of this association remains obscure, its existence appears to be beyond doubt.

Acknowledgement

We wish to thank Mr T. A. Piggot, Consultant Plastic Surgeon at the Royal Victoria Infirmary, Newcastle-upon-Tyne, for allowing us to report his case.

References

- ANDERSON, W. (1891). Lectures on contractions of the fingers and toes; their varieties, pathology and treatment. *Lancet*, 2: 57-59.
- ANDERSON, W. *The deformities of the fingers and toes*. London, J. A. Churchill, 1897: 6.
- BACORN, R. W. and KURTZKE, J. F. (1953). Colles' fracture. A study of two thousand cases from the New York State Workman's Compensation Board. *Journal of Bone and Joint Surgery*, 35A: 3: 643-658.
- BRUIJN, H. P. de (1987). Functional treatment of Colles' fracture. *Acta Orthopaedica Scandinavica, Supplement* 223: 1-95.
- CASTAING, J. (1964). Les fractures récentes de l'extrémité inférieure du radius chez l'adulte. *Revue de Chirurgie Orthopédique*, 50: 5: 581-696.
- CLARKSON, P. (1961). The aetiology of Dupuytren's disease. *Guy's Hospital Reports*, 110: 1: 52-62.
- COONEY, W. P., DOBYNS, J. H. and LINSCHIED, R. L. (1980). Complications of Colles' Fractures. *Journal of Bone and Joint Surgery*, 62A: 4: 613-619.
- DUPUYTREN, G. (1831). De la rétraction des doigts par suite d'une affection de l'aponévrose palmaire.—Description de la maladie.—Opération chirurgicale qui convient dans ce cas. *Journal Universel et Hebdomadaire de Médecine et de Chirurgie Pratiques et des Institutions Médicales*, 5: 349-365.
- FÉRÉ, C. and DEMANCHE, R. (1903). Note sur un cas de rétraction de l'aponévrose palmaire consécutive à une fracture de l'avant-bras. *Revue de Chirurgie*, 28: 324-328.
- GOYRAND, G. (1833). Nouvelles recherches sur la rétraction permanente des doigts. *Mémoires de l'Académie Royale de Médecine*, 3: 489-496.
- GOYRAND, G. (1835). De la rétraction permanente des doigts. *Gazette Médicale de Paris*, 2s 3: 481-486.

Table 3—Reported incidence of Dupuytren's disease in series of patients with Colles' fracture

	Incidence	No. of patients
Stewart et al., 1985	22 (9.3%)	235
Kohlmayer, 1935	6 (5.4%)	110 males
	4 (0.75%)	530 females
Smaill, 1965	2 (4.9%)	41
Cooney et al., 1980	3 (1.1%)	565
Castaing, 1964	2 (0.45%)	440
Bruijn, 1987	5 (2.5%)	196
Bacorn and Kurtzke, 1953	4 (0.2%)	2132

- HUESTON, J. T. *Dupuytren's Contracture*. Edinburgh and London, E. and S. Livingstone, 1963: 74.
- IVERSEN, J. (1909). Über die traumatische Entstehung der Dupuytren'schen Kontraktur über deren Localisation am Daumen. Inaugural Dissertation, Kiel (quoted by Skoog, 1948 and Scholle, 1936).
- KOILMAYER, H. (1935). Zur Frage der traumatischen Entstehung der Dupuytren'schen Fingerkontraktur. *Zentralblatt für Chirurgie*, 33: 1928–1931.
- MAURER, G. (1936). Zur Lehre der Dupuytren'schen Palmarfascienkontraktur und ihre Behandlung. *Deutsche Zeitschrift für Chirurgie*, 246: 685–692.
- NICHOLS, J. B. (1899). A clinical study of Dupuytren's contracture of the palmar and digital fascia. *American Journal of the Medical Sciences*, 117: 3: 285–305.
- RINNE, H. A. (1888). Ueber eine seltene Aetiologie der Dupuytren'schen Fingercontractur. *Deutsche Medizinische Wochenschrift*, 14: 761.
- SCHAEFER, V. (1936). Die Genese der Dupuytren'schen Kontraktur (Die Bedeutung der Anlage, des chronischen Traumas und des Unfalles). *Zentralblatt für Chirurgie*, 29: 1712–1716.
- SCHOLLE, W. (1930). Über die *Dupuytren'sche* Fingerkontraktur unter besonderer Berücksichtigung ihres Vorkommens bei Jugendlichen. *Deutsche Zeitschrift für Chirurgie*, 223: 328–339.
- SKOOG, T. (1948). Dupuytren's contraction, with special reference to aetiology and improved surgical treatment. Its occurrence in epileptics. Note on knuckle-pads. *Acta Chirurgica Scandinavica*, 96: Supplement 139: 113–114.
- SMAILL, G. B. (1965). Long term follow up of Colles's fracture. *Journal of Bone and Joint Surgery*, 47B: 1: 80–85.
- STEWART, H. D., INNES, A. R. and BURKE, F. D. (1985). The hand complications of Colles' fractures. *Journal of Hand Surgery*, 10B: 1: 103–107.
- VOGT, P. Verkrümmung und Steifigkeit der Finger. In: Pitha, V. and Billroth, C. A. T. (Eds.) *Handbuch der allgemeinen und speziellen Chirurgie*. Stuttgart, Enke, 1868: Volume 4: Part 2B: Section 10: 141–145.

Accepted: 9 July 1991
Miss S. A. Kelly, Department of Plastic Surgery, University College Hospital, London WC1E 6AU.

© 1992 The British Society for Surgery of the Hand