

Journal of Hand Surgery (British and European Volume)

<http://jhs.sagepub.com/>

The Contractility of Knuckle Pads: An in vitro study

L. R. IRWIN, I. L. NAYLOR and W. HOLMS

J Hand Surg [Br] 1997 22: 110

DOI: 10.1016/S0266-7681(97)80033-2

The online version of this article can be found at:

<http://jhs.sagepub.com/content/22/1/110>

Published by:



<http://www.sagepublications.com>

On behalf of:

[British Society for Surgery of the Hand](#)

Additional services and information for *Journal of Hand Surgery (British and European Volume)* can be found at:

Email Alerts: <http://jhs.sagepub.com/cgi/alerts>

Subscriptions: <http://jhs.sagepub.com/subscriptions>

Reprints: <http://www.sagepub.com/journalsReprints.nav>

Permissions: <http://www.sagepub.com/journalsPermissions.nav>

Citations: <http://jhs.sagepub.com/content/22/1/110.refs.html>

>> [Version of Record](#) - Feb 1, 1997

[What is This?](#)

THE CONTRACTILITY OF KNUCKLE PADS

An in vitro study

L. R. IRWIN, I. L. NAYLOR and W. HOLMS

From the Bradford Royal Infirmary and the School of Pharmacy, University of Bradford, Bradford, UK

Strips of tissue from knuckle pads contract in response to the myofibroblast stimulant mepyramine in a reversible, repeatable and dose-dependent manner. The significance of this finding is discussed.
Journal of Hand Surgery (British and European Volume, 1997) 22B: 1: 110–112

Knuckle pads are often an associated finding in patients with Dupuytren's disease. Since their first mention in the late 19th century (Garrod, 1893; Paget, 1875), and further clinical and histological assessment shortly afterwards (Garrod, 1904; White, 1907), the incidence, histology, differential diagnosis and other properties of knuckle pads have all been well described in the literature (Hueston, 1984; Hueston and Wilson, 1973; Mikkelsen, 1977; Skoog, 1948; Weber, 1938; Wilson, 1972).

The ultrastructural demonstration of myofibroblasts in such pads (Caroli et al, 1991; Hueston, 1984) makes them histologically similar to the palmar nodules of Dupuytren's disease (James and Odom, 1980). Although the knuckle pads contain myofibroblasts, only one case has been described in which contraction was a problem (Hueston, 1982). In this case the tissue was found between the interphalangeal joints and led to problems with both active and passive flexion.

We have studied knuckle pads using the same system used to examine the in vitro contractility of myofibroblasts in palmar nodules (Naylor et al, 1994).

MATERIALS AND METHODS

Eight consecutive patients with knuckle pads were studied over a period of 2.5 years. There were six male and two female patients with an average age of 33.8 years. The number of specimens was 20. Of note, only three of the eight patients had palmar Dupuytren's disease.

Knuckle pads were excised under general or appropriate regional anaesthesia, with tourniquet control, via a transverse incision directly over the pad. The pad was dissected carefully from both the skin and the underlying extensor apparatus to which it was always found to be densely adherent.

The excised tissue was placed on to saline-soaked swabs at around 4°C and transported to the laboratory for the in vitro experiments. All tissue was used within 2 hours of excision.

Since the knuckle pads varied in size, each specimen was either used as obtained or bisected. Each specimen was weighed, its length and width recorded and then it was attached to a superfusion isometric recording system, as has previously been described for palmar Dupuytren's nodules (Naylor et al, 1994). Each tissue sample was arranged for tension measurements along the longitudinal axis of the original knuckle pad. All

specimens, irrespective of size, were placed under a preload of 2 g and allowed to equilibrate for 40 minutes.

To verify the absence of both skeletal and vascular smooth muscle in the tissue, barium chloride and potassium chloride were applied to the preparations at a fixed dose range of 1 to 8 mg. These were then followed by the drug mepyramine over the fixed dose range of 100 µg to 2 mg. The volumes injected did not exceed 0.2 ml. For each response to mepyramine, the height of the contraction was measured and transformed into a "change in isometric tension". The areas under the contraction tracings were also measured using a digitizer and DIGIT programme to assist in a more precise quantification of the responses.

After testing, all samples were placed in 10% formal saline for 7 days then processed for light microscopy by conventional techniques. Tissue sections, cut at 6 µm, were stained using Goldner's modification of Masson's trichrome stain (Goldner, 1938).

RESULTS

None of the tissue samples showed any spontaneous activity while resting in the organ baths attached to the superfusion apparatus. After an initial period of relaxation, they all held a constant tension for the remainder of the experimental period.

None of the specimens showed a response to the addition of potassium or barium chlorides, indicating the absence of both skeletal and smooth muscle in the preparations.

All tissues examined gave repeatable, dose-dependent contractions to mepyramine (Fig 1). When duplicate strips from a nodule were available, good correlation was obtained between the two samples. All the induced

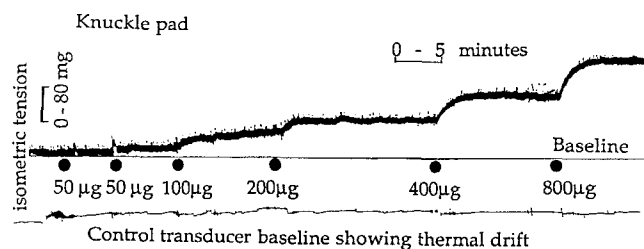


Fig 1 The type of dose-dependent contractile response to a superfusion dose of mepyramine, on a specimen from one patient. The slow, sustained response is typical.

contractile responses were fully reversible if enough time was left between drug additions.

The preparations were stable and sensitive for a period of about 8 hours after excision. There was variability among the tissue samples, but all the responses were repeatable within a tissue (Fig 2). Irrespective of the tissue studied, the dose response effect was very steep, indicating a narrow range of drug effectiveness. The shape of the responses to mepyramine are similar to those obtained from Dupuytren's nodules (Fig 3).

Histological examination revealed a dense fibrous matrix within which were areas of dense cellular deposition containing myofibroblasts. No smooth or skeletal muscle was seen.

DISCUSSION

These experiments show for the first time that knuckle pads can be made to contract in vitro.

The failure of potassium and barium chlorides to elicit a response, when taken in conjunction with the histological evidence, indicates that the response is not

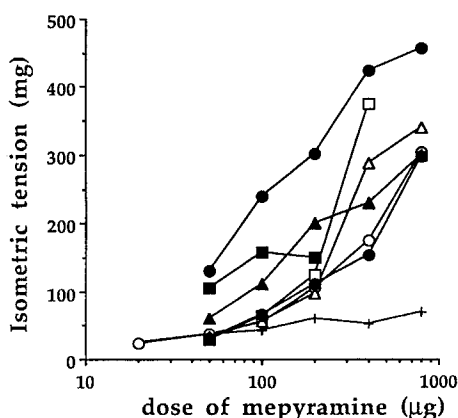


Fig 2 A comparison of responses among specimens. The steep dose response, repeatability and reversibility suggest a receptor effect.

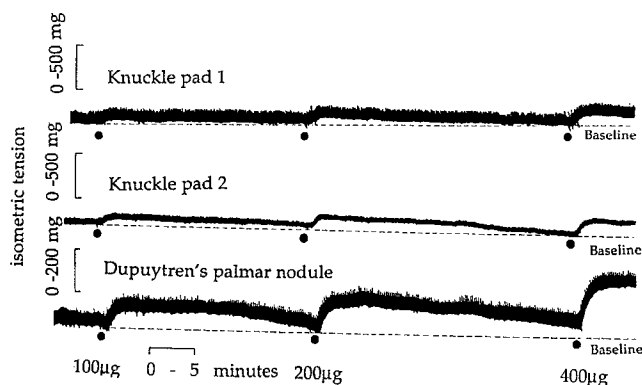


Fig 3 The responses of knuckle pads and palmar Dupuytren's nodules, which are known to rely on myofibroblasts for the demonstrated contractile effects.

due to either skeletal muscle or vascular smooth muscle in the tissues. The dose dependency, the reversibility and the repeatability of the responses would suggest that cellular receptors are responsible for the observed effects. Other studies (Caroli et al, 1991; Hueston, 1984) suggest that the myofibroblast is the cell most likely to be responsible for the effects.

The sensitivity to mepyramine, an antihistamine which has similar effects on Dupuytren's nodular tissue (Naylor et al, 1994) and the type of slow, sustained response seen, support the view that the cells have similar properties to those in palmar nodules.

In the technique of superfusion, the drug is applied to the surface of the tissue for only a very brief period, possibly 5 to 10 seconds, before being removed in the superfusing physiological solution. Consequently, the observed drug effects increasing beyond 1 to 15 minutes cannot be the result of continuous stimulation, but must be due to the initial excitation passing between the cells within the tissue and leading to a profound stimulation of the cells. This suggests that the cells in the tissue may well have a pseudosyncytial arrangement. This is not too unexpected since myofibroblasts are well documented as having cell-to-cell contacts through which information could be relayed. The results suggest that the initial stimulus which excites these cells in vivo (e.g. in the contractility of Dupuytren's disease) may only need to be of a small magnitude to exert a powerful and sustained effect.

These observations confirm the similarity in both structure and potential contractility of Dupuytren's tissue in the palm and knuckle pads on the dorsum of fingers. The fact that knuckle pads rarely cause problems from their contractility may be due to their more favourable anatomical position and the looser subcutaneous tissues around them compared with the palm (Hueston, 1985). However, some believe that physical activity at the affected area is responsible for cord formation and contractility (Baird et al, 1994).

Controversies continue to surround the histological, chemical and immunological nature of Dupuytren's disease. Arguments persist as to whether myofibroblasts are actually present in Dupuytren's tissue, and even which techniques are reliable in their demonstration (Berndt et al, 1994; Gabbiani and Montandon, 1985; McCann et al, 1993; Pasquali-Ronchetti et al, 1993).

This study appears to add weight to the belief that myofibroblasts are associated with the contractility of Dupuytren's tissue, but does not address the issue as to whether the trigger for activity is a systemic or a locally produced agent.

References

BAIRD K S, CROSSAN J F and WOJCIAK B (1994). Cytokine and growth factor control of the Dupuytren's nodule. *Journal of Hand Surgery*, 19B (Supplement 1): 22.
 BERNDT A, KOSMEHL H, KATENKAMP D, et al (1994). Appearance of myofibroblastic phenotype in Dupuytren's disease is associated with a fibronectin, laminin, collagen type-IV and tenascin extracellular matrix. *Pathobiology*, 62: 55-58.

- CAROLI A, ZANASI S, MARCUZZI A, et al (1991). Epidemiological and structural findings supporting the fibromatous origin of dorsal knuckle pads. *Journal of Hand Surgery*, 16B: 258-262.
- GABBIANI G and MONTANDON D. The myofibroblasts in Dupuytren's disease and other fibromatoses. In: Hueston J T and Tubiana R (Eds): *Dupuytren's disease*, 2nd Edn. Edinburgh, Churchill Livingstone, 1985: 86-93.
- GARROD A E (1893). On an unusual form of nodule upon the joints of the fingers. *Saint Bartholomew's Hospital Reports*, 29: 157-161.
- GARROD A E (1904). Concerning pads upon the finger joints and their clinical relationships. *British Medical Journal*, 2: 8.
- GOLDNER J (1938). A modification of the Masson trichrome technique for routine laboratory purposes. *American Journal of Pathology*, 14: 237-243.
- HUESTON J T (1982). The table top test. *The Hand*, 14: 100-103.
- HUESTON J T (1984). Some observations on knuckle pads. *Journal of Hand Surgery*, 9B: 75-78.
- HUESTON J T. The management of ectopic lesions in Dupuytren's disease. In: Hueston J T and Tubiana R (Eds): *Dupuytren's disease*, 2nd Edn. Edinburgh, Churchill Livingstone, 1985: 204-210.
- HUESTON J T and WILSON W F (1973). Knuckle pads. *Australian and New Zealand Journal of Surgery*, 42: 274-277.
- JAMES W D and ODOM R B (1980). The role of the myofibroblast in Dupuytren's contracture. *Archives in Dermatology*, 116: 807-811.
- MCCANN B G, LOGAN A, BELCHER H, et al (1993). The presence of myofibroblasts in the dermis of patients with Dupuytren's contracture. *Journal of Hand Surgery*, 18B: 656-661.
- MIKKELSEN O A (1977). Knuckle pads in Dupuytren's disease. *The Hand*, 9: 301-305.
- NAYLOR I L, COLEMAN D J, COLEMAN R A, et al (1994). Reactivity of nodular cells in vitro: a guide to the pharmacological treatment of Dupuytren's contracture. In: Berger A, Delbrück A, Brenner P and Hinzmann R (Eds): *Dupuytren's disease: pathobiochemistry and clinical management*. Berlin, Springer Verlag, 1994: 139-150.
- PAGET J (1875). On the minor signs of gout in the hands and feet. *British Medical Journal*, 1: 665-666.
- PASQUALI-RONCHEZZI I, GUERRA D, BACCARANI-CONTRI M, et al (1993). A clinical, ultrastructural and immunochemical study of Dupuytren's disease. *Journal of Hand Surgery*, 18B: 262-269.
- SKOOG T (1948). Dupuytren's contraction with special reference to aetiology and improved surgical treatment. *Acta Chirurgica Scandinavica*, 96 (Supplement 139): 86-93.
- WEBER F P (1938). A note on Dupuytren's contraction, camptodactylia and knuckle pads. *British Journal of Dermatology and Syphilis*, 50: 26-31.
- WHITE W H (1907). On pads on the finger joints. *Quarterly Journal of Medicine*, 1: 479-480.
- WILSON W F (1972). Shearer's knuckles. *Australian and New Zealand Journal of Surgery*, 42: 192-193.

Received: 9 February 1996
 Accepted after revision: 31 May 1996
 Mr L. R. Irwin, Department of Orthopaedics, St James's University Hospital, Beckett Street, Leeds LS9 7TF, UK.

© 1997 The British Society for Surgery of the Hand