
Narrow-band red light phototherapy in perennial allergic rhinitis and nasal polyposis

Ittai Neuman, MD and Yehuda Finkelstein, MD

Background: Allergic rhinitis and nasal polyposis are common nasal diseases, but the available treatment modalities have only limited success.

Objective: To assess the therapeutic effect of low-energy narrow-band red light phototherapy on nasal clinical symptoms of allergic rhinitis and nasal polyposis.

Methods: In a double-blind randomized prospective study, 50 patients with allergic rhinitis and 10 with nasal polyposis received intranasal illumination at 660 nm for 4.4 minutes three times a day for 14 days (total dose 6 joules per day). Twenty-nine rhinitic patients and one patient with polyposis received equivalent sham illumination as placebo. Evaluation was based on symptom scores and a clinical assessment that included pre-treatment and post-treatment videotaped rigid and flexible nasendoscopy.

Results: Following treatment, improvement of symptoms was reported by 72% of the allergic rhinitis patients and objective improvement was endoscopically demonstrated in 70% of them as compared with 24% and 3%, respectively, in the placebo group. These differences were significant. No improvement was obtained in any of the patients with polyposis.

Conclusions: Allergic rhinitis, if uncomplicated by polyps or chronic sinusitis, can be effectively treated by narrow-band red light illumination of the nasal mucosa at 660 nm, with marked alleviation of clinical symptoms. Whenever possible, candidates for phototherapy should be selected by endoscopic examination.

Ann Allergy Asthma Immunol 1997;78:399–406.

INTRODUCTION

Allergic rhinitis is the most common of all the IgE-mediated allergic diseases. Its incidence may be as high as 10% in children and 20% to 30% in adolescents.^{1,2} Patients who suffer from annoying symptoms are commonly treated by daily medication with antihistamines, decongestants, topical or systemic corticosteroids, nasal disodium cromoglycate, levocabastine or ipratropium bromide, or by hyposensitization with specific allergens. Treatment by daily medication is aimed at

reducing symptoms caused by allergen triggers and inflammation.

Although commonly used, these drugs are far from ideal. For example, antihistamine administration may result in symptomatic improvement in 37% to 83% of patients,^{3–10} but there are Food and Drug Association warnings of side effects or after effects and the cost is often prohibitive. The presence of nasal polyps, which are sometimes related to chronic inflammation and to allergic states,¹¹ further aggravates the symptoms and may require repeated surgical intervention. Current, research efforts are therefore aimed at devising effective new approaches for the relief of allergic rhinitis and nasal polyposis.

Low-energy narrow-band illumination has been used successfully as a therapeutic measure in a number of medical situations.^{12–16} Low-energy narrow-band light in the visible and infrared ranges has various biochemi-

cal, cellular, histologic, and functional effects.^{17–25} Reactive oxygen species in human blood were found to be suppressed after diode laser illumination at 660, 820, 880, and 950 nm,²¹ possibly as a result of activation of superoxide dismutase²² or activation of catalase.²³ Several authors have reported and measured changes in Ca²⁺ transport due to visible and infrared light.^{20,24,25} Since allergic symptoms are largely dependent on oxygen radical formation^{18–25} and Ca²⁺ mobility,²⁶ we considered it worth investigating the effects of a 660-nm light-emitting diode (LED) on patients with allergic rhinitis and nasal polyposis.

The aim of the present study was to investigate the efficacy of intranasal illumination at 660 nm in the treatment of perennial allergic rhinitis and nasal polyposis. The rhinologic status of patients before and after treatment was evaluated by the use of videotaped nasendoscopy, which is the “gold standard” for diagnostic evaluation of nasal diseases.

PATIENTS AND METHODS

The study group consisted of 50 patients with perennial allergic rhinitis and 10 with nasal polyposis (Table 1). Patients' ages ranged from 12 to 68 years (mean 26.5 years) and the male:female ratio was 30:20. All patients had daily symptoms despite antihistamines and local steroid spray treatments. Twenty patients had concomitant asthma symptoms. The control group consisted of 29 patients with perennial allergic rhinitis and one with polyposis (Table 2). Patients' ages ranged from 12 to 52 years (mean 24 years), the male:female ratio was 18:11, and 12 patients had bronchial asthma. Patients with severe deviation of the nasal septum causing bilateral nasal obstruction were excluded from

From the Department of Allergy and Asthma, Hasharon Hospital, Petah Tiqwa (IN); and the Department of Otolaryngology, Head and Neck Surgery, Meir Hospital, Sapir Medical Center, Kfar Saba (YF), and the Sackler School of Medicine, Tel-Aviv University; Israel.

This research was supported in part by Amcor Ltd, POB 2850, Tel Aviv, Israel.

Received for publication February 5, 1996.

Accepted for publication in revised form September 19, 1996.

Table 1. Estimated Pre-treatment Severity of Symptoms of Allergic Rhinitis in the Study Group and Their Improvement After Intranasal Phototherapy (n = 50)

Symptom	Severity Prior to Photo-therapy	No. of Patients	Improvement					
			Subjective			Objective		
			None	Mild	Marked	None	Mild	Marked
Nasal obstruction	Normal	1						
	Mild	2	2	0	0	1	0	1
	Moderate	20	1+1*	9	9	9	9	2
	Severe	27	6	9	12	9	11	7
Total improvement			39/49 = 80%			30/49 = 61%		
Rhinorrhea	Normal	2						
	Mild	6	1	2	3	1	3	2
	Moderate	16	2	4	10	2	10	4
	Severe	26	6	11	9	14	4	8
Total improvement			39/48 = 81%			31/48 = 65%		
Edema of middle turbinate	Normal	19						
	Mild	25				12	8	5
	Moderate	3				2	0	1
	Severe	3				2	1	0
Total improvement						15/31 = 48%		
Nasal itching	Normal	13						
	Mild	32	8	13	11			
	Moderate	5	1	3	1			
	Severe	0						
Total improvement			28/37 = 76%					
Headache	Normal	26						
	Mild	24	7	8	9			
	Moderate	0						
	Severe	0						
Total improvement			17/24 = 70%					
Cough (postnasal drip)	Normal	21						
	Mild	20	5	5	10			
	Moderate	8	4	1	3			
	Severe	1	0	0	1			
Total improvement			20/29 = 69%					

* Deterioration.

the study. Candidates in whom nasendoscopy revealed purulent postnasal drip flowing from an edematous and hyperemic infundibulum or with streaks of purulent discharge flowing across the eustachian tube orifice were diagnosed as suffering from sinusitis and were excluded from the study. Also excluded were patients who were convalescing from an upper respiratory tract infection or had used nasal or oral corticosteroids less than 30 days before the start of the study. The study was done during the early summer months and both the control and the study patients were run simultaneously.

The diagnosis of allergic rhinitis was based on definite symptoms of

nasal itching, rhinorrhea, sneezing, nasal obstruction or mouth breathing, as well as positive reactions to epicutaneous tests to perennial inhalant antigens. Skin prick testing was performed with the most concentrated glycerinated extract available: house dust mite, cockroach, molds, feathers, grass pollen, weed pollens, sage pollen, and local tree pollens. Criteria for positive skin prick test responses were a wheel of 3 mm or greater diameter with erythema of at least 5 mm. Histamine control skin tests were read at ten minutes, allergen and negative control skin tests were read at 15 minutes. The duration of nasal symptoms ranged from 1 to 16 years (mean 5 years). Pretreatment se-

verity of rhinitis symptoms was determined according to a standardized severity scale.²⁵ A score of 0 (no symptoms) to 3 (severe symptoms) was assigned for each of the following rhinitis symptoms: nasal stuffiness, rhinorrhea, nasal itching, sneezing, headache, and cough (postnasal drip). Post-treatment symptomatic improvement of one grade was regarded as mild while improvement of two or more grades was regarded as marked.

After recording their symptoms in a diary for 2 weeks as a run-in period, all candidates for inclusion in the study underwent videoendoscopic examination of the nose. The videoendoscopic system consisted of a xenon light

Table 2. Estimated Pretreatment Severity of Symptoms of Allergic Rhinitis in the Control Group and Their Improvement After Sham Treatment (n = 29).

Symptom	Severity Prior to Treatment	No. of Patients	Improvement					
			Subjective			Objective		
			None	Mild	Marked	None	Mild	Marked
Nasal obstruction	Normal	0						
	Mild	3	2	0	1	0	0	0
	Moderate	12	6+1*	3	2	9	3	0
	Severe	14	11	3	0	11	3	0
Total improvement			9/29 = 31%			6/29 = 21%		
Rhinorrhea	Normal	1						
	Mild	5	1	1	3	4	0	1
	Moderate	10	10	0	0	10	0	0
	Severe	13	13	0	0	12	1	0
Total improvement			4/28 = 14%			2/28 = 7%		
Edema of middle turbinate	Normal	12				1*		
	Mild	14				12	2	
	Moderate	2				2		
	Severe	1				1		
Total improvement						2/17 = 12%		
Nasal itching	Normal	4						
	Mild	18	9+1*	5	3			
	Moderate	7	0	0	0			
	Severe	0						
Total improvement			8/25 = 32%					
Headache	Normal	18						
	Mild	10	8	1	1			
	Moderate	0						
	Severe	0						
Total improvement			2/10 = 20%					
Cough (postnasal drip)	Normal	16						
	Mild	8	5	2	1			
	Moderate	5	5					
	Severe	0						
Total improvement			3/13 = 21%					

* Deterioration.

source (Karl Storz PR-50), Contec-Medical Endo-Camera and a video recording apparatus. Each patient was examined by the use of a rigid endoscope (Storz Hopkins 4-mm telescope) introduced as deeply as possible into the nostril for close examination of the mucosa and intranasal structures. In addition, a flexible endoscope (Olympus ENF-P3) was used to penetrate the narrow intranasal passages not accessible by the rigid endoscope, thus enabling close examination of the nasopharynx for postnasal drip.

Nasal endoscopy facilitates qualitative evaluation of the mucosa, diagnosis of polyposis or polypoid disease,

and characterization of the secreted discharge as watery, thick, mucoid, purulent, white, yellowish, or green. It also provides the examiner with a close view of the intranasal structures and the interrelationships between them, enabling diagnosis of anatomic abnormalities of the septum and middle meatus that may occlude sinusal ostia.^{26,27}

When the endoscopic examination was equivocal and sinusitis could not be excluded, computed tomography of the sinuses in coronal sections was performed. The diagnosis of sinusitis is based on the characteristic endoscopic^{26,27} and radiologic findings.^{28,29} Patients in whom the endoscopic exami-

nation was equivocal and CT revealed sinus disease were also excluded from the study.

The study was designed as a double-blind, randomized, parallel-group trial. The study protocol was approved by the Helsinki Committee on the use of human subjects in research. Informed consent was obtained in writing from all patients prior to their participation.

Patients were randomly assigned to receive either intranasal illumination at 660 nm or sham illumination as a placebo. The instrument used was, a Bio-nase unit (Amcor Ltd, Israel), which emits red light at 660 ± 5 nm. The unit consists of a control box and two light-



Figure 1. The Bionase unit, consisting of a control box containing the electronic circuit and a battery, and two light-emitting units for intranasal use. Note the push button on the control box.

emitting diode probes for intranasal use (Fig 1). A push-button switch on the control box activates the probes for 4.4 minutes, during which time 1 joule of light energy is delivered from each unit. Patients were instructed to introduce the probes into their nostrils as deeply as possible and to press the push button. Each nostril was subjected to low-energy stimulation (4 mW) for 4.4 minutes (1 joule per treatment session) three times a day for 14 consecutive days (Fig 1). Bionase devices with internally disconnected light emitting diodes probes were used for sham illumination in the placebo group.

Patients were instructed to record their rhinitis symptoms daily in the evening throughout the study period. Illumination treatment was started immediately after the initial videoendoscopic examination. No medications were allowed during the 2 weeks of phototherapy. Two weeks after the start of the treatment, patients presented themselves for a review of their scores and an objective assessment of rhinitis symptoms by videotaped endoscopy. The ear, nose and throat specialist (YF), who performed this examination was not informed of the kind of illumination (660 nm or sham) each patient had received. The videotapes of each patient before and after treatment were compared and evaluated by the authors upon termination of the treatment.

Statistical analysis

Differences between the placebo and test groups were evaluated by the Mann-Whitney nonparametric test. The chi square test was performed to detect differences between the two groups in the various symptom-related variables (nasal obstruction, rhinorrhea, nasal itching, cough and headache) and in endoscopic findings (nasal mucosa, secretions, nasal passage and ethmoid appearance). The Spear-

man correlation test was used to ascertain differences in age, gender, and the presence of bronchial asthma as independent variables and in the improvement in patients' various symptoms and the endoscopic findings as dependent variables. A probability of less than .05 was considered significant.

RESULTS

There were no significant differences in gender or age between patients in the study and the placebo groups. The degrees of severity of symptomatology prior to treatment of the patients with allergic rhinitis in the study and placebo groups are summarized in Tables 1 and 2, respectively. Nasal obstruction caused by edematous congestion of the inferior turbinates was the most common pretreatment finding on nasendoscopic examination (Tables 1 and 2, Figs 2 and 3). In second place among the findings clearly observed by the rigid endoscope were droplets of mucoid or watery discharge scattered on the septal and turbinate mucosa (Figs 2 and 3). These findings, together with streaks of mucoid dis-

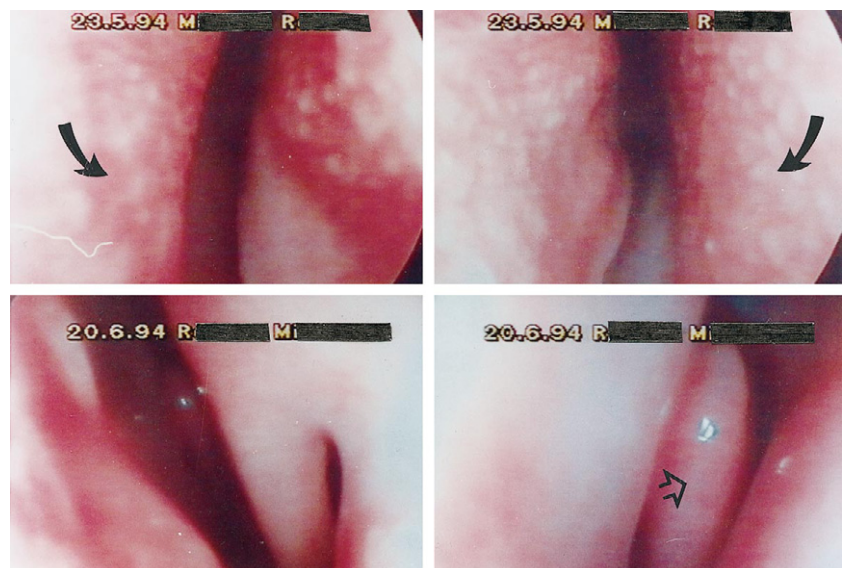


Figure 2. Typical rigid endoscopic views of the nasal mucosa of a patient with allergic rhinitis, before (top), and after (bottom) treatment. Top: edematous congestion of the inferior turbinates (arrows). Small drops of mucoid discharge are scattered on the septal (curved arrows) and turbinates' hyperemic mucosa. Bottom: endoscopic views of the nose of the same patient after successful phototherapy. The inferior turbinate (arrow), the middle turbinate (empty arrow) and the nasal mucosa appear normal.

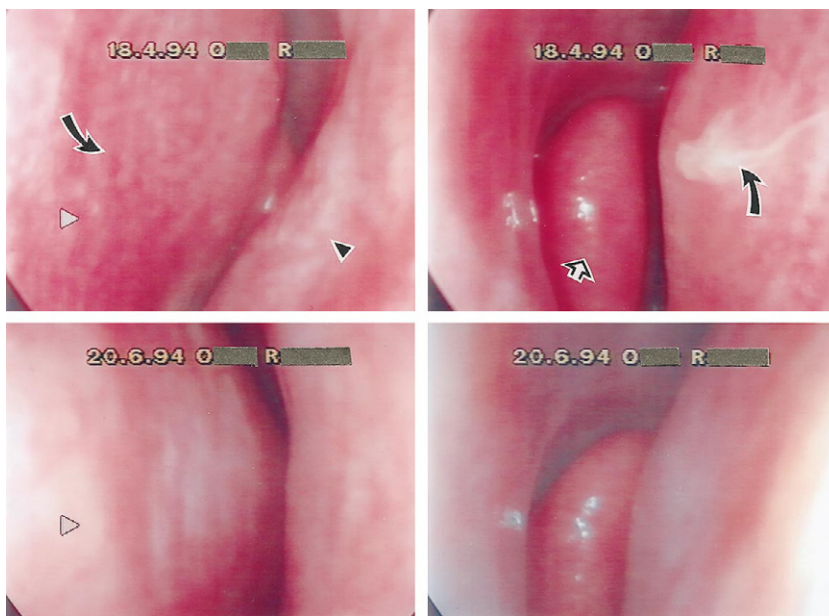


Figure 3. A typical rigid endoscopic view of the nasal mucosa in a patient with allergic rhinitis. Top: before treatment the mucosa of the septum (curved arrows) and inferior turbinate (arrowhead) and middle turbinate (empty arrow) is hyperemic, congested and shows scattered small drops of mucoid discharge. Bottom: normal mucosa, inferior and middle turbinates in the same patient after successful phototherapy.

charge flowing across the eustachian tube orifice, were obtained to varying extents in almost all patients. Only one patient in the study group had normal nasal mucosa (Table 1, "nasal obstruction"). Only two patients in the study group (Table 1: "rhinorrhea") and one patient in the placebo group (Table 2—"rhinorrhea") did not show watery or mucoid discharge. Edema of the middle turbinate with mucoid or watery discharge was found in 50 of the 79 patients with allergic rhinitis.

The results obtained in the two groups after 2 weeks of treatment are summarized in Tables 3 and 4, respectively. Mild overall improvement of symptoms was experienced by 44% and marked improvement by 29% of the patients with allergic rhinitis in the active treatment group. Patients with accompanying septal deviation reported a lower rate of improvement. Of the ten patients with nasal polyposis only one experienced mild improvement in rhinorrhea, but none showed

any objective improvement (Table 3). When the patients with nasal polyposis were excluded and the various symptoms were individually evaluated after phototherapy in patients with allergic rhinitis only, an improvement in nasal obstruction was reported by 80% and an improvement in rhinorrhea was reported by 81% of the patients in the active treatment group versus 31% and 14% in the sham group (Table 1 and 2). Considering only the patients with allergic rhinitis, mild objective improvement in nasal obstruction was endoscopically demonstrated after phototherapy in 41% (in 9 patients with moderate and in 11 patients with severe nasal obstruction). Marked objective improvement was found in 20% (in one patient with mild, two patients with moderate, and in seven patients with severe nasal obstruction) (Table 1). Objective improvement in rhinorrhea was mild in 35% of these patients and marked in 29%. Mild or marked objective improvement of edema of the middle turbinate was seen in 48%. Subjective improvements in nasal itching, headache, and cough were reported by 60%, 70%, and 69% of these patients, respectively.

Of the 29 patients with allergic rhinitis in the placebo group (Tables 2 and 4), seven (24%) reported mild or marked improvement; and objective evaluation showed only mild improvement in six patients (21%) (Table 4). When allergic rhinitis symptoms in the placebo group were evaluated individ-

Table 3. Number (%) of Patients in the Study Group Showing Improvement or Deterioration After Intranasal Phototherapy

Disease	Improvement						Deterioration	
	None		Mild		Marked		Sub	Obj
	Sub*	Obj*	Sub	Obj	Sub	Obj		
Allergic rhinitis (n = 34)	8 (24%)	9 (26%)	15 (44%)	13 (38%)	10 (29%)	12 (35%)	1 (3%)	0
Allergic rhinitis and septal deviation (n = 16)	5 (31%)	6 (38%)	10 (63%)	9 (56%)	1 (6%)	1 (6%)	0	0
Nasal polyposis (n = 10)	9 (90%)	10 (100%)	1 (10%)	0	0	0	0	0
Total number (n = 50)†	13	15	25	22	11	13	1	0
Total percent†	26%	30%	50%	44%	22%	26%	2%	

* Sub = subjective and Obj = objective.

† Only the patients with allergic rhinitis are included in the calculation.

Table 4. Number of Patients in the Control Group Showing Improvement or Deterioration After Sham Treatment

Disease	Improvement						Deterioration	
	None		Mild		Marked		Sub	Obj
	Sub	Obj	Sub	Obj	Sub	Obj		
Allergic rhinitis (n = 23)	17	18	4	5	1	0	1	0
	74%	78%	17%		4%		4%	
Allergic rhinitis and septal deviation (n = 6)	4	5	1	1	1	0	0	0
	67%	83%	17%	17%	17%			
Nasal polyposis (n = 1)	1	1						
	100%	100%						
Total number (29)†	21	23	5	6	2	0	1	0
Total percent†	72.5%	79%	17%	21%	7%		3.5%	

* Sub = subjective and Obj = objective.

† Only the patients with allergic rhinitis are included in the calculation.

ually, subjective improvement in nasal obstruction was reported by 31% of patients and objective improvement was found in 21%. The corresponding findings for rhinorrhea were 14% and 7%. The objective improvement in edema of the middle turbinate and the subjective improvements in nasal itching, headache, and cough are recorded in Table 2.

Subjectively experienced improvement in the study group of patients with allergic rhinitis was significantly greater than in the placebo group with respect to the following variables: nasal obstruction ($P = .016$), headache ($P = .023$), nasal itching ($P = .019$), cough ($P = .004$), rhinorrhea ($P = .0004$), and overall subjective improvement ($.021$). Objectively recorded improvement was also significantly greater in the study group with regard to the appearance of the nasal mucosa ($P = .017$), ethmoidal edema ($P = .0007$), nasal passage ($P = .0002$), nasal discharge ($P = .022$), and overall objective improvement ($P = .0006$). In patients with allergic rhinitis only, as compared with those with allergic rhinitis accompanied by septal deviation, improvements in the mucosal appearance and nasal passage were less significant ($P = .04$ and $.02$ respectively) in the study group than in the placebo group, and differences in improvement in nasal discharge were of borderline significance ($P = .06$). Improvements in symptomatology and in endoscopic findings were not corre-

lated with sex, age, coexistence of bronchial asthma, or previous response to medical treatment of the condition.

DISCUSSION

The findings of this study demonstrate that exposure of the congested nasal mucosa of patients with allergic rhinitis to narrow-band red light illumination at 660 nm results in a significant alleviation of symptoms, except in those cases aggravated by the presence of polyps or by a deviated nasal septum. In many cases the clinical improvement, though significant, was only partial. Nevertheless, in some instances phototherapy proved beneficial where all attempts at other types of conservative treatment had failed. Many of our patients had not responded to previous conservative treatment with antihistamines or local steroids. Others had suffered side effects that precluded the use of antihistamines, so that phototherapy was their only recourse. No adverse side effects of the treatment were observed in this study.

Low-energy narrow-band phototherapy may therefore be viewed as a useful additional approach in the treatment of allergic rhinitis. Although the resulting improvement may be only partial, this treatment could be of value after surgical procedures such as inferior turbinectomy and correction of septal deviation. Further, since sinusitis may be a sequela of upper respiratory tract infection, malformed intrana-

sal structures, or chronic mucosal disease such as allergic rhinitis, polypoid disease or polyposis, the routine use of phototherapy in patients with allergic rhinitis could possibly reduce the occurrence of secondary sinusitis in these patients.

Phototherapy had no effect in patients with nasal polyposis. Polyps originate in the ethmoidal cells, out of reach of the diode's beam. Candidates for phototherapy should therefore be selected on the basis of an accurate nasal examination in order to exclude patients with polyposis and/or other conditions not amenable to such treatment.

In the present study, both patient selection and objective therapeutic assessments were based mainly on videoendoscopy. The use of endoscopy and of computed tomography have changed completely the methods of diagnosis and treatment of sinusitis.²⁶⁻²⁹ Patients with equivocal endoscopic findings were excluded from our study if CT demonstrated sinus disease. CT scanning provides information about the 3 dimensional structure of the paranasal sinus complex. Endoscopy, however, also yields useful information on the appearance of the mucosa and may even allow detection of small areas of pathologic involvement not usually revealed by CT. Endoscopic findings of purulent discharge are indicative of sinusitis even if the radiographic examination is normal, and its cause should be deter-

mined. Endoscopy together with CT therefore appears to be a useful diagnostic procedure in the selection of patients for phototherapy. In addition, the video equipment allows convenient documentation of the findings.

Low-energy illumination therapy has proved effective in a number of clinical situations such as pain relief³⁰ and wound healing.¹³ Illumination at both the visible (380 to 770 nm) and the infrared (700 to 1000 nm) range were shown to be of therapeutic benefit, but these two types of illumination differ markedly in their photochemical and photophysical properties. The visible light probably initiates the cascade of metabolic events at the level of the respiratory chain of the mitochondria, including the formation of reactive oxygen species, through a photochemical reaction,⁹ whereas infrared illumination does so by activating enzymes, and probably also Ca²⁺ channels in the membranes.³¹ Karu et al²¹ found that diode lasers (660, 820, 880 and 950 nm) suppress the release of reactive oxygen species in human blood. Czuba et al³² recently reported a decrease in neutrophil chemiluminescence, considered a sensitive indicator of cellular oxidative metabolism, during exposure of the cells to low-power infrared illumination. Yamaha et al³³ described the production of reactive oxygen species in human neutrophils following their illumination at 830 nm. Another recent finding is the activation of catalase and superoxide dismutase by red light.^{22,23} Catalase is known to regulate H₂O₂ concentration in the cell and superoxide dismutase to suppress O₂ formation. Activation of these enzymes by red light might explain how red light acts to suppress the oxygen radicals formed in allergic reactions. As for the effect of light illumination on Ca²⁺ transport, accelerated influx of Ca²⁺ into cells was reported following illumination at 633 and 660 nm.^{17,24,25} Since allergic symptoms are strongly dependent on formation of reactive oxygen species³⁴⁻⁴¹ and on transient [Ca²⁺] changes in participant neutrophils, eosinophils or mast cells,⁴² it seems likely that these cells are af-

ected by light of the appropriate wavelength, intensity and energy. Accordingly, on the basis of findings in previous studies,^{31,43,44} the illumination selected for our study was red light at 660 nm.

The patients who participated in the present study were followed up for approximately 1 year, and none exhibited any adverse side effects of the phototherapy. Those patients who had responded favorably to the treatment showed continuing benefit throughout the year. In some patients, illumination seemed to act synergistically with antihistamines, local steroids, or disodium cromoglycate. We believe that many patients can obtain relief of symptoms with this new therapeutic protocol, either by itself or in combination with other modes of treatment. On the basis of the findings in our study, although further more detailed followup and comparisons with conventional therapy are needed, we suggest illumination at a wavelength of 660 nm for the treatment of symptoms of allergic rhinitis.

In conclusion, allergic rhinitis, when uncomplicated by polyps, deviated nasal septum or chronic sinusitis, may be treated effectively by red light illumination of the nasal mucosa at 660 nm, leading in many cases to marked alleviation of symptoms. Wherever possible, candidates should be selected by endoscopic examination to rule out polyposis and sinusitis.

ACKNOWLEDGMENT

We express our appreciation to Ms. Nava Yellin for help with the statistical work, to Rahel Lobart PhD from the Physics Department, Bar Ilan University, Ramat Gan for her assistance in preparing the manuscript, to Eng. Emanuel Mendes for the technical assistance, and to Ms. Shirley Smith for editing the manuscript.

REFERENCES

1. Haahtela T, Heiskala M, Suoniemi I. Allergic disorders and immediate skin test reactivity in Finnish adolescents. *Allergy* 1980;35:433-41.
2. Malmberg H. Symptoms of chronic

and allergic rhinitis and occurrence of nasal secretion granulocytes in university students, school children, and infants. *Allergy* 1979;36:389-94.

3. Oei HD. Double-blind comparison of loratadine (SCH 29851), astemizole, and placebo in hay fever with special regard to onset of action. *Ann Allergy* 1988;61:36-9.
4. Friedman HM. Loratadine: a potent, nonsedating, and long-acting H1 antagonist. *Am J Rhinol* 1987;1:95-9.
5. Banov CH. Comparative efficacy of once daily loratadine versus terfenadine in the treatment of allergic rhinitis. *J Intern Med Res* 1989;17:150-6.
6. Chu TJ, Yamata M, Biedermann AA, et al. Once versus twice daily dosing of terfenadine in the treatment of seasonal allergic rhinitis: US and European studies. *Ann Allergy* 1989;63:612-5.
7. Kaliner MA. Nonsedating antihistamines: pharmacology, clinical efficacy and adverse effects. *Am Fam Phys* 1992; 45:1337-42.
8. Clissold SP, Sorkin EM, Goa KL. Loratadine: a preliminary review of its pharmacodynamic properties and therapeutic efficacy. *Drugs* 1989;37: 42-57.
9. Simons FER, Reggin JD, Roberts JR, Simons KJ. Benefit/risk ratio of the antihistamines (H1-receptor antagonists) Terfenadine and chlorpheniramine in children. *J Pediatr* 1994;124: 979-83.
10. Bruttmann G, Charpin D, Germouty J, et al. Evaluation of the efficacy and safety of loratadine in perennial allergic rhinitis. *J Allergy Clin Immunol* 1989;83:411-6.
11. Shatkin JS, Delsupehe KG, Thisted RA, Corey JP. Mucosal allergy in the absence of systemic allergy in nasal polyposis and rhinitis: a meta-analysis. *Otolaryngol Head Neck Surg* 1994; 111:553-6.
12. Caspers KH. Laser stimulation therapy. *Physics Med Rehab* 1977;18: 426-45.
13. Kana JS, Halna D, Waldelich W. Effect of low power density laser radiation on healing of open skin wounds in rats. *Arch Surg* 1981;116:291-6.
14. Kovacs L. The stimulatory effect of laser on the physiological healing of portion surface. *Lasers Surg Med* 1981;1:241-52.
15. Mester E. Clinical results of laser stimulation and experimental studies on the

- mechanism of action. *Min Med* 1981; 72:2195-9.
16. Ribari O. The stimulating effect of low power laser rays: Experimental examinations in otorhinolaryngology. *Rev Laryng* 1981;102:531-3.
 17. Sallet IC, Passarella S, Qualiariello E. Effects of selective irradiation on mammalian mitochondria. *Photochem Photobiol* 1987;45a:433-5.
 18. Bolognani L, Volpi N. Reactivation of partially inactivated enzymes by low power laser beam. *Radiol Med* 1991; 81:81-6.
 19. Rochking S, Nissan M, Lubart R, et al. The in vivo nerve response to direct low-energy laser inactivation. *Acta Neurochir* 1988;94:74-7.
 20. Lubart R, Wollman Y, Friedman H, et al. Effects of visible and near IR lasers on cell cultures. *J Photochem Photobiol* 1992;12:305-10.
 21. Karu T, Andreichuk T, Ryalykh T. Suppression of human blood chemiluminescence by diode laser irradiation at wavelength 660, 820, 880 OR 950 nm. *Laser Ther* 1993;5:103-9.
 22. Vladimirov YA, Gorbatenkova EA, Parcimonov NV, Azizova OA. Photo-reactivation of superoxide dismutase by intensive red light. *Free Rad Biol Med* 1988;5:281-6.
 23. Karu TI, Lyapunova TS, Pomosnikova NA. Activation of yeast metabolism with HE-NE laser radiation. IV. Relationship between the activity of catalase and stimulation of protein synthesis. *Lasers Life Sci* 1993;5: 251-7.
 24. Young SR, Dyson M, Bolton P. Effect of light on calcium uptake by macrophages. *Laser Ther* 1990;2:53-7.
 25. Karu T. Depression of the genome after irradiation of human lymphocytes with HE-NE laser. *Laser Ther* 1992;4: 5-24.
 26. Stammberger H. Endoscopic endonasal surgery—concepts in treatment of recurrent rhinosinusitis. Part I. Anatomic and pathophysiologic considerations. *Otolaryngol Head Neck Surg* 1986;94:143-7.
 27. Stammberger H. Endoscopic endonasal surgery—concepts in treatment of recurrent rhinosinusitis. Part II. Surgical technique. *Otolaryngol Head Neck Surg* 1986;94:147-56.
 28. Nass RL, Holliday RA, Reede DL. Diagnosis of surgical sinusitis using nasal endoscopy and computed tomography. *Laryngoscope* 1989;99:1158-60.
 29. Lazar RH, Younis RT, Parvey LS. Comparison of plain radiographs, coronal CT, and intraoperative findings in children with chronic sinusitis. *Otolaryngol Head Neck Surg* 1992; 107:29-34.
 30. Walker J. Relief from chronic pain by low power laser illumination. *Neurosci Lett* 1983;43:339-44.
 31. Karu T. Molecular mechanism of the therapeutic effect of low intensity laser radiation. *Lasers Life Sci* 1988;2: 53-74.
 32. Czuba P, Adamek M, Krol W, et al. Decrease of neutrophils chemiluminescence during the exposure to low power infrared radiation. *SPIE*, 1994; 2324:307-10.
 33. Yamaha M, Shiroto C, Kobaya H, et al. Mechanistic approach to GaAlAs diode laser effects on production of reactive oxygen species from human neutrophils as a model for therapeutic modality at cellular level. *Laser Ther* 1993;5:111-6.
 34. Austin CE, Foreman JC. The effect of platelet-activating factor on the responsiveness of the human nasal airway. *Br J Pharmacol* 1993;110:13-8.
 35. Gorski F, Krakowiak A, Ruta U, et al. Eosinophil and neutrophil chemiluminescence in patients with atopic asthma and in healthy subjects. *Allergol Immunopathol Madr* 1993;21: 71-4.
 36. Shichijo T, Ariyama A, Tsuji Y. Oxygen radicals. *Nippon Rinsho* 1993;51: 638-42.
 37. Chanez P, Dent G, Yukawa T, et al. Generation of oxygen free radicals from blood eosinophils from asthma patients after stimulation with PAF or phorbol ester. *Eur Respir J* 1990;3: 1002-7.
 38. Fujimoto K, Yoshikawa S, Martin S, et al. Oxygen radical scavengers protect against eosinophil-induced injury in isolated perfused rat lungs. *J Appl Physiol* 1992;73:687-94.
 39. Vachieri I, Damon M, Le Doucen C, et al. Increased oxygen species generation in blood monocytes of asthmatic patients. *Am Rev Respir Dis* 1992; 146:1161-6.
 40. Smith LJ, Houston M, Anderson J. Increased levels of glutathione in bronchoalveolar lavage fluid from patients with asthma. *Am Rev Respir Dis* 1993; 147:1461-4.
 41. Meltzer EO, Zeiger RS, Schats M, Jalowayski AA. Chronic rhinitis in infants and children: Etiologic, diagnostic, and therapeutic considerations. *Pediatr Clin N Am* 1983;30:47-71.
 42. Elsner J, Oppermann M, Czech W, et al. C3a activates reactive oxygen radical species production and intracellular calcium transients in human eosinophils. *Eur J Immunol* 1994;24: 518-22.
 43. Smith KC. The photobiological basis of low level laser radiation therapy. *Laser Ther* 1991;3:19-24.
 44. Friedman H, Lubart R, Lulicht I. A possible explanation of laser induced stimulation. *J Photochem Photobiol B: Biol* 1991;11:87-95.

*Request for reprints should be addressed to:
Ittai Neuman, MD
Department of Allergy & Asthma
Hasharon Hospital
Golda Medical Center
P O Box 141
Petah Tiqwa 49372
Israel*