

with linear skin defects syndrome without linear skin lesions. *J Hum Genet* 1999;44:63-68

- 6 Ogata T, Wakui K, Muroya K, et al. Microphthalmia with linear skin defects syndrome in a mosaic female infant with monosomy for the Xp22 region: molecular analysis of the Xp22 breakpoint and the X-inactivation pattern. *Hum Genet* 1998;103:51-56
- 7 Stratton RF, Walter CA, Paulgar BR, et al. Second 46,XX male with MLS syndrome. *Am J Med Genet* 1998;76:37-41

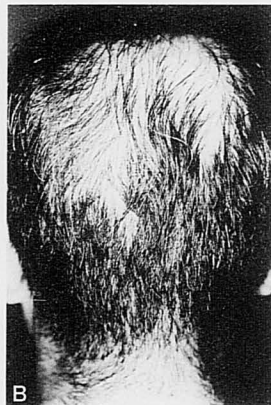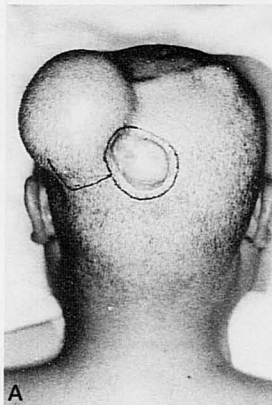
Simultaneous Use of a Tissue Expander and Skin Graft in Scalp Reconstruction

In scalp reconstruction, reconstruction of the hair is imperative from functional and cosmetic viewpoints. When the defect is large, there are few useful methods to effect repair other than tissue expansion. However, when this technique is applied to a preexisting defect, it is difficult to determine how the defect should be managed during skin expansion. Matthews and Missotten¹ and Kiyono and colleagues² managed the defect with artificial materials such as Eusol, paraffin, and Marlex mesh. On the other hand, Hodkinson³ and Wilmshurst and Sharpe⁴ managed facial defects with temporary skin grafting.

In 2 patients we performed a temporary skin graft to a scalp defect that was caused by resection of a malignant tumor and trauma respectively because, in both patients, galeal tissue could be retained (Fig A). A tissue expander was placed under adjacent normal scalp in a subgaleal plane through the defect. After 3 months, the grafted skin was removed and an expanded hair-bearing flap was transferred to the defect. Thirty months postoperatively, a good aesthetic result has been achieved in both patients (Fig B).

Disadvantages of this technique are that (1) sufficient observation and easy detection of recurrence may not be obtained in tumor reconstruction with a questionable margin, and that (2) potentially contaminated wounds are likely to lead to complications in the trauma reconstruction.

The use of skin grafting has several



(A) A malignant proliferating trichilemmal cyst recurred in the occipital area. After tumor resection, the tissue expander was placed under adjacent normal scalp through the defect, and was covered with a split-thickness skin graft from the back concomitantly. (B) Thirty months after the reconstruction, no local recurrence had occurred, and a good aesthetic result was obtained.

advantages compared with artificial materials. The greatest advantage is that special management is rarely required during expansion. There is also no increased susceptibility to infection during expansion, and the patient can take a bath during tissue expansion. In contrast, the skin graft has several disadvantages: scarring of the donor site, a change in shape of the grafted skin as a result of the tension exerted during skin expansion, and the defect must be covered with viable tissues (such as galea) to ensure graft take.

Tissue expansion with a temporary skin graft is one of the methods for reconstructing a preexisting defect in hair-bearing scalp.

Masamitsu Kuwahara, MD
Mitsuo Hatoko, MD, PhD
Aya Tanaka, MD
Satoshi Yurugi, MD
Kumi Mashiba, MD
Division of Plastic Surgery
Nara Medical University
840 Shijo-cho, Kashihara-City
Nara 634-0813, Japan
Address correspondence to Dr
Kuwahara.

References

- 1 Matthews RN, Missotten FE. Early tissue expansion to close a traumatic defect of scalp and pericranium. *Br J Plast Surg* 1986;39:417-421
- 2 Kiyono M, Matsuo K, Fujiwara T, et al. Repair of scalp defects using a tissue expander and Marlex mesh. *Plast Reconstr Surg* 1992;89:349-352
- 3 Hodkinson DJ. Skin graft as an alternative to Marlex mesh in conjunction with tissue expansion. *Plast Reconstr Surg* 1992;90:933-934
- 4 Wilmshurst AD, Sharpe DT. Immediate placement of tissue expanders in the management of large excisional defects on the face. *Br J Plast Surg* 1990;43:150-153

Pacinian Corpuscle Hyperplasia Coexisting With Dupuytren's Contracture

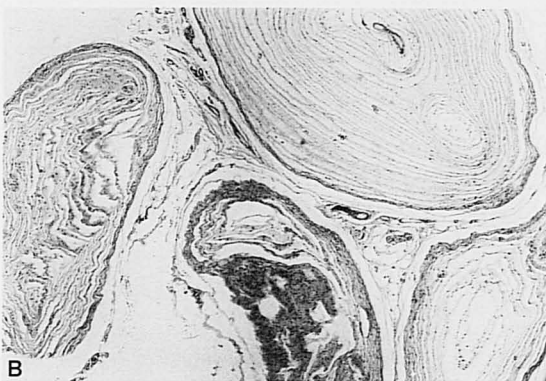
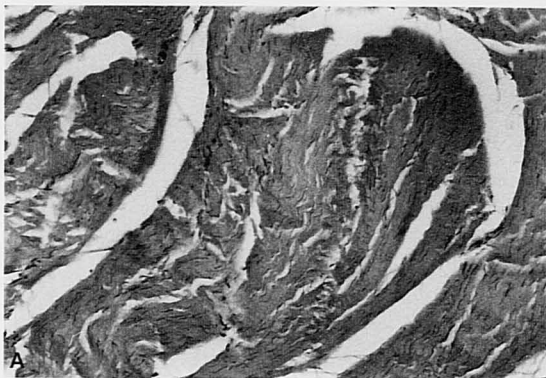
Pathological disorders of Pacinian corpuscles are very rare, and most are located within the hand. Pacinian corpuscle proliferation, usually located adjacent to the proximal digital nerves or in the distal phalanges, is accepted as true hyperplasia-

sia and has been reported in only 31 patients.

An 87-year-old woman presented with contracture of her right palm, which she had endured for more than 7 years. Although there was no pain, during past 2 years her symptoms had gradually increased and her hand function deteriorated. She was operated based on a diagnosis of Dupuytren's contracture. During the surgical procedure, multiple pearl-like, small nodules were noted in the distal metacarpal region, located mainly near the base of the second, third, and fourth digits. Along with these lesions, the entire palmar fascia was removed. Histopathologically, there were poorly defined fascicles of mature-appearing fibroblasts surrounded by abundant, dense collagen, which is consistent with Dupuytren's contracture (Fig A). In addition, the material contained numerous Pacinian corpuscles with a density between 10 to 15 corpuscles per square centimeter. The size of these corpuscles ranged from 1.5 to 2 mm in diameter, and they showed the classic structure of lamellae (Fig B).

Pacinian corpuscles were first described in 1742 by Vater, but it is Pacini who defined their histological structure in 1835.² These corpuscles are pearl-gray structures that measure 1 to 4 mm in length and are as thick as 2 mm. They are observed in the deep layer of the palmar corium, below sweat glands in the proximal and middle phalanges adjacent to the periosteum.³ Corpuscle clusters are usually located near nerves and vessels in the metacarpophalangeal and proximal phalangeal regions of the three central digits. Each Pacinian corpuscle consists of 13 to 15 concentric lamellae of connective tissue surrounding a central core that contains an unmyelinated nerve fiber. They serve as fine-touch and vibration receptors based on their rapidly adapting sensory ability.²

The main complaint associated with Pacinian corpuscle hyperplasia is incapacitating pain radiating to the hand and arm. However, loss of sensation may be the only



(A) Dupuytren's contracture characterized by densely collagenated stroma without an obvious cellular proliferation (H&E, original magnification $\times 100$ before 72% reduction). (B) Multiple concentric lamellae with a central core containing large clusters of Pacinian corpuscles ranging in size from 1.5 to 2 mm in diameter (H&E, original magnification $\times 40$ before 72% reduction).

symptom. Review of the literature revealed three cases of Pacinian corpuscle hyperplasia without local pain.⁴ Although rare, this proves that true hyperplasia can be seen without any associated pain, as in our patient. History of hand trauma is present in the majority of patients, and local steroid injection is another suspected factor.⁴ In our patient, in addition to true Pacinian corpuscle hyperplasia, there was Dupuytren's contracture as well.

It is not rare to observe some Pacinian corpuscles during hand

surgery, especially during surgery for Dupuytren's contracture, but these observations cannot be accepted as true hyperplasia because they must meet certain diagnostic criteria. Pacinian corpuscle disorders were classified by Rhode and Jennings⁵ into four types (A-D) according to their size, number, and location. The most common type is B, which consists of a grapelike cluster of normal size, and 3 to 5 Pacinian corpuscles per square centimeter attached to the digital nerve by a fine filament.⁴ Our patient

showed approximately 10 normal-size Pacinian corpuscles per square centimeter: type B.

The coexistence of Dupuytren's contracture with Pacinian corpuscle hyperplasia may reflect a close topographic relationship between the Pacinian corpuscles and the palmar fibromatosis of the hand.^{6,7} Although, Dupuytren's contracture and Pacinian corpuscle hyperplasia are two different entities, they share similar suspected etiological factors such as trauma. Despite the relative frequency of Dupuytren's contracture and the rare occurrence of Pacinian corpuscle disorders, the coexistence of these two disorders in our patient raises a question: Do these phenomena have an impact on each others' development or is this only a coincidence?

Nalan Akyürek, MD*
Ömür Ataoglu MD*
Seyhan Çenetoglu, MD†
Selahattin Özmen, MD†
Tarik Çavuşoglu, MD†
Reha Yavuzer, MD†

*Department of Pathology
†Department of Plastic and
Reconstructive Surgery
Gazi University Faculty of
Medicine
Ankara, Turkey
Address correspondence to Dr
Yavuzer
Barış Sitesi 87. Sokak No:24
06530 M. Kemal Mah
Ankara, Turkey

References

- 1 Reznik M, Thiry A, Fridman V. Painful hyperplasia and hypertrophy of Pacinian corpuscles in the hand: report of two cases with immunohistochemical and ultrastructural studies, and a review of the literature. *Am J Dermatopathol* 1998;20:203-207
- 2 Stark B, Carlstedt T, Hallin G, Risling M. Distribution of human Pacinian corpuscles in the hand. *J Hand Surg [Br]* 1998;23B:370-372
- 3 Cauna N, Mannan G. The structure of human digital Pacinian corpuscles (corpuscles lamellosa) and its functional significance. *J Anat (Lond)* 1958;92:1-20
- 4 Jones NF, Eadie P. Pacinian corpuscle hyperplasia in the hand. *J Hand Surg [Am]* 1991;16A:865-869
- 5 Rhode CM, Jennings WD. Pacinian

corpuscle neuroma of digital nerves. *South Med J* 1975;68:86-89

- 6 Jozsa L, Salamon A, Reffy A, et al. Fine structural alterations of the palmar aponeurosis in Dupuytren's contracture: a combined scanning and transmission electromicroscopic examination. *Zentralbl Allg Pathol* 1988;134:15-25
- 7 Tyrkko J, Viljanto J. Significance of histopathological findings in Dupuytren's contracture. *Ann Chir Gynaecol Fenn* 1975;64:288-291

Palliative Amputation for a Peculiar Case of Malignant Melanoma of the Lower Limbs

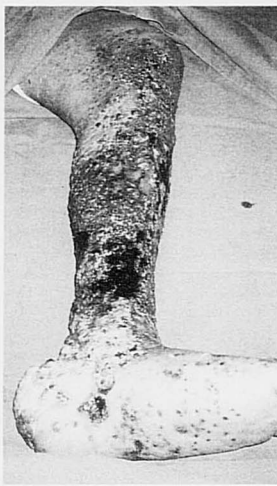Despite the merits of an early diagnosis and intervention as weapons against melanoma, we report a peculiar case of a 74-year-old white man affected by extensive melanoma of the left lower limb. The patient's medical history revealed that 3 years before presenting to our department he developed a hard nodule on the sole of the left foot that was excised surgically elsewhere.

Because of the recurrence of the lesion, which in approximately 4 months spread along the leg and up to the lower two thirds of the thigh, and because of a worsening in general condition, the patient was referred to our outpatient clinic and was admitted to our unit.

On arrival, physical examination of the lower left leg revealed multiple, dark, hard, painful, and fragile lesions on the foot, malleolus, leg, and lower two thirds of the thigh. This gave the limb the appearance of a large, lumpy, putrid sore, and it released a foul-smelling liquid (Fig). The patient's pain was intense. A biopsy of the lesion confirmed the clinical diagnosis of malignant melanoma.

The clinical and instrumental staging of the patient showed inguinal lymph node involvement, and an absence of internal organ involvement and metastases to the bone and of skin lesions in other regions. Two days after admission, the limb was amputated 4 cm below the coxofemoral joint, and superficial and deep inguinal lymph nodes were removed.

Histological examination of the lesion showed plurifocal infiltration of a scarcely differentiated malig-



Malignant melanoma affecting the entire lower limb.

nant melanoma and widespread metastatic tumor in all examined lymph nodes. The postoperative period was unremarkable and the patient died 13 months later as a result of cerebral metastasis.

This case is peculiar with regard to tumor size, clinical course, and treatment problems. The cancer spread rapidly from a node on the sole of the left foot to the entire leg. The finding of such a large, rapidly growing lesion without internal organ metastases poses several treatment problems. There are currently no uniform protocols to manage patients such as this. In agreement with others,¹⁻⁵ treating melanoma by partial or radical amputation of a limb is rare. Kourtesis and colleagues² report fewer than 1% of amputations, whereas Jacques and associates³ describe 58 cases of amputation resulting from melanoma at Memorial Sloan-Kettering Cancer Center in New York between 1965 and 1984. Ebskov⁴ reports Danish records from 1978 to 1987 with 31 amputations and a 5-year survival rate of 28%. We agree with the most widely held view that treating melanoma with limb ampu-