

Cytokine Manipulation of Explanted Dupuytren's Affected Human Palmar Fascia

M. ANN KUHN, WYAIT G. PAYNE, PHILIP C. KIERNEY, LEE L. Q. PU, PAUL D. SMITH, KATHERINE SIEGLER, FRANCIS KO, XUE WANG and MARTIN C. ROBSON*

Institute of Tissue Regeneration Repair and Rehabilitation, Department of Veterans Affairs Medical Center, Bay Pines, FL and The Department of Surgery, University of South Florida, Tampa, Florida

(Received May 24, 2000)

Introduction: Dupuytren's disease plagues human hands and digits producing fibrotic nodules and fascial cords with resultant debilitating flexion contracture deformities. Interest in this condition is great but because the disease is specific to humans and study has been hampered by the lack of an *in vivo* model. By utilizing an *in vivo* "nude" rat model it is possible to maintain and study explanted Dupuytren's contracted palmar fascia for prolonged periods of time.

Materials and Methods: Human specimens were divided into four, one for *in vitro* analysis, and three for model explantation. The explanted tissue was perfused with either transforming growth factor beta-2 (TGF β_2), its antibody, or a control vehicle. Explant biopsies were obtained at 30 and 60 days and compared to tissue prior to explantation. Immunohistochemistry of collagen I and III, DNA synthesis, protein production, and fibroblast kinetics were serially determined.

Results: Perfusion of explanted Dupuytren's tissue by TGF β_2 upregulated collagen I and III from biopsies obtained from the explants at 30 days when compared to vehicle control (P<0.001). Perfusion with antibody prevented this upregulation when compared to vehicle control (P<0.001). Cell cultures derived from fibroblasts obtained from biopsies of the explants perfused with TGF β_2 increased DNA synthesis, protein production and fibroblast kinetics.

Conclusion: These findings paralleled those from other fibroproliferative disorders suggesting a role for TGF β_2 in the pathogenesis of Dupuytren's contracture as well as possible novel treatment approaches.

Keywords: Dupuytren's Disease, Transforming growth factor beta, Transforming growth factor beta antibody, cytokines, sandwich-island flap

INTRODUCTION

It has been over 150 years since Dupuytren's initial description of a progressive fibrosis affecting human

hands and digits.[1,2] Interest in the commonly recognized entity of Dupuytren's disease has resulted in detailed study and precise characterization of its altered palmodigital anatomy. Anatomic descriptions

* Correspondence: Martin C. Robson, MD, Director Institute of Tissue Regeneration Repair and Rehabilitation Bay Pines VA Medical Center P.O. Box 5005 Bay Pines, FL 33744 Telephone: 727-398-9599 Fax: 727-319-1038 e-mail: mcrobson@earthlink.net

of such pathologic palmar fascia have been presented previously.[3,4] The desire to treat and liberate the hands compromised by Dupuytren's contracture remains widespread. Currently surgical fasciectomy with concomitant cord and nodule excision is recognized as the principal therapeutic modality for this condition while methods of effective medical therapy are currently under investigation.[5-8]

The flexion deformities localized to the palmodigital aponeurosis associated with Dupuytren's disease have been compared to other progressive human fibrotic conditions. It is postulated that many of the same factors that contribute to the development of other progressive human fibrotic conditions such as hypertrophic scar and keloid also play a role in the development of Dupuytren's disease.[9-17] In fact, it is known that a small percentage of Dupuytren's patients will be found to be afflicted with other fibrosing conditions.[18]

The mechanisms and biology responsible for abnormal human wound repair and the development of scar formation continue to be aggressively studied. An array of tissue cytokines orchestrate the sequence of normal wound repair. There are now significant data that demonstrate that cytokines also have critical roles in abnormal wound repair and the formation of various human proliferative-type scars. Evidence points to transforming growth factor beta ($TGF\beta$) as the key cytokine that initiates and terminates normal tissue repair, and with sustained production undertakes the development of pathologic progressive tissue fibrosis.[19] Recent data in animals suggest that persistent overexpression of dysregulated activation of the cytokine $TGF\beta$ may lead to proliferative scarring.[20,21]

$TGF\beta$ has been demonstrated to have a significant effect on Dupuytren's fibroblasts as well. With normal human skin as a control, mitogenesis of cultured Dupuytren's fibroblasts following treatment with exogenous $TGF\beta$ was documented.[22] Intracellular immunologic marking of both $TGF\beta_1$ and $TGF\beta_2$ in Dupuytren's nodule tissue explant *in vitro* studies have been confirmed.[23] The addition of exogenous isoforms $TGF\beta_1$ and $TGF\beta_2$ separately and in combination was significantly mitogenic for Dupuytren's

myofibroblasts versus control palmar fascia in these same *in vitro* experiments.[23] We have produced similar data for keloid fibroblasts. It has been demonstrated that $TGF\beta_2$ is significantly mitogenic for human keloid fibroblasts maintained in an *in vitro* cell culture environment compared to human control cultures.[24] Exogenous $TGF\beta_2$ treatment resulted in significantly increased procollagen production and DNA synthesis by these same human keloid fibroblast cultures.

Dupuytren's contracture is known to be a naturally occurring disease in humans only. This feature has restricted the investigation of Dupuytren's disease to *in vitro* techniques. A reproducible *in vivo* model is necessary for the dynamic study and biologic manipulation of human Dupuytren's affected palmar fascia. Dupuytren's lesions were produced in monkeys by traumatic disruption of palmar fascial fibers, but capacity for study purposes has been limited.[13] Dupuytren's affected palmar aponeurosis explants have been maintained in an athymic mouse from which characteristics of histologic and electron microscopic structural changes following extended specimen implantation were determined.[25] Our laboratory has perfected an *in vivo* (athymic) "nude" rat vascularized sandwich-island flap model that remedied the identical predicament for the proliferative dermal scars of keloid and hypertrophic scar which are also restricted to humans.[26] To date no comparable *in vivo* Dupuytren's contracture data exist and data obtained from keloid, non-burn hypertrophic scar, and burn hypertrophic scar confirm our ability to maintain human Dupuytren's tissue explants in this same *in vivo* "nude" rat model for extended periods.[27,28]

Numerous similarities appear to exist between Dupuytren's contracture fibroblast *in vitro* cell culture data and comparable keloid and burn hypertrophic and proliferative scar *in vitro* cell culture data. The influences exerted by the important tissue cytokine $TGF\beta$ on these various tissue cultures are also comparable as demonstrated by analogous *in vitro* biochemical and cell proliferation data. Therefore, this study utilizes the vascularized sandwich island flap in the "nude" rat as an *in vivo* model of Dupuytren's disease

and demonstrates biologic manipulation of Dupuytren's explants by $TGF\beta_2$ and its neutralizing antibody.

MATERIALS AND METHODS

Collection and General Characterization of Affected Dupuytren's Contracture Tissue

Specimens were obtained from human subjects who were undergoing elective Dupuytren's contracture release and fasciectomy independent of this study. Tissues were used immediately or stored at 4°C in RPMI-1640 with 10% fetal bovine serum (FBS) to which 20 µg/ml gentamicin and 2 µg/ml Amphotericin B had been added.[29,30] This methodology has been demonstrated to be successful for up to 72 hours.[29] Specimens were then divided into four pieces, three of which were placed into a sandwich island flap on individual "nude" rats as described later. The fourth piece was used for *in vitro* cell culture and proliferation kinetics.

Animal Care and Surgical Procedures

Outbred, congenitally "nude" (athymic) rats were purchased commercially (Harlan Sprague Dawley, Inc., Indianapolis, IN). All animals were male and weighed between 250 and 300 g. The animals were housed in pathogen-free barrier facilities, in cages with sealed air-filters, animal isolators, laminar flow units, and laminar flow rooms. All supplies including food, water, bedding, etc., were sterilized to prevent infection. Procedures recommended in the Guide for Care and Use of the Nude Mouse in Biomedical Research (Institute of Laboratory Animal Resources, 1976) were used at all times. Persons handling the rats wore caps, masks, sterile gowns and gloves, and shoe covers. All surgical operations on the "nude" rats were carried out under intraperitoneal Nembutal anesthesia, 35 mg/kg body weight, using aseptic surgical techniques. Operations

were performed under a unidirectional airflow biological hood. Surgical instruments were sterilized by autoclave technique and surgical sites were prepared with povidone iodine solution.

A total of 12 "nude" rats were used in this study. The prepared human specimens were explanted in the "nude" rats in a two-stage procedure as described by Polo and colleagues.[26] The first stage was creation of the sandwich flap. The abdominal skin of the rat was incised along three sides, creating a flap based on the superficial inferior epigastric pedicle. The width of the flap base was between 30 and 35 mm. The medial edge of the flap was located 5 mm from midline, and the cephalad edge of the flap was 10 mm caudal to the xiphoid process of the sternum. The prepared human Dupuytren's specimen was sutured to the inner surface of the flap. The flap was then returned to its bed, in the normal anatomic position. This surgical procedure resulted in a sandwich flap, which received the entirety of its blood supply from the superficial inferior epigastric vessels.

The final step in the preparation of the flap was initiated three weeks later. The femoral vessels, which arise 3-4 mm distal to the origin of the superficial inferior epigastric vessels were surgically isolated and divided thus maximizing blood flow into the sandwich flap through the superficial inferior epigastric vessels. The sandwich flap was then raised while isolated on its neurovascular pedicle (single artery, vein, and nerve) and tubed, converting it to a sandwich-island flap. The flap, on its isolated pedicle, was then moved through a subcutaneous tunnel to the ipsilateral flank where it was externalized and sutured in place on the dorsum of the rat. The abdominal donor site was closed primarily. The transfer of the island flap achieves two goals. It isolates the explanted specimen on a vascularized pedicle away from potential cannibalization as well as facilitates observation and accurate measurement of the specimens. Importantly, this provides an isolated vascular pedicle providing the blood to the explanted sample allowing for direct perfusion of cytokines and antibodies.

Biologic Manipulation of Dupuytren's Specimen Explants with Perfusion of TGF β_2 or Neutralizing Antibody to TGF β_2

The animals were divided into three equal groups and the Dupuytren's implants were directly perfused with 200 ng of recombinant human TGF β_2 (Genzyme, Framingham, MA)/sodium acetate; 250 μ g anti-TGF β_2 neutralizing antibody (Genzyme, Framingham, MA)/phosphate buffered saline (PBS); or PBS as a control vehicle. The total volume of each perfusion was 100 μ l. Perfusion was undertaken daily for 5 consecutive days, and again on days 10, 15, and 20. The amount of recombinant TGF β_2 was used because of a dose response curve demonstrating 200 ng to give the most marked response.[27] The antibody dosage was determined by using the same method. At 30 days following initiation of treatment, biopsies were obtained from each rat. At this time one half of the explant was removed. The biopsy specimen was divided into three parts. The first part was placed in 10% formalin solution and processed for light microscopy. The second part was immediately embedded in Histo Prep (Fisher Scientific, Pittsburgh, PA) and snap-frozen in liquid nitrogen. The tissue was then cut in 3 μ m sections on a cryostat at -20°C and mounted on polysialic acid glass slides in preparation for immunohistochemical staining of collagen I, and collagen III. The third part was used to evaluate growth kinetic responses. The rats were sacrificed on day 60 and the remaining explants were removed. Once again, the specimens were divided as on day 30 with one part used for light microscopy, one part used for immunohistochemical staining and one part used to evaluate growth kinetic responses.

Histology

The tissues were dehydrated through a graded series of ethanol, then similarly through xylene, and embedded in paraffin. The blocks were cut at about 5 μ m and the sections were stained with hematoxylin-eosin and Masson's trichrome stain. Masson's trichrome was utilized to document total collagen formation.

Immunohistochemistry for TGF β_2 , Collagen I and Collagen III

The immunohistochemical technique used was that validated for collagen I and collagen III by Shah, et al.[31] Cryosections were incubated with PBS for 30 minutes at room temperature. Sections were fixed in 4% paraformaldehyde for 20 minutes. Endogenous peroxidase was blocked by a 30 minute incubation in 1% hydrogen peroxide in PBS. After PBS washing, sections were incubated with diluted normal goat serum (1:10) to block nonspecific protein binding. Sections were then incubated for 2 hours at room temperature in a humidified chamber with rabbit antibodies specific for TGF β_2 (Santa Cruz Biotechnology, Inc. Santa Cruz, CA), diluted 1:50 in 1 percent BSA/PBS; and for collagen I and collagen III (Chemicon International Inc., Temecula, CA), diluted 1:20 in 1 percent BSA/PBS. Unbound antibody was removed by washing with PBS. Bound antibody was localized with biotinylated goat antibody. After applying ABC solution (Vector Labs, St. Louis, MO), 3,3-diaminobenzidine (DAB) with hydrogen peroxide was added as a substrate. Control staining was performed using PBS in place of the primary antibody and in place of the secondary antibody separately. At least two sections from each specimen were immunostained for TGF β_2 , collagen I and collagen III.

Quantification of Trichrome and Immunohistochemical Staining

Sections of Masson's trichrome staining and immunohistochemical staining were photographed using a Leitz Dialux microscope and Kodak Ektachrome 64 ASA film corrected for tungsten light. The photographs were then digitized using a standard desktop flatbed scanner. The staining was changed from blue (trichrome staining) or brown (immunostaining) into black on a white background. The intensity of staining was measured in ten randomly chosen noncontiguous and non-overlapping squares of each section using Sigma Scan (Jandel Scientific, Corte Madeira, CA). The intensity was measured between 0 to 255 (0 being no light intensity or black and 255 being the

greatest intensity or pure white). Because the staining was displayed as black on white, we subtracted the intensity measurement from 255 to depict greater staining with a higher value.

Cell Culture and Proliferation Kinetics

In vitro cell culture characteristics of Dupuytren's disease specimens prior to and following explantation and treatment were measured by assays for cellular proliferation and protein production. Biopsy specimens obtained from the "nude" rats and those obtained from human subjects were rinsed in 10 ml of calcium- and magnesium-free Dulbecco's phosphate-buffered saline (Sigma Chemical Co., St. Louis, MO) supplemented with gentamycin (20 mg/ml) for 30 minutes at room temperature. A second antibiotic rinse using 10,000 U/ml penicillin G, 25 µg/ml amphotericin B, and 10,000 µg/ml streptomycin sulfate solution (Gibco BRL, Grand Island, NY) was performed for 10 minutes. Each biopsy specimen was cut into 1–2 mm pieces, placed onto 60 mm culture dishes and incubated for 15 minutes at 37° C. A 10 ml aliquot of Dulbecco's modified Eagle's medium (DMEM; Gibco, BRL) was carefully and slowly added to the culture dish, which was then incubated at 37° C in 5% carbon dioxide. The cells were subcultured until 80% confluence was obtained by removing the medium and tissue fragments from the culture dish with calcium- and magnesium-free Dulbecco's phosphate-buffered saline solution (Gibco, BRL). Trypsin-ethylenediaminetetraacetic acid (0.25%) (Gibco BRL) was added, and the cultures were incubated at 37° C for 15 minutes. A 15 ml aliquot of soybean trypsin inhibitor (Sigma) was added. The cultures were centrifuged at 1000 g for 10 minutes. The supernatant was decanted and the cell pellets were resuspended in 5 ml Dulbecco's modified Eagle's medium. This rinse/wash and 5-minute centrifuge was repeated three times. Trypan blue dye exclusion was used to determine cell count and viability. The cells were counted using a hemocytometer, and their cell number was adjusted to 1×10^5 cells, which were then plated on a 35-mm Petri dish with 2 ml DMEM and 10% fetal bovine serum, and incubated at

37° C in 5% carbon dioxide. The medium was changed every 3 days. The four groups of biopsy specimens, those obtained directly from patients and those obtained from nude rats treated with vehicle control, TGF β_2 and TGF β_2 antibody were maintained in culture. Each group was duplicated 5 times. Samples from each group were removed on days 1, 3, 5 and 7 and were trypsinized, washed with PBS, centrifuged, and resuspended in 1 ml DMEM. The viability and cell count were determined using the Trypan Blue dye exclusion method and a hemocytometer.

Assessment of DNA synthesis was determined by ^3H -thymidine uptake of the cell lysate. A total of 2.0×10^4 fibroblast cells per well of a 96-well tissue culture plate (Dow Corning) were incubated at 37° C in 5% CO $_2$ and MEM. After 24 hours the cells were exposed to 1 microcurie/well of ^3H -thymidine (6.7 Ci/mmol) (New England Nuclear) for 24 hours. The supernatant was aspirated and the cells lysed by addition of 10mM Tris HCL (pH 7.5), 1 mM EDTA, 0.5% sodium dodecyl sulfate. Duplicate aliquots of cell lysate were precipitated with 1 volume of 20% trichloroacetic acid and 1 mg/ml salmon sperm DNA at -20° C for 30 minutes followed by centrifugation at 12,000 g for 15 minutes. The supernatant was aspirated and the precipitates were collected on glass fiber filters, dried, and quantified by liquid scintillation counting. DNA synthesis was expressed as disintegrations per minute (DPM) of tritium-thymidine in 24 hours per culture.

Total protein synthesized was determined by the ^3H -proline uptake of the cell lysate. This was assessed by placing 2.0×10^4 fibroblast cells/well into a 96-well tissue culture plate. Cells were incubated for 24 hours at 37° C in 5% CO $_2$ and MEM. The cells were exposed to 5 microCi/well of ^3H -proline for 24 hours. The supernatant was aspirated and the cells were lysed by addition of 10mM Tris HCL (pH 7.5), 1 mM EDTA, 0.5% sodium dodecyl sulfate. The lysate was precipitated for 30 minutes with 20% trichloroacetic acid, PBS and 1% BSA at -20° C. Total protein synthesized during the 24-hour labeling period was estimated by determining DPM of acid-precipitable protein in cell culture lysates. Precipitates were collected on glass fiber filters, dried, and quantified by liquid scintillation counting.

Statistical analysis

The numerical data between treatment and control groups derived from trichrome and immunohistochemical staining for collagen I and collagen III were compared using a one-way analysis of variance performed by Sigma Stat (Jandel Scientific, Corte Madera, CA). An all pairwise comparison procedure (Tukey's test) was performed for statistically significant differences verified upon ANOVA. Significant differences were determined to have a P value of less than 0.05.

Cell count was compared among the fibroblasts obtained from explanted specimens treated with vehicle control, TGF β_2 , and TGF β_2 antibody. The numerical data from each day (1, 3, 5, and 7) was compared using a one-way analysis of variance (SigmaStat, Jandel Scientific). An all pairwise comparison procedure (Tukey's test) was performed for statistically significant differences verified upon ANOVA. Significant differences were determined to have a P value of less than 0.05. Comparisons were made of fibroblasts cultured from biopsies obtained at both 30 and 60 days. Next, the fibroblasts obtained directly from patients and placed into cell culture were compared with fibroblasts cultured from biopsies obtained on 30 and 60 days that had undergone treatment with TGF β_2 . A one-way analysis of variance (SigmaStat, Jandel Scientific) was performed with an all pairwise comparison procedure (Tukey's test) performed for statistically significant differences verified upon ANOVA. Significant differences were determined to have a P value of less than 0.05.

Each data point from DNA synthesis and protein production was assayed in duplicate from duplicate cultures. The numerical data between patient control, vehicle control, TGF β_2 treated and TGF β_2 antibody treated were compared using a one-way analysis of variance. An all pairwise comparison procedure (Tukey's test) was performed for statistically significant differences verified upon ANOVA. Significant differences were determined to have a P value of less than 0.05.

RESULTS

The Dupuytren's Disease tissue explanted in the "nude" rats remained viable in this system without

any evidence of rejection during the 60 day study. Histological examination of the biopsies obtained at 30 and 60 days demonstrated maintenance of the parent human Dupuytren's tissue structure.

Masson's trichrome stain of biopsies obtained at 30 days showed a higher intensity of staining of the TGF β_2 group compared to control and TGF β_2 antibody treated groups ($P < 0.001$). There was also an increased intensity of staining of control compared to the TGF β_2 antibody treated group ($P < 0.001$). No statistically significant differences were observed with staining of biopsies obtained at 60 days. (Figure 1)

The immunohistochemical staining for collagen I of biopsies obtained at 30 days demonstrated that the group treated with TGF β_2 had increased intensity of staining compared to control and the TGF β_2 antibody treated groups ($P < 0.001$). There was also an increased intensity of staining of control compared to the TGF β_2 antibody treated group ($P < 0.001$). No statistically significant differences were observed with immunostaining of biopsies obtained at 60 days. (Figure 2)

The immunohistochemical staining for collagen III of biopsies obtained at 30 days also showed the group treated with TGF β_2 had increased intensity of staining compared to control and the TGF β_2 antibody treated groups ($P < 0.001$). As with collagen I staining, there was also increased intensity of staining of control compared to the TGF β_2 antibody treated group ($P < 0.001$). There were no statistically significant differences observed with immunostaining of biopsies obtained at 60 days. (Figure 3)

Biopsies of explanted Dupuytren's tissue obtained at 30 days grown in cell culture were compared with one another in terms of their cell growth kinetics. TGF β_2 appeared to stimulate the cells to reproduce and proliferate significantly more so than control ($P = 0.018$) and TGF β_2 antibody treated group ($P = 0.009$) by day 5 in culture. By day seven in culture the stimulation of the cells to reproduce and proliferate in the TGF β_2 treated group was significantly greater compared to the TGF β_2 antibody treated group ($P = 0.037$). (Figure 4) Biopsies of Dupuytren's tissue obtained at 60 days demonstrated an increase in the proliferative potential of the TGF β_2 treated group compared to control and the TGF β_2 antibody treated

**DUPUYTREN'S TREATED WITH TGF β 2
AND TGF β 2 ANTIBODY
MASSON'S TRICHROME STAIN**

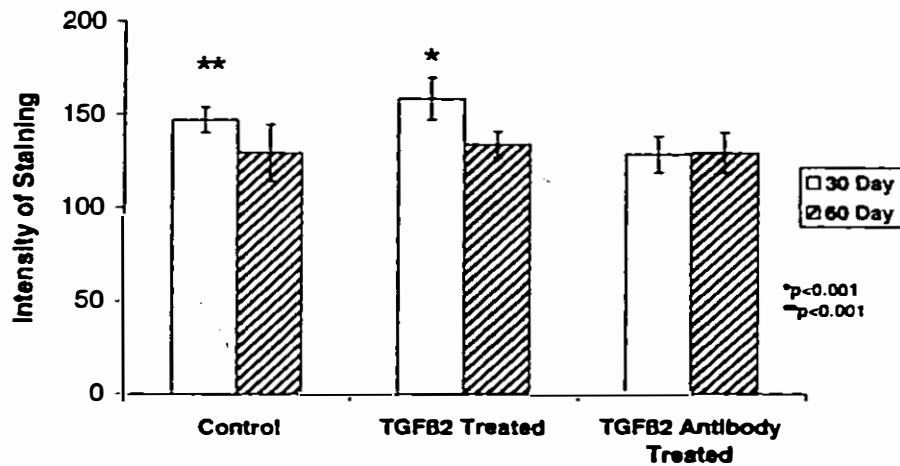


FIGURE 1 Masson's trichrome stain for collagen patterns shows a higher intensity of staining for the TGF β 2 treated group compared to the control and TGF β 2 antibody treated groups at 30 days ($P < 0.001$). There is also an increased intensity of staining of control compared to the TGF β 2 antibody treated group ($P < 0.001$)

**DUPUYTREN'S TREATED WITH TGF β 2
AND TGF β 2 ANTIBODY
COLLAGEN I IMMUNOSTAINING**

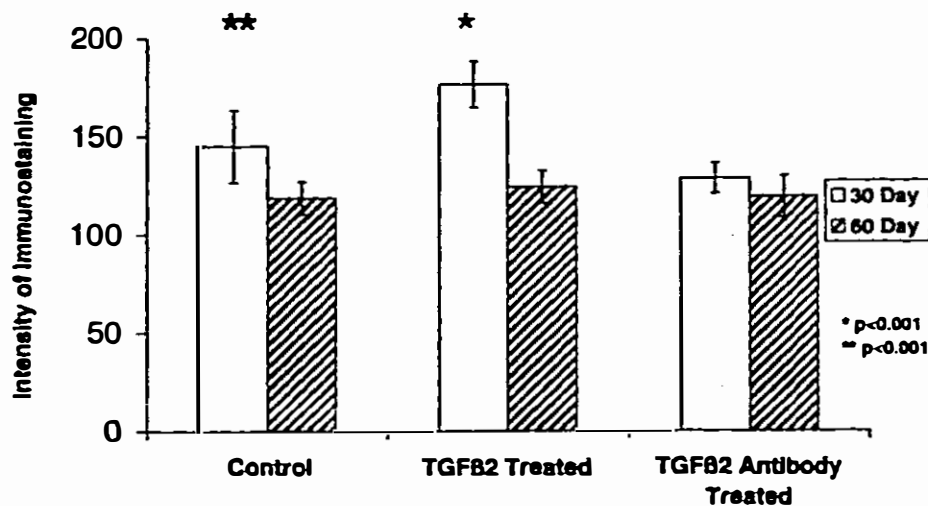


FIGURE 2 Immunohistochemical staining for collagen I shows the TGF β 2 treated group had an increased intensity of staining compared to control and the TGF β 2 antibody treated groups at 30 days ($P < 0.001$). This increase was also demonstrated when comparing control and the TGF β 2 antibody treated group ($P < 0.001$)

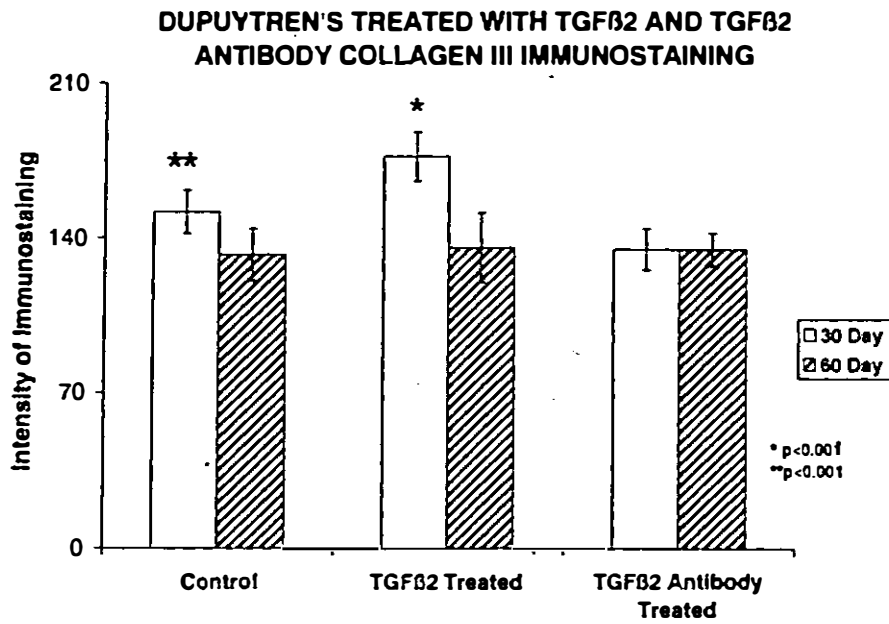


FIGURE 3 Immunohistochemical staining for collagen III at 30 days demonstrates an increased intensity of staining of the group treated with TGFβ₂ compared to control and TGFβ₂ antibody treated groups (P<0.001). There is also increased intensity of staining of control compared to the TGFβ₂ antibody treated group (P<0.001)

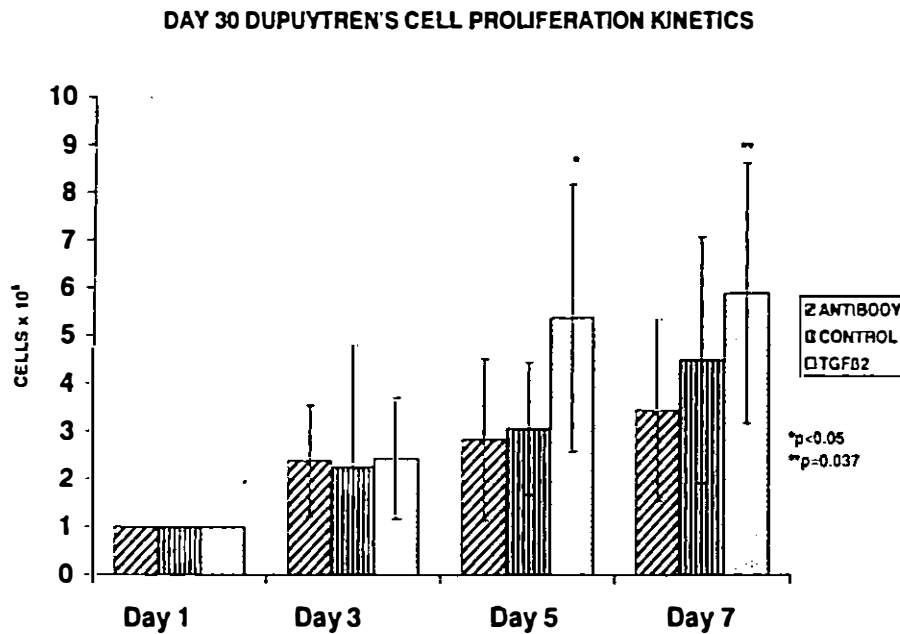


FIGURE 4 Dupuytren's cell proliferation kinetics of fibroblasts obtained from Dupuytren's explants treated with TGFβ₂ and biopsied at 30 days demonstrating an increase in cell number compared to fibroblasts obtained from Dupuytren's explants treated with control and fibroblasts obtained from Dupuytren's explants treated with TGFβ₂ antibody by day 5 (P=0.018 and 0.009 respectively). At day seven there was an increase in cell proliferation in the TGFβ₂ treated group compared to the TGFβ₂ antibody treated group (P<0.037)

DAY 60 DUPUYTREN'S CELL PROLIFERATION KINETICS

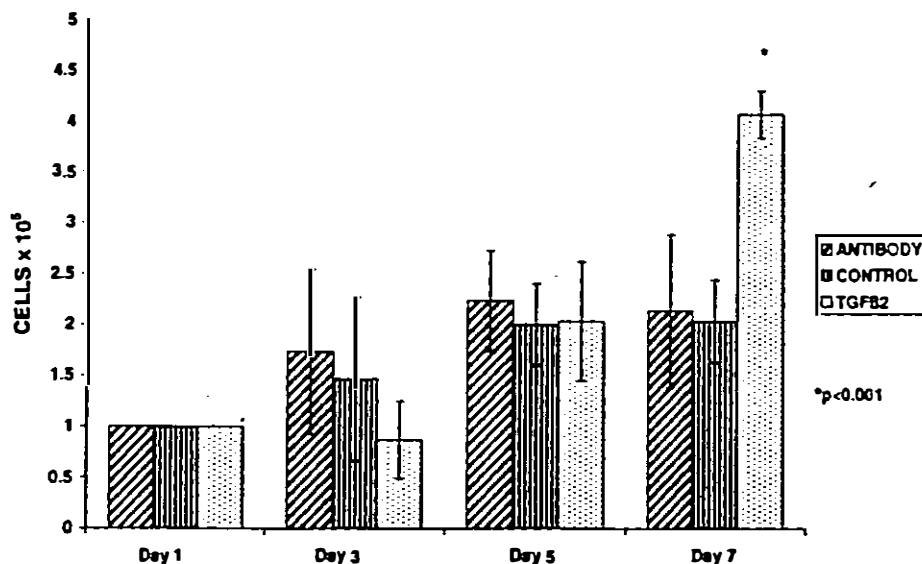


FIGURE 5 Dupuytren's cell proliferation kinetics at 60 days demonstrating an increase in cell number of fibroblast obtained from biopsies of explants treated with TGF β_2 compared to the fibroblasts obtained from biopsies of explants treated with vehicle and fibroblasts obtained from biopsies of explants treated with TGF β_2 antibody at day 7. ($P < 0.001$)

group ($P < 0.001$). (Figure 5) A comparison of the explanted Dupuytren's tissue treated with TGF β_2 and the Dupuytren's tissue immediately grown in cell culture without explantation demonstrates an increase in the proliferative potential of the 30 day TGF β_2 -treated group at both 5 and 7 days ($P < 0.05$). This proliferative potential was not demonstrated in cell cultures from biopsies obtained at 60 days in the TGF β_2 -treated group when compared to Dupuytren's tissue immediately placed into cell culture. (Figure 6)

TGF β_2 treatment significantly increased DNA synthesis in Dupuytren's fibroblasts at day 3 compared to Dupuytren's fibroblasts immediately placed into cell culture without explantation, explanted Dupuytren's fibroblasts cultured from those treated with vehicle only, and explanted Dupuytren's fibroblasts cultured from those treated with TGF β_2 antibody ($P < 0.05$). This increase in DNA synthesis in the TGF β_2 -treated fibroblasts persisted at day 5 when compared to vehi-

cle control ($P < 0.05$) and at day 7 when compared to Dupuytren's fibroblast immediately placed into cell culture, vehicle control and fibroblasts obtained from explants treated with TGF β_2 antibody. (Figure 7)

Total protein synthesized in Dupuytren's fibroblasts cultured from biopsies obtained from explants treated with TGF β_2 was significantly increased when compared to Dupuytren's fibroblasts placed immediately into cell culture without explantation, Dupuytren's fibroblasts obtained from explants treated with vehicle control, and Dupuytren's fibroblasts obtained from explants treated with TGF β_2 antibody. This increase was seen in days 3, 5, and 7 of tissue culture ($P < 0.05$) with the exception of fibroblasts obtained from biopsies of explants treated with TGF β_2 antibody on day 7. These fibroblasts demonstrated increased protein production compared to the fibroblasts obtained from biopsies of explants treated with TGF β_2 . (Figure 8)

DUPUYTREN'S CELL PROLIFERATION KINETICS

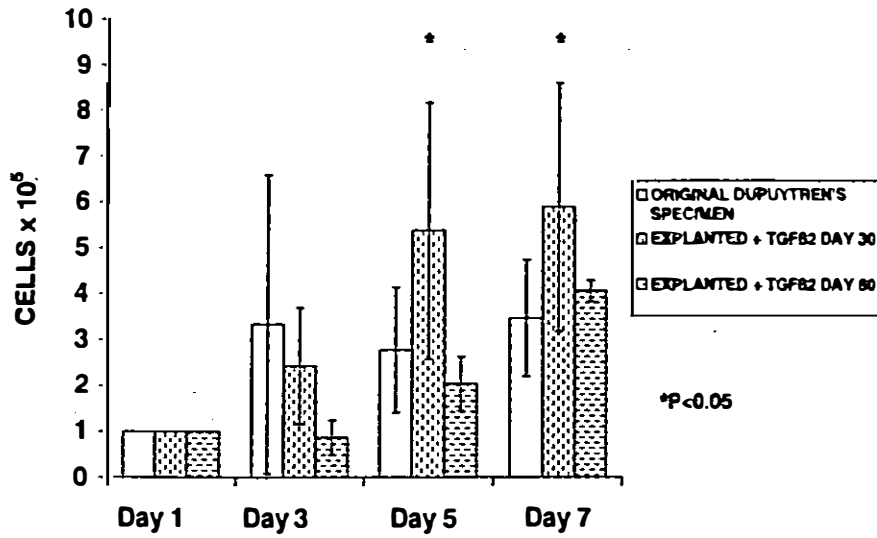


FIGURE 6 Dupuytren's cell proliferation kinetics of fibroblasts obtained from explanted Dupuytren's tissue treated with TGFβ₂ biopsied at days 30 and 60 demonstrates and increase in cell number by days 5 and 7 compared to fibroblasts obtained from Dupuytren's tissue placed immediately into cell culture (0.05)

DNA PRODUCTION

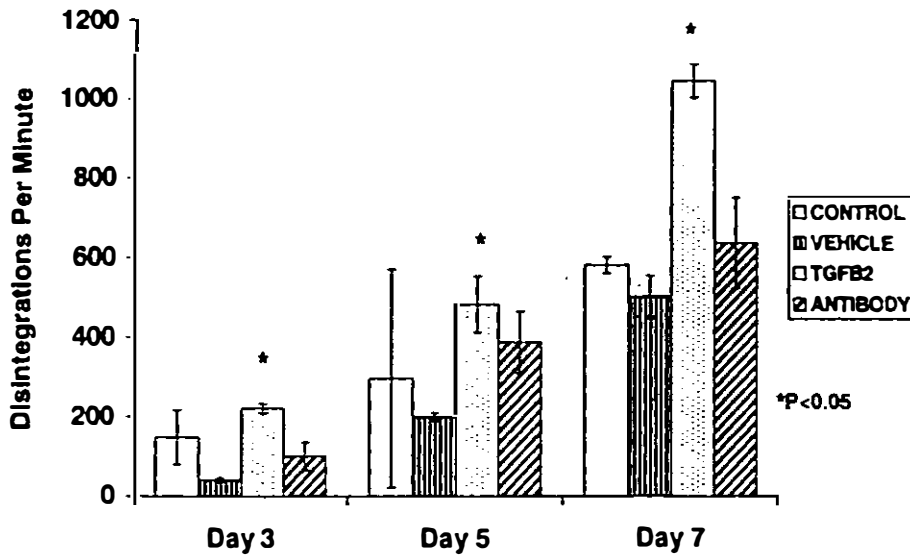


FIGURE 7 Determination of DNA synthesis demonstrates an increase of DNA production in fibroblasts obtained from explants treated with TGFβ₂ compared to fibroblasts obtained from explants treated with vehicle control at days 3, 5, and 7. (P<0.05) There was an increase of DNA production in fibroblasts obtained from explants treated with TGFβ₂ compared to Dupuytren's tissue placed immediately into cell culture and fibroblast obtained from explants treated with TGFβ₂ antibody on days 3 and 7 (P<0.05)

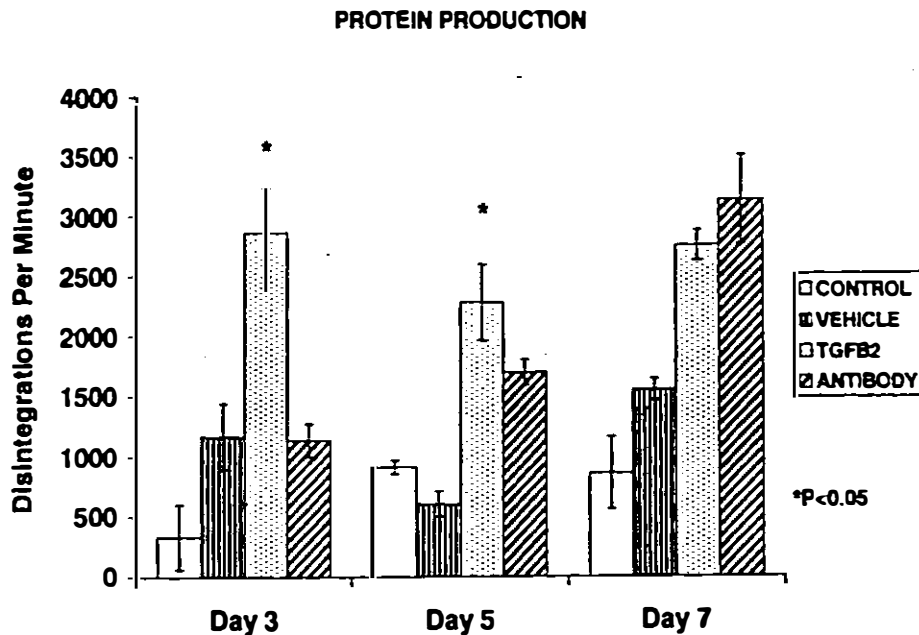


FIGURE 8 Determination of protein production demonstrates an increase in total protein synthesized in Dupuytren's fibroblasts cultured from biopsies obtained from explants treated with TGF β_2 compared to Dupuytren's fibroblasts placed immediately into cell culture and Dupuytren's fibroblasts obtained from explants treated with vehicle control on days 3, 5, and 7 and Dupuytren's fibroblasts obtained from explants treated with TGF β_2 antibody on days 3 and 5 (P<0.05)

DISCUSSION

By using the *in vivo* "nude" rat vascularized sandwich-island flap model, we have demonstrated significantly increased types I and III collagen production by Dupuytren's tissue xenografts after administration of exogenous TGF β_2 to such xenografts. We have also demonstrated significantly decreased types I and III collagen production by Dupuytren's tissue xenografts from biopsies obtained at 30 days after administration of exogenous TGF β_2 antibody to such xenografts. Biopsies obtained at 60 days did not show any statistical differences between the treatment groups however this may be explained by the timing of the last treatment dose. Treatment was ended at day 20 and the effects of treatment would likely have subsided by day 60. Tissue cultures developed from explants of these intra-flap maintained and TGF β_2 -treated Dupuytren's tissue also displayed increased cell proliferation kinetics with inhibition of these same bio-

logic effects consequent to treatment of the explants with neutralizing TGF β_2 antibody. These data are similar to previous data demonstrating increased types I and III collagen production by keloid and burn hypertrophic scar xenografts in an identical model.[32] Tissue cultures developed from explants of TGF β_2 treated keloid and hypertrophic burn scars also displayed increased *in vitro* cell proliferation kinetics and inhibition of these same biologic effects consequent to treatment of human keloid and proliferative scar with neutralizing TGF β_2 antibody.[27,28]

The increase in absolute cell number may represent either mitogenesis and increased cell proliferation or diminished apoptosis and thus a failure to undergo natural cell death. ^3H -Thymidine uptake and determination of DNA synthesis aid in delineating these processes. It is expected that increased fibroblast cell proliferation yields a concordant increase in DNA synthesis while a failure to undergo apoptosis is expected to result in a stable DNA volume. The

results demonstrate increased DNA synthesis in the explants treated with TGF β_2 which is similar to data obtained from keloid fibroblasts.[24] However, treatment of explants with TGF β_2 antibody did not show a significant decrease of DNA synthesis in the fibroblast cultures. This is likely explained by the fact that in the keloid studies the fibroblasts were cultured in the presence of TGF β_2 or TGF β_2 antibody whereas in this study the Dupuytren's explants were exposed while *in vivo* and no further treatment was given once the cells were placed in culture. It is likely the effect of TGF β_2 antibody treatment on the explants diminished greatly over the time the fibroblasts spent in culture. Protein production in fibroblasts cultured from Dupuytren's tissue explants was also similar to keloid data with TGF β_2 treatment significantly increasing protein production. However, after 7 days in culture protein production was increased in the antibody treated explants. Once again, the effects of the antibody on the explants may have diminished once the cells were placed in culture.

All recent evidence suggests that TGF β_1 and TGF β_2 are the key cytokines in scarring and fibrotic conditions.[19-21,33-39] It has been demonstrated that TGF β_2 plays an important role in the fibrogenic nature of Dupuytren's disease.[22,23] Fibroblasts are abundant within the affected palmar fascia and TGF β has been demonstrated to be a stimulus for both collagen and noncollagen production by these cells.[40-42] It follows that upregulation and an overall increase in total protein subsequent to TGF β_2 therapy versus levels produced by non-TGF β_2 treated fibroblasts support this postulate. More support for the role of TGF β_2 in Dupuytren's disease is the increased proliferation potential of fibroblasts isolated from TGF β_2 treated Dupuytren's palmar fascia compared to fresh non-TGF β_2 treated Dupuytren's palmar fascia.

Because Dupuytren's disease is known to naturally affect only humans, *in vivo* studies have been distinctly hampered. Scientific models have been difficult to define and of limited value. The "nude" rat vascularized island-sandwich flap allows successful maintenance of keloid, hypertrophic burn and hypertrophic scar explants. Published data confirm greater than one year survival of human explanted scar in this

"nude" rat model.[26] Our data also demonstrate maintenance of viable Dupuytren's affected palmar fascia explants for up to 60 days. The "nude" rat model ensures that proliferative scar specimens are exposed to an isolated vasculature unique to the flap. This anatomic feature allows for focal cytokine administration and resultant biologic manipulation of the secluded tissue specimens.

The etiology of Dupuytren's contracture remains unknown, but we theorize that Dupuytren's disease is pathobiologically related to the progressive fibrosing human physiologic disorders of keloid and proliferative scar formation. If stimulation of fibrosis by TGF β_2 plays a role in the pathogenesis of Dupuytren's disease, recent data supports new forms of treatment. Neutralizing antibodies to TGF β_1 and TGF β_2 have been demonstrated to reduce dermal scarring in rat dermal wounds.[31,43] TGF β_2 antibody has been demonstrated to decrease contraction of keloid or burn hypertrophic scar fibroblast-populated collagen lattices.[28] These observations have been extended to *in vivo* demonstrations that explanted human proliferative scar collagen production can be downregulated by TGF β_2 antibody.[32] There are other ways to attack over production of TGF β_1 and TGF β_2 . McCallion and Ferguson have used exogenous mannose-6-phosphate to reduce scarring in rodent, porcine, and human wounds.[44] Mannose-6-phosphate prevents activation of TGF β_1 by competitive inhibition of binding of the critical latency associated peptide (LAP).[19] Decorin protein has also been used in the central nervous system to decrease fibrotic scarring known to be secondary to TGF β_1 . [45] Decorin binds and neutralizes all three TGF β isoforms.[46] Tamoxifen can inhibit keloid fibroblast proliferation and decrease collagen production.[35] These actions have been reported to be due to a decrease in TGF β production.[47] Finally, Tredget, et al have been able to decrease the volume of hypertrophic scars with the use of systemic interferon alpha-2b.[48] The action appears to be secondary to the ability of interferon alpha-2b to normalize elevated levels of TGF β_1 and TGF β_2 .

By neutralizing or downregulating TGF β_2 , it may be possible to manipulate and control Dupuytren's

contracture in the clinical setting. The development of a pharmacologic anecdote able to halt this progressive and debilitating disease, or perhaps even reverse it human manifestations, may ultimately be possible.

Acknowledgements

Supported by a Department of Veterans Affairs Merit Review Grant, and grants from the American Society of Surgery for The Hand and The Plastic Surgery Educational Foundation

References

- Verheyden, C.N. (1983) The history of Dupuytren's contracture. *Clin. Plast. Surg.*, 10, 619-625.
- Dupuytren, B. (1834) Permanent retraction of the fingers produced by an affection of the palmar fascia. *Lancet*, 2, 222.
- McFarlane, R.M. (1974) Patterns of the diseased fascia in the fingers in Dupuytren's contracture. *Plas. Reconstr. Surg.*, 54, 31-44.
- McGrouther, D.A. (1982) The microanatomy of Dupuytren's contracture. *Hand*, 14, 215-236.
- Starkweather, K.D., Lattuga, S., Hurst, L.C., Badalamente, M.A., Guilak, F., Sampson, S. P., Dowd, A., Wisch, D. (1991) Collagenase in the treatment of Dupuytren's disease: An in vitro study. *J. Hand Surg.*, 21A, 490-495.
- Hurst, L.C., Badalamente, M.A., Makowski, J. (1986) The pathobiology of Dupuytren's contracture: Effects of prostaglandins on myofibroblasts. *J. Hand Surg.* II, 18-22.
- Hurst, L.C., Badalamente, M.A. (1999) Nonoperative treatment of Dupuytren's disease. *Hand Clin.*, 15, 97-107.
- Badalamente, M.A., Hurst, L.C., Sampson, S.P. (1988) Prostaglandins influence myofibroblast contractility in Dupuytren's disease. *J. Hand Surg.*, 13A, 867-871.
- Kischer, C.W., Theis, A.C., Chvapil, M. (1982) Perivascular myofibroblasts and microvascular occlusion in hypertrophic scars and keloids. *Hum. Pathol.*, 13, 819-824.
- Brickley-Parsons, D., Glimcher, M., Smith, R., Albin, R., Adams, J. (1981) Biochemical changes in the collagen of the palmar fascia in patients with Dupuytren's disease. *J. Bone Joint Surg.*, 63A, 787-797.
- Hunter, J., Ogdon, C., Norris, M.G. (1975) Dupuytren's contracture. I Chemical pathology. *Br. J. Plast. Surg.*, 28, 10-18.
- Viljanto, J., Seppala, P.O., Lehtonen, A. (1971) Chemical changes underlying Dupuytren's contracture. *Ann. Rheumat. Dis.*, 30, 423-427.
- Larsen, R., Takagishi, N., Posch, J. (1960) The pathogenesis of Dupuytren's contracture. Experimental and further clinical observations. *J. Bone Joint Surg.*, 42A, 993-1007.
- Badalamente, M.A., Hurst, L.C. (1999) The biochemistry of Dupuytren's disease. *Hand Clin.*, 15, 35-42.
- Gelberman, R.H., Amiel, D., Rudolph, R.M., Vance, R.M. (1980) Dupuytren's contracture. An electron microscopic, biochemical and clinical correlative study. *J. Bone Joint Surg.*, 62A, 425-432.
- Bazin, S., Le Lous, M., Duance, V.C., Sims, T.J., Bailey, A.J., Gabbiani, G., D'Andiran, G., Pizzolato, G., Browski, A., Nicoletis, C., Delaunay A. (1980) Biochemistry and histology of the connective tissue of Dupuytren's lesions. *Eur. J. Clin. Invest.*, 10, 9-16.
- Murrell, G.A. (1991) The role of the fibroblast in Dupuytren's contracture. *Hand Clin.*, 7, 669-681.
- Gonzalez-Martinez, R., Marin-Berolin, S., Amor-rortu-Velayos, J. (1995) Association between keloids and Dupuytren's disease: Case report. *Br. J. Plast. Surg.*, 48, 47-48.
- O'Kane, S., Ferguson, M.W.J. (1997) Transforming growth factor β s and wound healing. *Int. J. Biochem. Cell Biol.*, 29, 63-78.
- Border, W.A., Noble, N.A. (1994) Transforming growth factor beta in tissue fibrosis. *NEJM*, 331, 1266-1292.
- Border, W.A., Rouslahti, E. (1992) Transforming growth factor beta in disease: The dark side of tissue repair. *J. Clin. Invest.*, 90, 1-7.
- Kloen, P., Jennings, C.L., Gehhardt, M.C., Springfield, D.S., Mankin, H.J. (1995) Transforming growth factor beta: Possible roles in Dupuytren's contracture. *J. Hand Surg.*, 20, 101-108.
- Badalamente, M.A., Sampson, S.P., Hurst, L.C., Dowd, A., Miyasaka, K. (1996) The role of transforming growth factor beta in Dupuytren's disease. *J. Hand Surg.*, 21A, 210-215.
- Smith, P.D., Siegler, K., Wang, X., Robson, M.C. (1998) Transforming growth factor β_2 increases DNA synthesis and collagen production in keloid fibroblasts. *Surgical Forum*, XLIX, 617-619.
- Kischer, C.W., Pindur, J., Madden, J., Shetlar, M.R., Shetlar, C.L. (1989) Characterization of implants from Dupuytren's contracture tissue in the nude (athymic) mouse (42859). *Proc. Soc. Exp. Biol. Med.*, 190, 268-274.
- Polo, M., Kim, Y.J., Kucukcelebi, A., Hayward, P.G., Ko, F., Robson, M.C. (1998) An in vivo model of human proliferative scar. *J. Surg. Res.*, 74, 187-195.
- Polo, M., Smith, P.D., Kim, Y., Wang, X., Ko, F., Robson, M. (1999) Effect of TGF- β_2 on proliferative scar fibroblast cell kinetics. *Ann. Plast. Surg.*, 43, 185-190.
- Smith, P., Mosiello, G., Deluca, L., Ko, F., Maggi, S., Robson, M.C. (1999) TGF- β_2 activates proliferative scar fibroblasts. *J. Surg. Res.*, 82, 319-323.
- Krueger, G.G., Wojciechowski, Z.J., Burton, S.A., Gilha, A., Huther, S.E., Leonard, L.G., Rohr, W.D., Petelenz, T.J., Higuchi, W.I., Pershing, L.K. (1985) The development of a rat/human skin flap served by a defined and accessible vasculature on a congenitally athymic (nude) rat. *Fundamental and Appl. Toxicol.*, 5, S112-S121.
- Garner, W.L., Karmiol, S., Rodriguez, J.L., Smith, D.J., Jr., Phan, S.H. (1993) Phenotypic differences in cytokine responsiveness of hypertrophic scar versus normal dermal fibroblasts. *J. Invest. Dermatol.*, 101, 875-879.
- Shah, M., Foreman, D., Ferguson, M. (1994) Neutralizing antibody to TGF- $\beta_{1,2}$ reduces cutaneous scarring in adult rodents. *J. Cell Science*, 107, 1137-1157.
- Wang, X., Smith, P., Pu, L.L.Q., Kim, Y.J., Ko, F., Robson, M.C. (1999) Exogenous TGF- β_2 modulates collagen I and collagen III synthesis in proliferative scar xenografts in nude rats. *J. Surg. Res.*, 87, 194-200.
- Younai, S., Nichter, L.S., Wellisz, T., Reinisch, J., Nimni, M.E., Tuan, T.L. (1994) Modulation of collagen synthesis by transforming growth factor-beta in keloid and hypertrophic scar fibroblasts. *Ann. Plast. Surg.*, 33, 148-151.
- Younai, S., Venters, G., Vu, S., Nichter, L., Nimni, M., Tuan, T.L. (1996) Role of growth factors in scar contraction: An in vitro analysis. *Ann. Plas. Surg.*, 36, 495-501.
- Lee, T.Y., Chin, G.S., Kim, W.J.H., Chau, D., Gittes, G.K., Longaker, M.T. (1999) Expression of transforming growth

- factor beta 1, 2, and 3 proteins in keloids. *Ann. Plast. Surg.*, 43, 179-184.
36. Shah, M., Foreman, D.M., Ferguson, M.W. (1995) Neutralization of TGF-beta 1 and TGF-beta 2 or exogenous addition of TGF-beta 3 to cutaneous rat wounds reduces scarring. *J. Cell Sci.*, 108, 985-1002.
 37. Cox, D.A. Transforming growth factor beta-3. (1995) *Cell. Biol. Int.*, 19, 357-370.
 38. Kuhn, A., Singh, S., Smith, P.D., Ko, F., Falcone, R., Lyle, W.G., Maggi, S.P., Wells, K.E., Robson, M.C. (2000) Periprosthetic breast capsules contain the fibrogenic cytokines TGF- β 1 and TGF- β 2, suggesting possible new treatment approaches. *Ann. Plast. Surg.*, 44, 387-391.
 39. Fu, L.L.Q., Smith, P.D., Wang, X., Payne, W.G., Kuhn, M.A., Ko, F., Robson, M.C. Overexpression of transforming growth factor beta-2 and its receptor in rhinophyma: An alternative mechanism of pathobiology. *Ann. Plas. Surg.* (in press).
 40. Alioto, R.J., Rosier, R.N., Burton, R.I., Puzas, J.E. (1994) Comparative effects of growth factors on fibroblasts of Dupuytren's tissue and normal palmar fascia. *J. Hand Surg.*, 19A, 442-452.
 41. Berndt, A., Kosmehl, H., Mandel, U., Gabler, U., Luo, X., Celeda, D., Zardi, L., Katenkamp, D. (1995) TGF beta and bFGF synthesis and localization in Dupuytren's disease (nodular palmar fibromatosis) relative to cellular activity, myofibroblast phenotype and oncofetal variants of fibronectin. *Histochem. J.*, 27, 1014-1120.
 42. Igarashi, A. (1996) Connective tissue growth factor gene expression in tissue sections from localized scleroderma, keloid, and other fibrotic skin disorders. *J. Invest. Dermatol.*, 106, 729-733.
 43. Shah, M., Foreman, D.M., Ferguson, M.W.J. (1992) Control of scarring in adult wounds by neutralizing antibody to transforming growth factor β . *Lancet*, 339, 213-214.
 44. McCallion, R.L., Ferguson, M.W.J. (1996) Fetal wound healing and the development of antiscarring therapies for adult wound healing. In: Clark, R.A.F., ed. *The molecular and cellular biology of wound repair*. New York: Plenum Press, 561-600.
 45. Logan, A., Berry, M., Gonzalez, M., Frautsching, S.A., Sporn, M.B., Baird, A. (1994) Effects of transforming growth factor- β 1 on scar production in the injured central nervous system of the rat. *Europ. J. Neurosci.*, 6, 355-363.
 46. Hildebrand, A., Romaris, M., Rasmussen, L.M., Heingard, D., Twardzik, D.R., Border, W.A., Ruoslahti, E. (1994) Interaction of the small interstitial proteoglycans biglycan, decorin, and fibromodulin with transforming growth factor beta. *Biochem. J.*, 302, 527-534.
 47. Chau, D., Mancoll, J.S., Lee, S., Zhao, J., Phillips, L.G., Gittes, G.R., Longaker, M.T. (1998) Tamoxifen downregulates TGF-beta production in keloid fibroblasts. *Ann. Plast. Surg.*, 40, 490-493.
 48. Tredget, E.E., Shankowsky, H.A., Pannu, R., Nedelec, B., Iwashina, T., Ghahary, A., Taerum, T.V., Scott, P.G. (1998) Transforming growth factor- β in thermally injured patients with hypertrophic scars: Effects of interferon alpha-2b. *Plast. Reconstr. Surg.*, 102, 1317-1328.