

Dupuytren's Disease

Dupuytren's disease (sweat producing tumour) is a disorder of the connective tissues, manifested by nodularity, thickening, and contractures in the palm, with extensions into the digits in a classic pattern (Fig. 26-1).

Although the disorder was known for centuries, it took its name from the influential French surgeon Baron Guillaume Dupuytren (1777-1835), who presented his thesis on the subject to the Academy of Science in Paris in 1832. Dupuytren maintained that the condition was a disease of the palmar fascia that developed in response to repetitive trauma and should be treated by fasciotomy.

In 1834, Dr. G. Goyrand of Aix-en-Provence presented his concepts with precise details that conflicted sharply with those of Dupuytren. Goyrand believed that it was a disease beginning in the fibrofatty tissues between the skin and palmar fascia, that the contracting bands were newly formed tissue rather than modifications of existing fascia, that repetitive trauma played no part in its development, and that the treatment should be excision of the diseased tissues.

Concerning repetitive trauma, Goyrand gave the example of the local banker having the worst contractures he had seen and assured everyone that the fellow had never done a lick of work in his life. The conclusions of Goyrand are essentially those held currently about the disorder.

Etiology

Dupuytren's disease is genetically determined by a single dominant gene of variable penetrance, appearing in those with a northern European heritage. It could be called the "Viking disease" from its area of apparent origin. The frequency of occurrence correlates closely with the pattern of Viking penetrations history records. It is only occasionally found among Asians and is rare among blacks.

Dupuytren's disease will develop only in genetically susceptible individuals, and their diathesis determines its severity. It also develops more frequently among men than women. The ratio depends upon the age of the group surveyed and the source of the data. Hospital records show a ratio of men to women of 7:1, but in very elderly groups the difference in ratio of male to female narrows to almost 1:1. The average ratio appears to be about 5:1. Dupuytren's disease is rare before the age of 40 and almost unknown before the age of 20. Incidence increases steadily with the age of the population surveyed. In a highly susceptible population, such as Scandinavia, the incidence among males rises from about 4% of those below age 40 to 40% of those in the 80-year-old group.

Other Etiologic Factors of Dupuytren's Disease

An increased incidence of Dupuytren's disease among epileptics, chronic invalids, and alcoholics

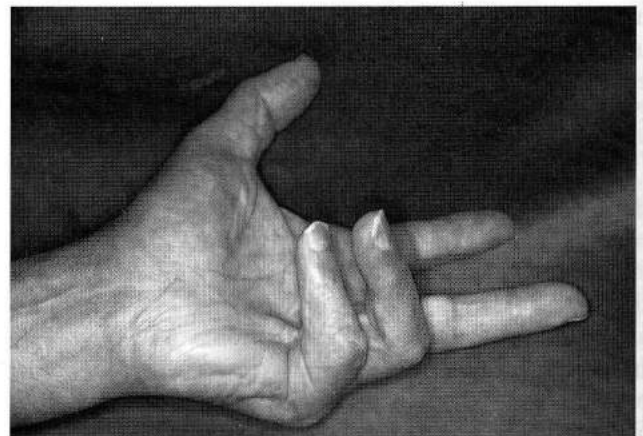


FIGURE 26-1 (A). Typical established Dupuytren's disease. It can involve any part of the hand, but usually the medial side (middle, ring, and small fingers) is most involved.

has been reported without explanation. A casual relation to diabetes mellitus has not been established, but diabetic patients having fasciectomy should be warned that a protracted course of soreness and even joint inflammation is frequent.

One must be very careful in assigning nongenetic etiologic factors. For example, once it was claimed that there is an occupational cause of the disorder in the beer brewing industry. It was not recognized that almost all brewers are of German, Irish, or Scandinavian descent, all genetically very susceptible groups!

RELATION TO OCCUPATION

Large statistical studies have failed to support the contention that Dupuytren's disease develops in response to repetitive trauma. The fact that a patient uses his or her hands in heavy or repetitive activities simply does not necessarily mean the tissues are being damaged. In fact, it is disuse of limbs that is associated with deterioration. The controversy over the possible relation of Dupuytren's disease to single-incident trauma probably stems from the general

failure to distinguish traumatic fasciitis from genetically determined Dupuytren's disease.

Dupuytren's Disease versus Traumatic Palmar Fasciitis

Contractures often reported as Dupuytren's disease may be traumatic palmar fasciitis, which can be produced by single-incident trauma (Fig. 26-2). Histologically, palmar fasciitis cannot be distinguished from Dupuytren's disease, but clinically, there are major differences. Palmar fasciitis develops unpredictably in response to a single trauma that can be blunt, but more often to small penetrating or minor incised wounds, such as surgical release of a "trigger finger" (Fig. 26-3). Its development is completely unpredictable, but it usually occurs among young patients, and often within days following a specific single-incident trauma. Its contracture typically progresses very rapidly in contrast to that of Dupuytren's disease. The resulting pain varies, but most often it is a severe burning type that does not respond to either systemic or locally injected steroids. Palmar fasciitis tends to be

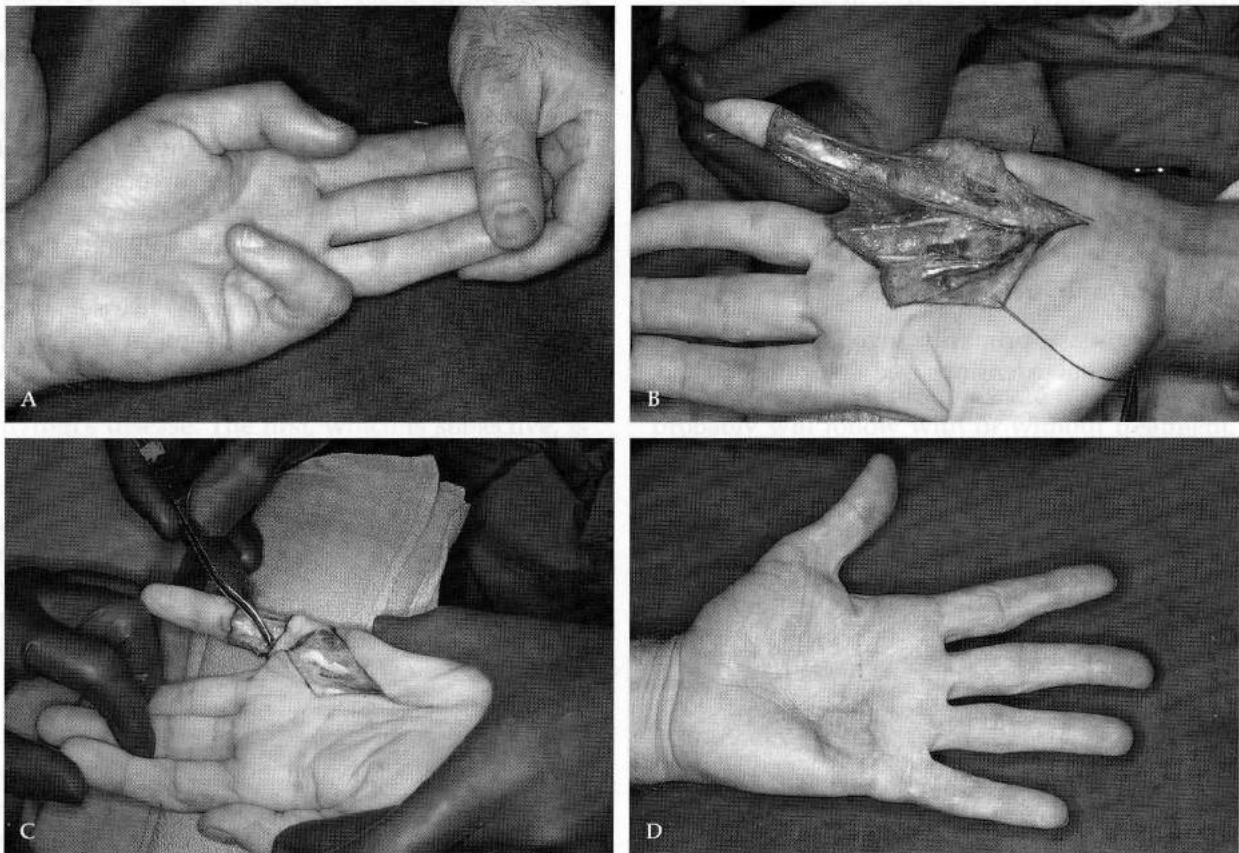


FIGURE 26-2 (A). A 24-year-old male with three-time recurrent palmar fasciitis following puncture wounds of a dog bite. He presented with a misdiagnosis of Dupuytren's disease, which appears the same but clinically behaves in a totally different manner. (B). Treatment by excision of involved skin and fascia. (C). Local flap brought across the fifth metacarpophalangeal (MP) joint to provide mobile subcutaneous flap tissues there. (D). Eight-year follow-up without further recurrences.

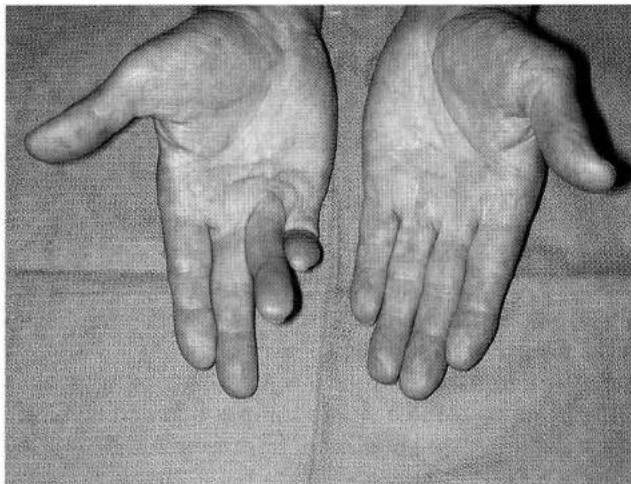


FIGURE 26-3 (A). Painful palmar fasciitis developing 3 weeks after "trigger finger" releases of ring and small fingers, a traumatic fasciitis misdiagnosed as Dupuytren's disease.

very aggressive with a very high incidence of recurrence after fasciectomy. In many ways it is similar to plantar fasciitis, a condition of the feet that is renowned for not responding to conservative treatment and being enormously disabling.

Limited fasciectomy for traumatic fasciitis is almost invariably followed by rapid recurrence of the disorder with persistence of pain. My limited experience with this rare problem is that excision of the diseased fascia along with the overlying skin followed by skin grafting is an effective treatment for these cases, as it is for recurrent Dupuytren's disease.

Pathology of Dupuytren's Disease

Dupuytren's disease primarily involves the palmar fascia and its digital extensions (see Color Plate 9) and

only secondarily the skin, joints, and other structures. The pathology of Dupuytren's disease is conveniently considered in three phases: (1) early or nodular, (2) active or contractile, and (3) late with fixed cords and deformity.

The onset of the disease most often is heralded by the appearance of a nontender nodule or puckering of the skin, generally on the medial side of the palm at the distal palmar crease. Occasionally the first indication may be the appearance of an unexplained painless contracture of a finger joint. Microscopically the nodule is composed predominantly of actively proliferating fibroblasts. The nodules lie in the fibrofatty tissues between the deep dermis of the skin and the palmar fascia to which they become attached. Neither the deep side of the palmar fascia nor the deeper transverse component of the palmar fascia is ever involved (Fig. 26-4), as noted by Skoog (1948). However, the extension of the transverse fascia across the thumb-index finger web is subjected to longitudinal stressing and often is found to be contracted as a thick cord.

Progression of nodules to cords is unpredictable. Histologically, the predominant cell at the second phase is the myofibrocyte described by Gabbiani and Majno. The myofibroblasts have the characteristics of smooth muscle cells and fibroblasts, both morphologically and in their chemical responses. They provide the contractile forces of deformity, which becomes fixed in the third or late phase by the deposition of the fibrotic tissues that characterize mature Dupuytren's disease. These late unyielding cords contain dense, highly polarized collagen bundles with very few cells; chiefly mature fibrocytes, which are found in granulation tissues. With Dupuytren's disease, type III collagen often rises to 40%. Chemical abnormalities are found in the fibrofatty tissues of patients with

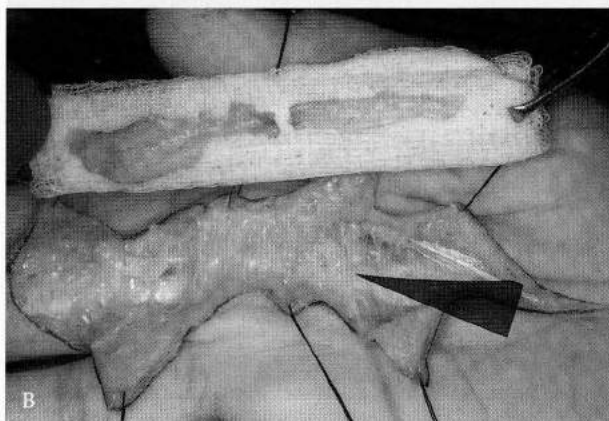
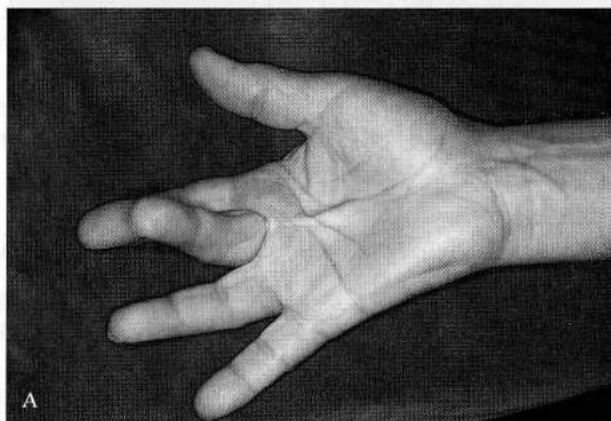


FIGURE 26-4 (A). Typical Dupuytren's contractures. (B). After excision of the diseased longitudinal components of the palmar fascia with preservation, the normal transverse components, which are always superficial to the neurovascular bundles.

Dupuytren's disease. This adds evidence on the hypothesis that the location of the inciting chemicals is in the fibrofatty tissues of the deep subdermis. The latter is the basis for treating recurrent disease by excision of involved skin along with the contracted fascia.

There are a number of unexplained observations. One is the consistent tortuosity of the ulnar artery. Another is that pacinian corpuscles encountered during surgery are often of remarkable size, as much as several millimeters in diameter. Still another is the fact that rarely are the deformities symmetrical between the two hands, even though the chemistries should be the same. The significance of these various observations is unknown.

ASSOCIATED PATHOLOGY

Nodules may develop in the plantar fascia of the feet in patients either with or without hand disease. Clinically, these nodules are different. The disease of the fascia in the feet, unlike that of the hands, generally is characterized by tender and painful nodules. This constitutes the chief complaint. Additionally, the excision of the lesions of the plantar fascia is followed by an extremely high incidence of recurrence compared with fasciectomy of the hands. These observations suggest that plantar fasciitis may be a traumatic fasciitis rather than a variant of Dupuytren's disease.

The association of Peyronie's disease, a fibrous anterior band contracture of the penis, with Dupuytren's disease is also questionable. This rare lesion tends to stabilize, and there may even be spontaneous regression.

Indications for Treatment

Essentially, there are two indications for treatment of Dupuytren's disease. The first, which is subjective, is if any contracture progresses to the point that it constitutes a physical impairment. The mere presence of the disease is not an indication for treatment, and there is no place for a prophylactic fasciectomy.

The second indication for treatment is objective, the same for everyone. It is if any PIP finger joint becomes significantly contracted. Opinions of what is significant vary greatly. McFarland (1990) has suggested that surgical release should be recommended as soon as any PIP joint contracture is recognized. This clearly is too aggressive for a problem whose course is unpredictable. The tight-fitting PIP joints, unlike the metacarpophalangeal (MP) joints, undergo anatomic changes when chronically and severely flexed, and relief without creating instability becomes increasingly difficult. A PIP joint contracture of 25 degrees or greater is a clear indication to consider surgical

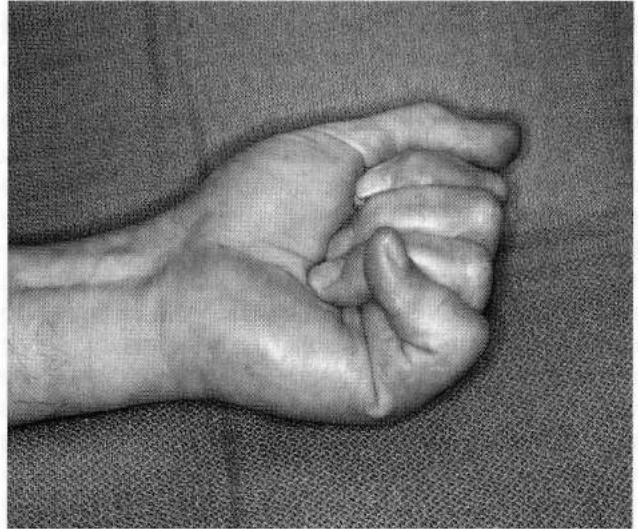

FIGURE 26-5 Flexion contractures of a finger's distal interphalangeal (DIP) joints are rare. Typically, there is DIP hyperextension, which is difficult to correct.

correction. Unlike the tight-fitting PIP joints, more severe MP joint contractures can be released successfully, but the majority of patients will find MP contractures of 40 degrees or more to cause sufficient awkwardness to request correction.

Flexion contractures of distal interphalangeal (DIP) joints are rare. The frequent problem with DIP joints (in keeping with the zig-zag concept of Landsmeer) is their loss of flexion or even rigid hyperextension, which impairs grasping. This is difficult to correct even by extensor tenotomy (Fig. 26-5) with full relief being rare.

Prognostic Factors

There are several indicators as to the course a patient probably will follow with or without treatment. The age of the individual at the time of first evidence of the disease is one of the most reliable prognostic indicators. Evidence of Dupuytren's disease before age 40 is uncommon and accounts for only about 4% of treated cases, but when encountered it is a basis for serious concern. Recurrence rates will be high, and if the onset has been before age 30, there will be a high probability of significant physical impairment regardless of treatment. Essentially, the older the age when the first signs of the disease appear, the less aggressive the disease will be and the more favorable the prognosis with treatment.

Extensive and diffuse skin involvement, especially to the radial side of the hand, is an unfavorable prognostic factor. The presence of knuckle pads (Garrod's nodes), ectopic fibrous deposits over PIP joints, is a bad prognostic sign, but to a lesser degree

than early age of onset or radial distribution of disease. Knuckle pads do not restrict joint motion, but can be easily traumatized and are tender with enough frequency to warrant their excision.

When loosely fitting MP joints are contracted, secondary stability from intrinsic muscles allows successful release. In contrast, severe flexion contractures of the tightly fitting PIP joints, often accompanied by hyperextension fixation of the DIP joints, only rarely can be fully corrected. Overzealous efforts to do so may result in disastrous joint instability or restricted flexion. Obviously, a patient who has recurrent contractures after experiencing an initially good correction has a strong diathesis for the disease and correspondingly a poorer prognosis.

Clearly, diabetes has an untoward effect on an individual's response to wounding and the reparative process. Diabetics have a tendency to experience protracted postoperative inflammation, soreness, and joint stiffening. Control of these with systemic steroids cannot be proffered.

DUPUYTREN'S DISEASE IN FEMALES

In younger age groups the disease is encountered much less often among females than males, but this ratio shifts steadily toward equality in the elderly. The most striking difference between males and females with Dupuytren's disease is that women almost invariably exhibit a far greater and more protracted inflammatory reaction to surgical procedures. Often this is so dramatic that it appears to be a different disorder. Protracted swelling, soreness, red-purple discoloration, and joint stiffness characterize the postoperative clinical course for most women. Because substantial vasomotor instability is characteristic, the label *reflex sympathetic dystrophy* (RSD) often is assigned, but these patients do not fully meet the criteria to qualify for that disorder (see Chapter 23). *Flare reaction* is the term more appropriately applied. Treatment includes administration of systemic steroids, protective splitting, and encouragement of active exercising. Passive manipulations, except for gentle extension stretching, should be avoided. Unlike RSD, improvement will eventually follow, although it may require several months. It is most important that female patients be warned of this probable course, as it occurs often with them.

I recommend treatment of any PIP joint contracture that becomes fixed in 25 or more degrees of flexion, especially for the small finger. As with males DIP joints should be corrected if possible. (see Fig. 26-5).

The Four Basic Types of Surgical Treatment

1. *Fasciotomy*, the simple division of fascial bands, was advocated by Baron Dupuytren. Its chief

use is for an elderly patient for whom limited improvement is appropriate or occasionally to release a band to improve hygiene and skin condition prior to definitive fasciectomy. A pretendinous band can be safely divided at the distal palmar crease. At this level, the neurovascular bundles always lie deep to the uninvolved transverse component of the palmar fascia.

2. *Radical fasciectomy*, which has been abandoned, is mentioned only for completeness and historical interest. The misguided idea was that the more fascia removed, the less probability of recurrence, but this makes no sense today, with the disease recognized as being characterized by newly formed tissues rather than modified fascia. Radical fasciectomies resulted in such extensive damage to hands that recovery was painfully slow and very often incomplete.
3. *Limited fasciectomy* is the basic treatment of Dupuytren's disease today. Excision is restricted to tissues grossly involved by the disease. Skin lengthening, joint releases, and skin replacement are performed as needed. Minimizing the inflammatory reaction is of such great importance that the highest priority goes to primary wound healing. The greatest controllable factor in achieving primary wound healing is preservation of adequate vascularity in the tissues, especially of skin flaps. This is difficult, as wide areas of skin are so often intimately involved with the disease. Unavoidable undermining results in very thin and thus poorly vascularized flaps. Palmar skin is vascularized by vertically oriented small vessels. Saving one or more of these will ensure the viability of the palmar flaps (see Fig. 26-6). Flaps with inadequate circulation require excision and replacement with grafts as an essential part of the primary treatment. If the resulting wound surfaces are not suitable for immediate skin grafting, a local or rarely a distant flap may be required to achieve the critical primary wound closure and healing. Generally, because the disease so often involves the middle, ring, and small fingers, fasciectomy of the palmar fascia to all three (the "ulnar triangle" of palmar fascia) should be done, even if only one of these fingers is grossly involved at the time.
4. *Fasciectomy with excision of involved skin and skin grafting* should be considered for four circumstances:
 - A. When there is inadequate skin for wound closure
 - B. To replace flaps of questionable viability
 - C. When treating recurrent disease

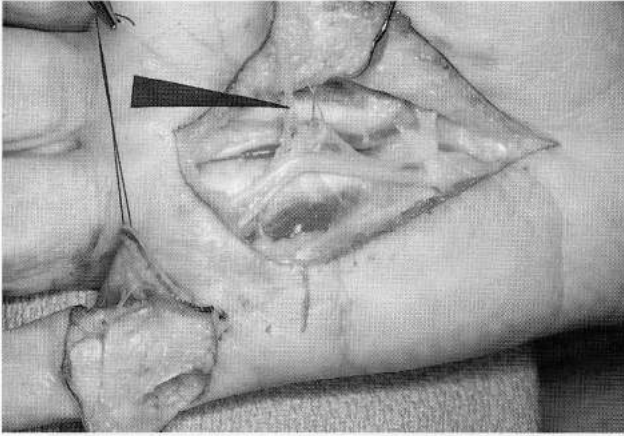


FIGURE 26-6 Elevation of palmar flaps is precarious, but preservation of one or more of the small vertically oriented vessels (pointer) into them will ensure viability.

- D. For selected cases, having a very strong diathesis for the disease, as part of primary treatment

Recommended Treatment of Dupuytren's Disease

There have been sporadic reports of successful chemical treatment of Dupuytren's disease, such as injection of early-stage nodules with steroids or digestive enzymes, but the basic treatment of Dupuytren's disease continues to be surgical, with uncomplicated primary wound healing being overwhelmingly the most important goal. To achieve this, vascularity to all flaps is essential and paramount for the palm whose vascularity is basically vertical rather than longitudinal (Fig. 26-6).

It is a fundamental principle of treatment that the operation be divided into two distinctly separate

parts. The first is palmar fasciectomy, and the second is the more difficult excision of disease from the digits and interphalangeal joint releases. Initial palmar fasciectomy results in improvement in digital extension. Not only is exposure for the fingers improved, but often a less extensive operation on the fingers is needed. With extremely severe contractures, I treat the two areas in separate operations (Fig. 26-7) to limit the surgical trauma at each session. The palmar portion should always be done first, after which finger contractures will be less severe and exposure improved. The palmar fasciectomy should be the complete "ulnar triangle," fascia to the middle, ring, and small fingers, even if only one appears to be disease involved at the time.

Controlling Recurrence of Dupuytren's Disease

The recurrence rate after fasciectomy for Dupuytren's disease varies greatly among patients according to their individual diathesis, but it averages about 4% overall. It diminishes in relation to the increasing age of the patient at the time of onset of the disease. Because Dupuytren's disease starts in the subdermal tissues with fascial involvement being secondary, the excision of skin with diseased fascia to remove the dermis has proven to be effective in preventing disease recurrences (Fig. 26-8) in at least 90% of cases. The exact success rate is not certain because one cannot distinguish between recurrence and extension of disease from fascia not previously excised. Surprisingly, skin from the anterior wrist, close to the hand and matching its tissues well, is as effective in preventing recurrent disease as grafts from more distant locations (Fig. 26-9).

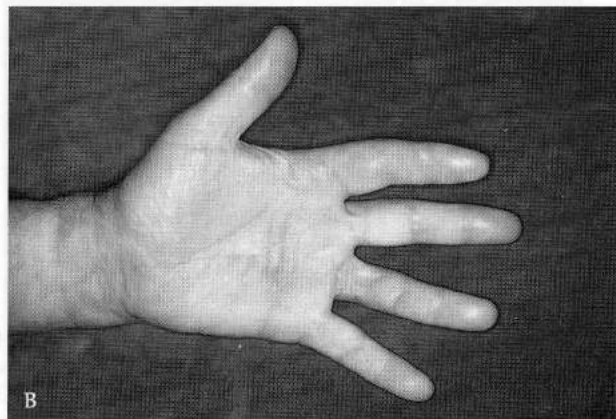
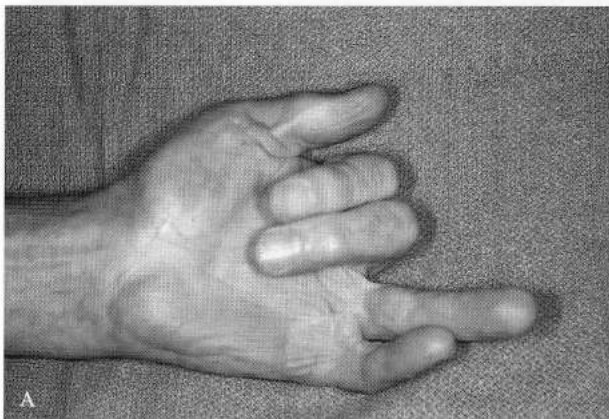


FIGURE 26-7 (A). Example of diffuse, severe recurrent disease treated in two separate operations. The first operation was in the palm, and after good healing and remobilization, the second operation was done on the fingers. Surgery is controlled injury, and too much at once may overwhelm the patient's recuperative powers. (B). Five-year follow-up shows exceptional results, with the skin grafts being difficult to detect.

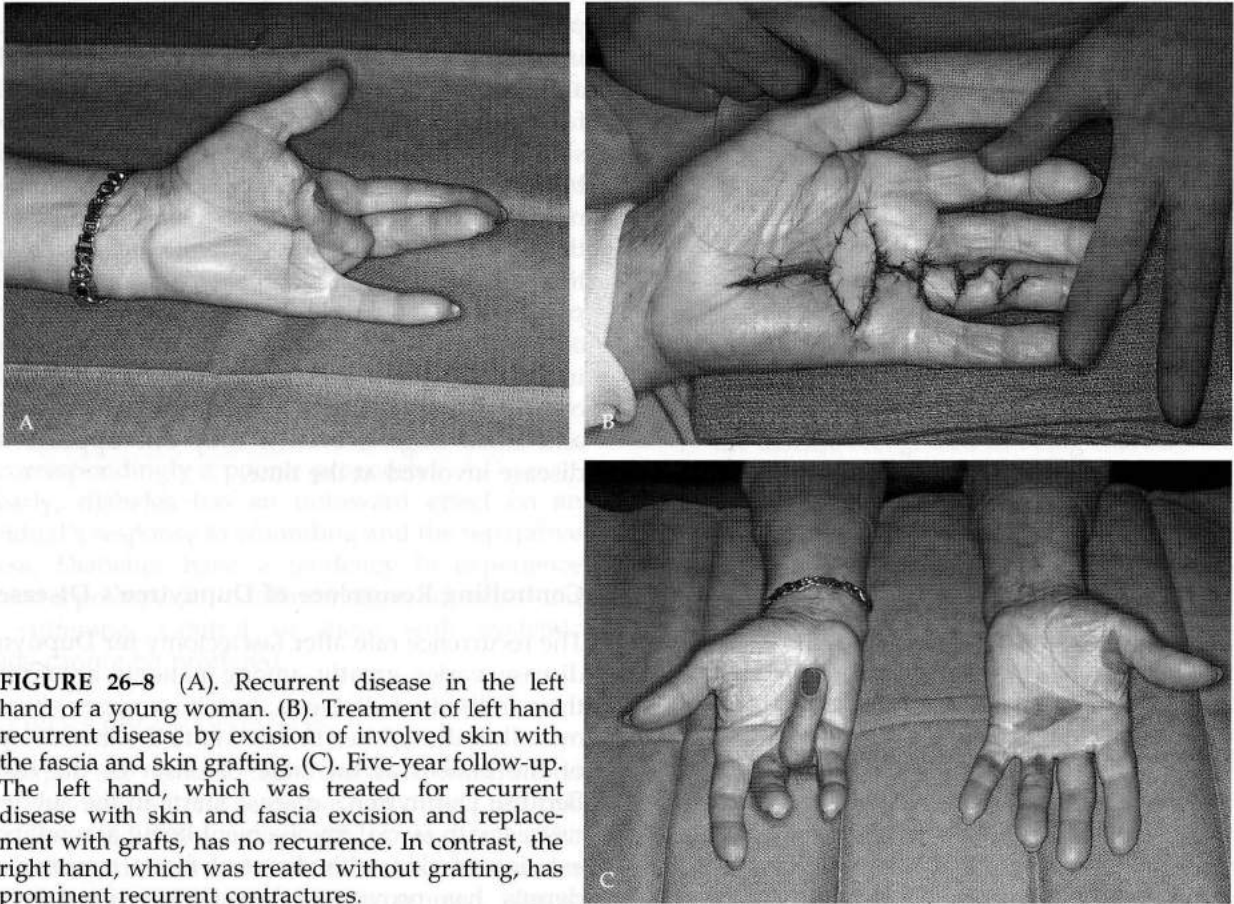


FIGURE 26-8 (A). Recurrent disease in the left hand of a young woman. (B). Treatment of left hand recurrent disease by excision of involved skin with the fascia and skin grafting. (C). Five-year follow-up. The left hand, which was treated for recurrent disease with skin and fascia excision and replacement with grafts, has no recurrence. In contrast, the right hand, which was treated without grafting, has prominent recurrent contractures.

Primary Skin Excision and Grafting

Excision of skin with the diseased tissue bands is mostly reserved for recurrent disease, but the approach may occasionally be used as part of primary surgery in cases having a high diathesis for the disease and especially for those with

involvement of the little finger. Secondary correction of the little finger is always difficult and hazardous with a substantially increased risk of nerve damage or other complications, compared to primary procedures.

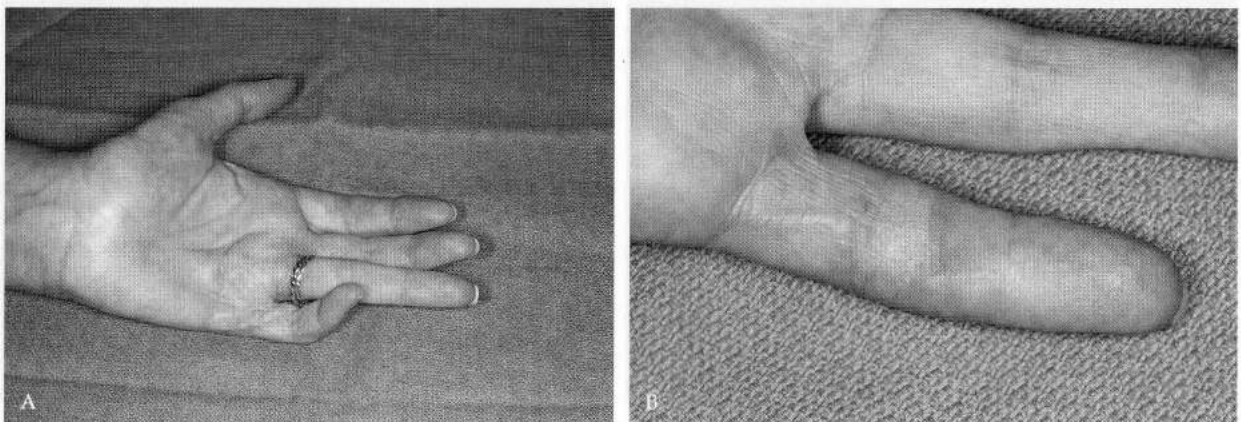


FIGURE 26-9 (A). Recurrent disease with fixed 60 degree proximal interphalangeal (PIP) contracture. (B). Treatment by excision of involved skin, with the fascia and skin grafting from the anterior wrist, which provides tissue of perfect match. It is as effective as skin from more distant sites in preventing a recurrence of Dupuytren's disease.

Skin Grafting and Skin Donor Sites

Repair of skin defects is in most cases with either full-thickness or very thick split-thickness skin grafts, as it is the dermis to which the strength and good characteristics of skin must be attributed. The thicker the graft taken, the greater the pain and donor site complication rate, including infections and scar hypertrophy.

When large skin grafts are required, the donor site of choice usually is the hairless area along the outer inguinal fold between the leg and the body. An ellipse of skin and subcutaneous fat up to 8 × 15 cm can be taken readily. No effort is made to remove the skin without subcutaneous fat. The resulting wound is closed directly in layers to obliterate space. An intradermal pull-out or set of buried sutures is used for skin coaptation. This technique minimizes wound morbidity associated with the taking of large and thick skin grafts. The patient will be able to discard the dressing and shower after 24 hours, with almost no pain.

The skin side of the large ellipse of tissue is then placed on the tape of a Padgett's drum dermatome, and the subcutaneous tissues are split off at the level of the deep dermis (Fig. 26-10). This leaves a smooth and even full-thickness skin graft on the tape, where it can be cut into appropriate sizes and shapes for the various hand defects to be grafted.

An acceptable alternative for large skin grafts is to cut a thick split-thickness graft medially from the buttock just below the waistline where there is little hair or motion. This wound should be grafted with an extremely thin graft from an adjacent area, usually lateral to the deep donor wound. This prevents blood from running on the skin cement applied for cutting the second (thin) graft. The thin graft is too fragile to be taken from the dermatome tape, so the tape with graft on it is trimmed to fit and sutured over the deep graft's donor wound. This results in minimal wound pain and complications at either site. Both wounds heal in only a few days (Fig. 26-11).

When only small skin grafts are required, the donor site of choice is the anterior wrist. This is the only skin that after transplantation matches that of the hand almost perfectly (see Fig. 26-9). An elliptically shaped graft of full-thickness skin, based on the most prominent transverse skin folds, is cut by free-hand technique. From adults, especially older ones, an ellipse of skin 8.0 cm long and 2.0 cm wide can be taken readily with direct closure of the wound. An intradermal 4-0 monofilament nylon pull-out suture is used and left in place for a minimum of 3 weeks. The ends of the pull-out suture are not tied to the flesh, as its tension invariably results in cellulitis and stitch abscesses after only a few days. The ends of the pull-out suture are tied around the tip of a cotton

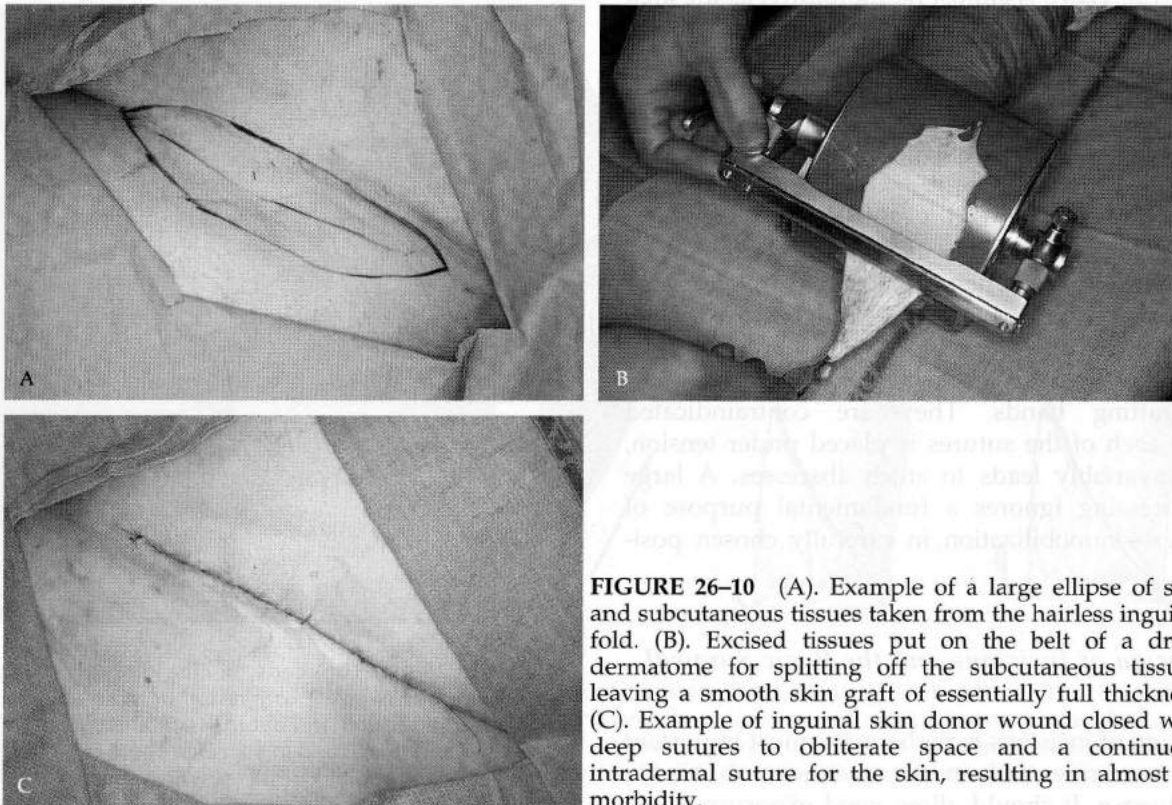


FIGURE 26-10 (A). Example of a large ellipse of skin and subcutaneous tissues taken from the hairless inguinal fold. (B). Excised tissues put on the belt of a drum dermatome for splitting off the subcutaneous tissues, leaving a smooth skin graft of essentially full thickness. (C). Example of inguinal skin donor wound closed with deep sutures to obliterate space and a continuous intradermal suture for the skin, resulting in almost no morbidity.

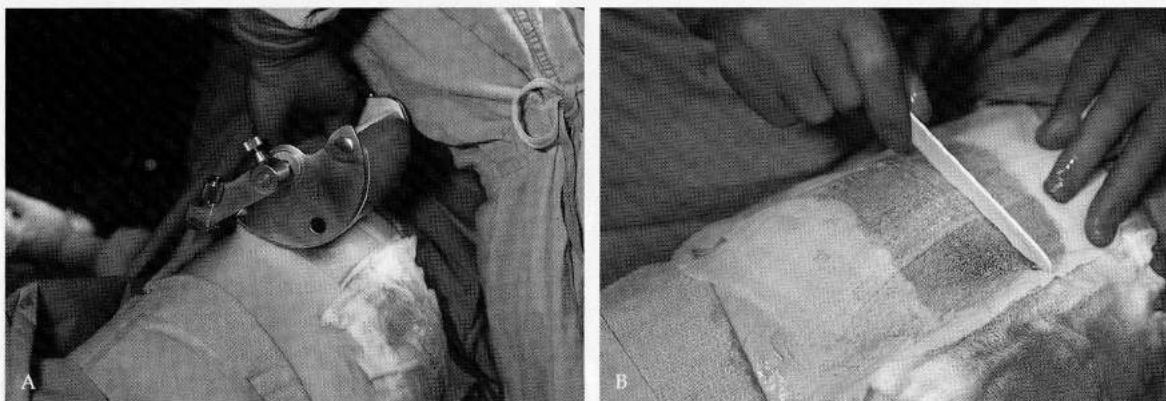


FIGURE 26-11 (A). The buttock just below the waistline makes a good donor site, but thick skin graft wounds have unacceptable morbidity. This can be minimized if the wound is grafted with an extremely thin skin graft from the adjacent area. (B). The thick medial graft has been cut first so that blood would not run on the skin cement put in the area from which the thin graft is to be taken. (C). The very thin graft donor site is covered with a single layer of fine-mesh gauze that dries quickly. The thin graft is too fragile to remove the dermatome tape, so the tape with it is sutured over the thick graft's wound after removing the tape's backing.

applicator stick, whose even distribution of pressure against the skin obviates stitch abscesses and allows the suture to be left in place for a long period of time (Fig. 26-12). There is almost no morbidity, as the area requires no dressing, and patients can shower normally. The tissue match to the hand is almost perfect (see Fig. 26-9).

The dressing is the key to successful transplantation of skin grafts. There must be absolute immobilization, as any motion will cause a shearing between the graft and the host bed. Capillaries growing from the recipient bed to revascularize the grafts will be torn to cause punctate hemorrhages, separation of the graft from the recipient wound, and necrosis of the grafts.

Bolus or "tie-over" dressings are not needed for skin grafting hands. They are contraindicated because each of the sutures is placed under tension, which invariably leads to stitch abscesses. A large bulky dressing ignores a fundamental purpose of dressings—immobilization in carefully chosen positions.

The Design of Incisions and the Basic Surgical Approach

The design of incisions is perhaps the most important technical consideration in the treatment of Dupuytren's disease. It should allow good exposure to the

diseased tissues in order to avoid the hazardous tunneling approach. Undermining should be mini-

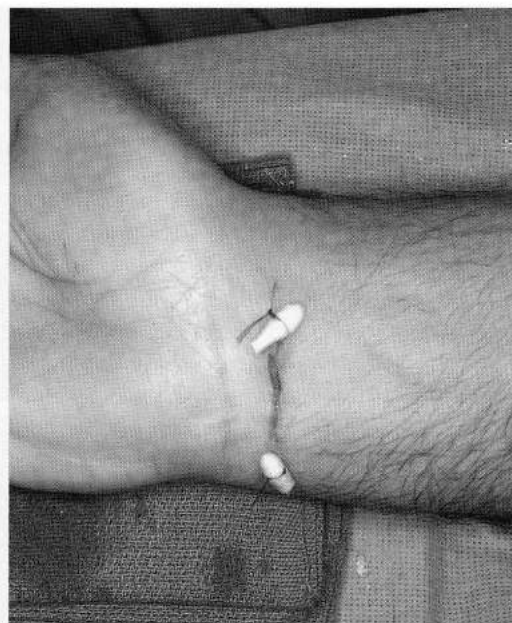

FIGURE 26-12 The ends of the intradermal pull-out suture are tied over the cotton tips from an applicator stick to distribute tension and avoid stitch abscesses. The suture can remain in place for 3 to 4 weeks. There is no place on the upper limbs for bolus dressings with which every suture is under tension.

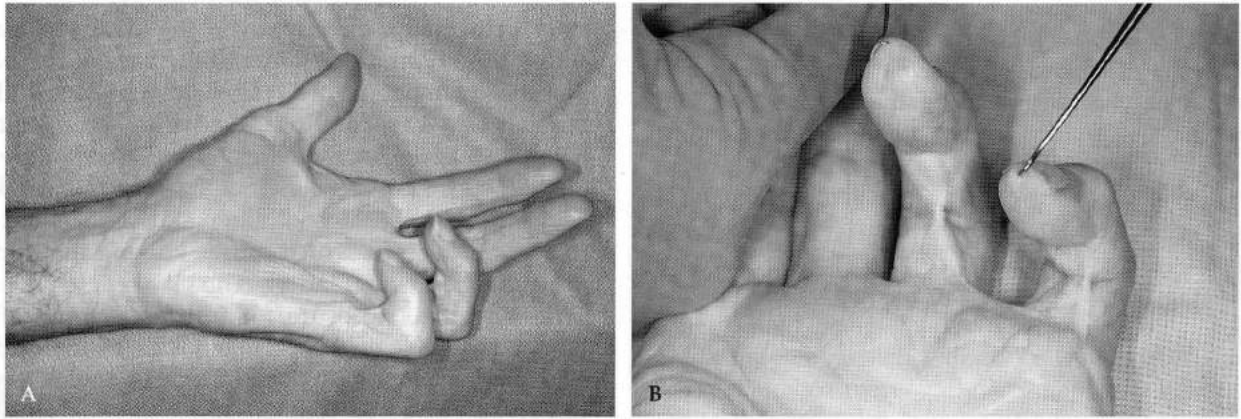


FIGURE 26-13 (A). Severe recurrent contractures attributed to Dupuytren's disease. (B). Closer examination shows that the recurrent contractures are caused by ill-advised longitudinal scar contractures. There was no recurrent disease.

mized to maintain maximum vascularity of the skin. The design of incisions in an unoperated hand is rather straightforward, permitting the surgeon to choose a plan for adequate exposure with minimal skin undermining. When confronted with scars of previous operations, the flexibility in designing incisions often is restricted.

Incisions must conform to the rules that govern placement of elective incisions to avoid troublesome scar contractures (Fig. 26-13). The basic rule is that they be placed along neutral lines, those that undergo no change in length with any movement of which the parts are capable (Fig. 26-14A). All wounds heal with scars, and all scars contract. Though initially appear-

ing to be good lines, short oblique incisions on the palmar surface of fingers will with contraction pull down into an almost straight longitudinal scar, which in turn pulls the PIP joint into flexion (Fig. 26-14B). Thus, it is important that oblique incisions on fingers cross the whole digit from one side to the other, not to the midpoint and then back to the same side (Fig. 26-14C,D).

Several examples will be given to illustrate these principles. When there is no significant skin shortage and flexion contractures primarily involve a single finger, the incision design popularized by Wakefield generally is satisfactory; that is, a straight line down the volar surface of the contracted finger from its DIP

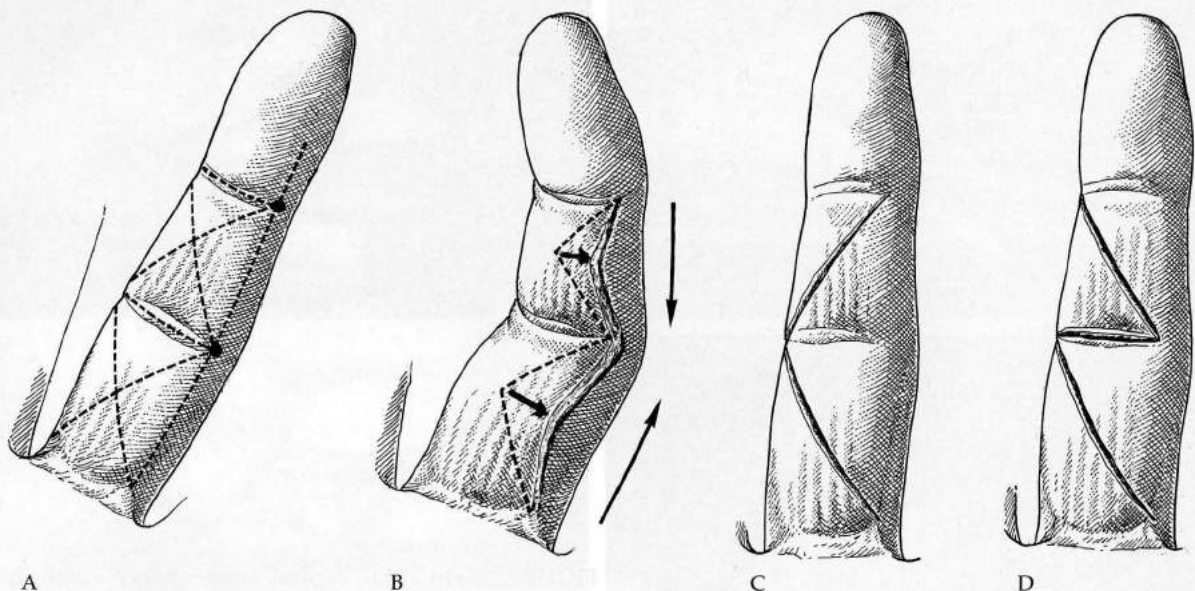


FIGURE 26-14 (A). Connecting lines from the midaxial point of joints are "neutral" because they have little change in length with movements of the parts. Therefore, contracture of a scar along these lines causes minimal disturbance of mobility. (B). With highly mobile fingers, short oblique palmar scars will contract enough to result in an almost straight longitudinal contracture. (C-D). Incisions on finger anterior surfaces must extend fully across the phalanx or parallel to skin creases but not change direction at the midpoint back to the site of origin.

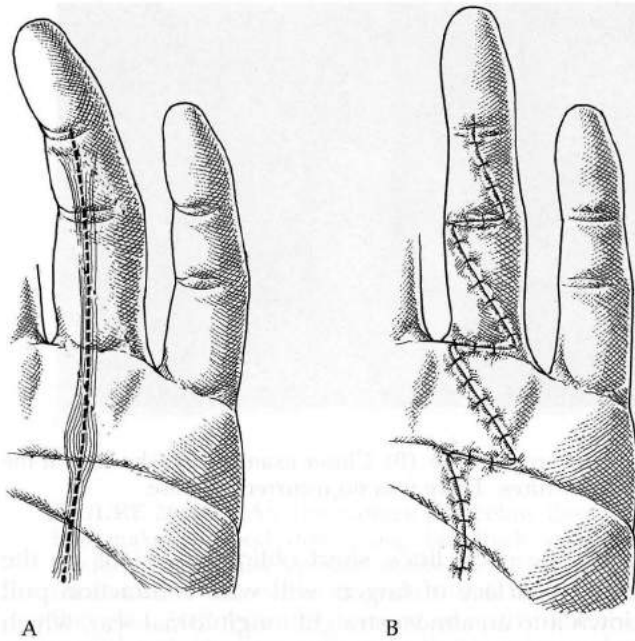


FIGURE 26-15 (A). A popular approach for single finger disease is that advocated by Wakefield. The greatest virtue of the simple longitudinal straight incision is good exposure and safety. (B). The substantial disadvantage of the Wakefield approach is that Z-plasties are required at each skin crease crossed.

joint proximally directly over the diseased bands across the PIP and MP joints to the base of the palm. The disadvantage of the Wakefield-type longitudinal incision is that multiple Z-plasties are required wherever the incision crosses transverse skin creases (Fig. 26-15). As I will elaborate later, my objection to Z-plasties is that the usually thin skin flaps have to be rotated 90 degrees, which causes kinking that further impairs their vascularity. The Wakefield incision gives adequate exposure for full fasciectomy of the "ulnar triangle" of the palmar fascia to the middle, ring, and small fingers regardless of which one is principally involved (Fig. 26-16).

For most cases, and especially when contractures are associated with moderate skin shortage, I prefer a series of short, broad-based opposing V flaps, converted into Y-V configurations. This gives excellent exposure and skin lengthening while preserving maximal circulation in the flaps, which are broad and short with no kinking of their pedicles as occurs with Z-plasty wound closures (Fig. 26-17). As previously emphasized, the flap margins must conform to the rules of elective incisions. These flaps can be advanced in a Y-V manner for longitudinal lengthening of skin, which carries their oblique lines almost completely across the whole phalanx (Fig. 26-18).

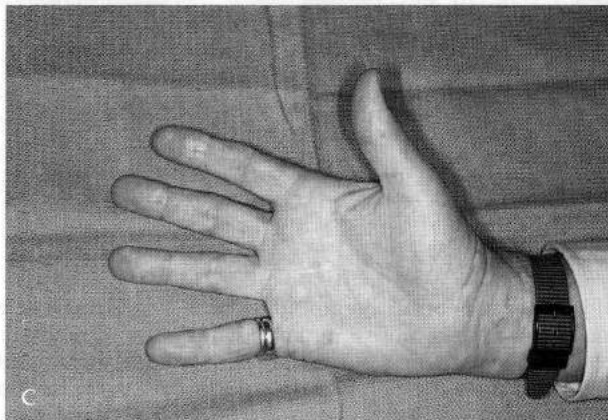
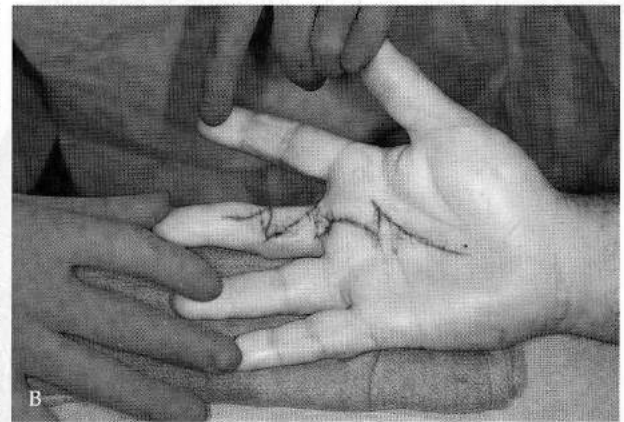
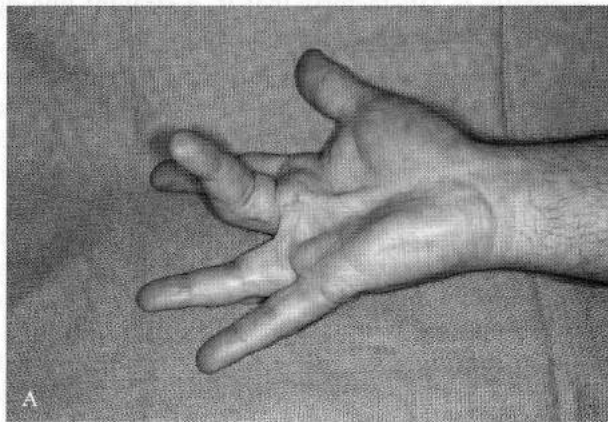


FIGURE 26-16 (A). Typical single finger contracture treated with a Wakefield approach, which provides adequate exposure for fasciectomy of the "ulnar triangle"; palmar fascia to the middle, ring, and small fingers is advocated even if only one finger appears to be involved. (B). Meticulous wound closure. (C). Twelve-year follow-up.

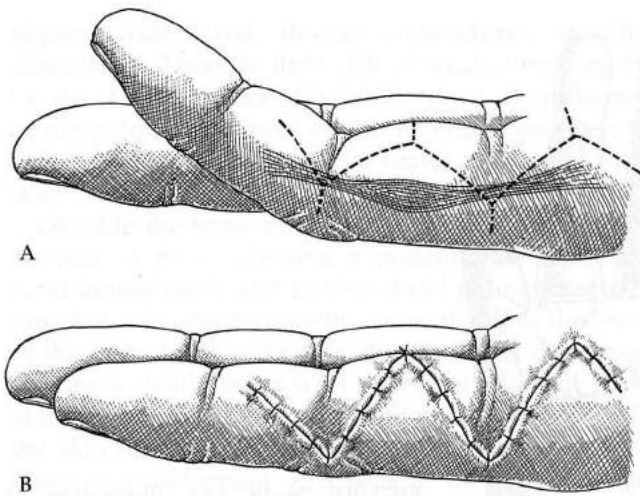


FIGURE 26-17 (A-B). I frequently employ the Y-V approach to fingers. The flaps are short and broad-based to give excellent exposure, but there is no kinking to diminish their vascularity.

Skoog (1948) emphasized that when there is extensive disease and multiple finger involvement, incisions are best made directly over the diseased

bands to minimize undermining and thus maximize flap vascularity. The Skoog approach is a transverse incision across the palm at the "safe zone" over the transverse component of the palmar fascia, which corresponds to the distal palmar crease on the surface. From the transverse palmar incision, longitudinal incisions perpendicular to it are made into each of the involved fingers distally, and a single incision is made proximally to the base of the palm (Fig. 26-19). These longitudinal incisions have to be corrected with Z-plasties, to which objections have been stated. There can be many variations, such as combining the Z-plasties with skin grafting when appropriate (Fig. 26-21). The great virtue of this technique is minimal flaps undermining for very extensive disease and thus maximum preservation of critical flap vascularity (Fig. 26-20).

Dissecting Technique

Dissection is principally by sharp knife technique. This is less traumatic than blunt scissors dissection. It always should be begun in the palm rather than the digits. As dissection progresses, the interference from

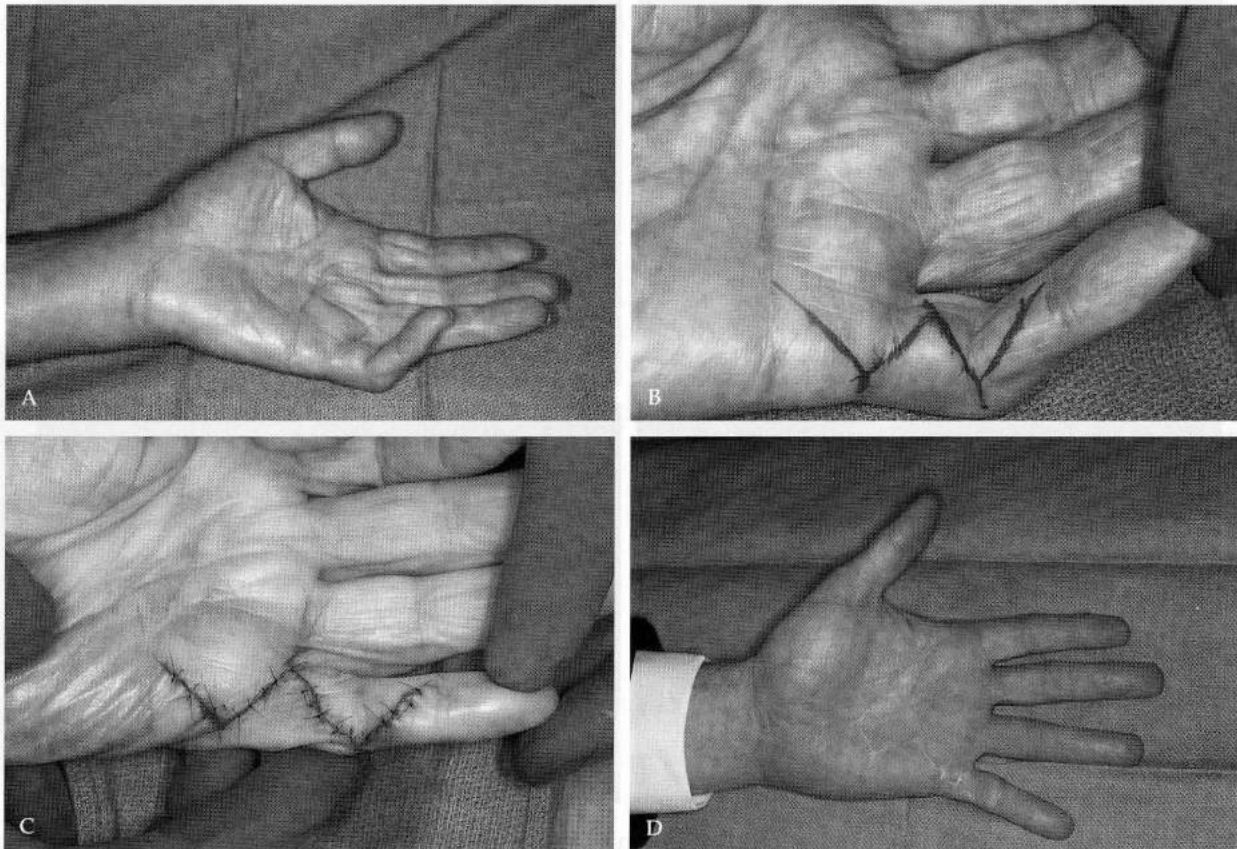


FIGURE 26-18 (A). Small finger 70 degree PIP contracture needing substantial skin lengthening. (B). Planned Y-V approach. (C). The lines of closure are all parallel to good incisional lines, obviating problems of scar contracture, and skin lengthening is excellent. (D). Sixteen-year follow-up of this difficult case.

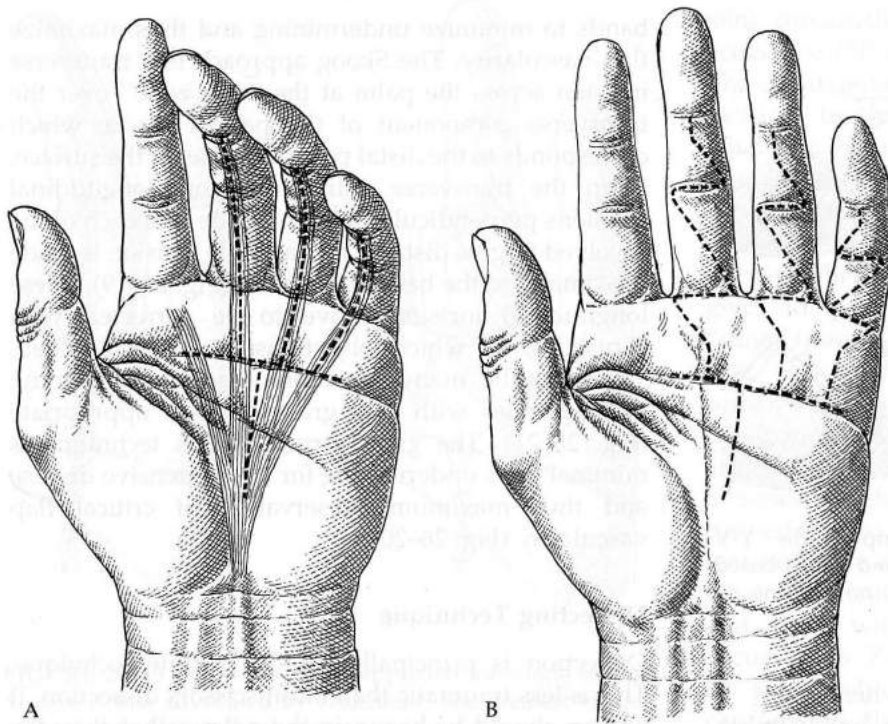


FIGURE 26-19 (A). Illustration of the basic Skoog-type direct approach for diffuse disease. Its greatest virtue is the direct approach to diseased fascia, with minimal skin undermining and thus devascularization. (B). All straight-line incisions must be corrected by Z-plasties, often combined with transversely oriented skin grafts.

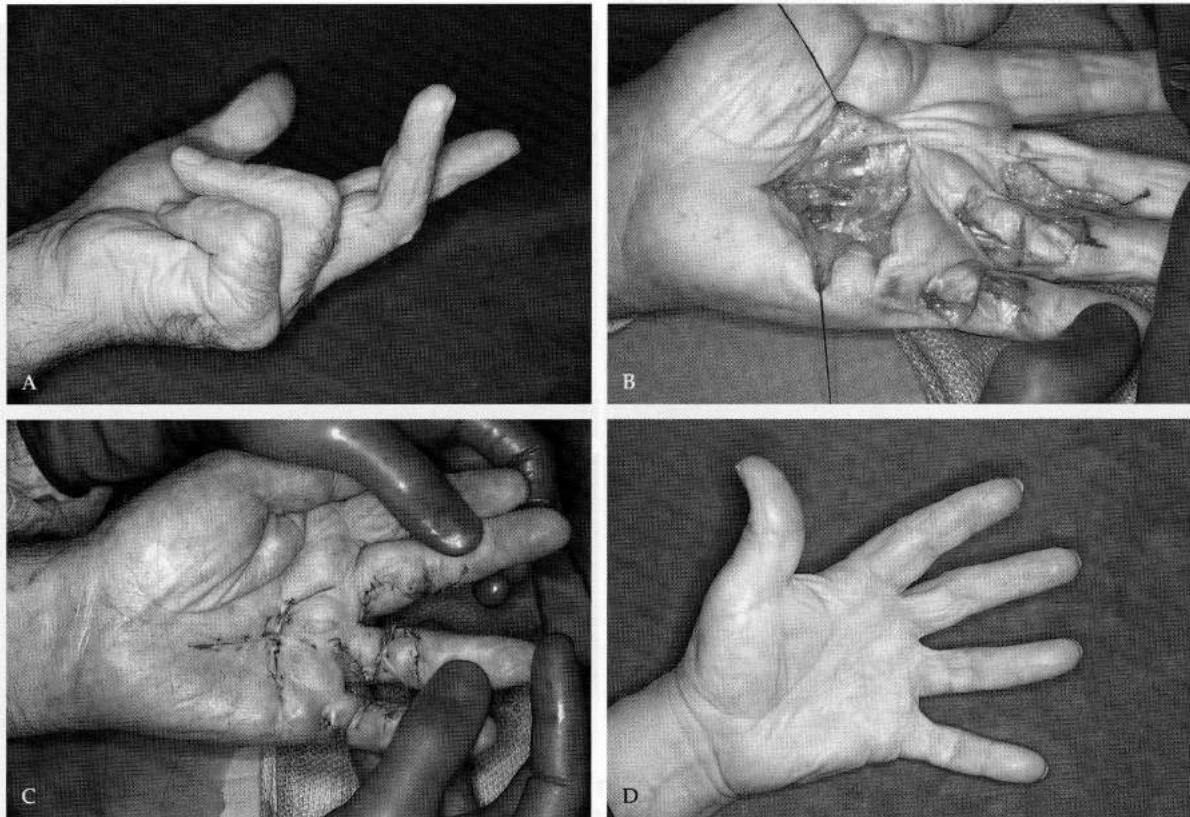


FIGURE 26-20 (A). Example of diffuse, advanced Dupuytren's disease for which primary wound healing and early active motion must be given top treatment priority, or the hand will be permanently crippled. (B). Dissection completed through multiple small incisions with minimal skin undermining. It is better to leave some contractures than to be so radical in dissections as to compromise primary wound healing. (C). Wound closure, incorporating skin graft replacement of the most disease-infiltrated skin. (D). Eight-year follow-up.

fingers with fixed flexion contractures steadily diminishes. There is little risk of inadvertent injury to one of the common digital nerves in the proximal or midpalm. The nerves do not emerge from deep to cross over the diseased fascial bands proximal to the transverse component of the palmar fascia.

Distal to the transverse palmar fascia, anything can happen. A nerve crossing a pretendinous diseased band immediately distal to the distal palmar crease is rare, but it is very frequently encountered at the level of the interdigital webs (Fig. 26-21). Thus, dissection in fingers should begin with the elevation of the flaps at the base of the digit in a plane immediately beneath the skin until the digital nerve locations are known. Observing movement of tissues in the finger as the nerve identified in the palm is gently pulled with forceps can be very helpful in determining the digital nerve's location in the fingers.

The preservation of the blood supply must be a paramount preoccupation while elevating flaps. Preserving even one or two of the small vertical vessels in the palm by dissecting diseased tissues from around them can significantly increase flap viability (see Fig. 26-6). Also, the surgeon needs to be mindful while planning that scars may be shifted by their contraction with healing to become less favorably placed than they appeared when designed and cut (see Fig. 26-14).

Dupuytren's Contractures of Thumbs

Dupuytren's disease involving a thumb will be in one of two locations, or in both. It may be along the radial side of the thumb from the neck of the proximal phalanx back into the thenar eminence. Incisions for

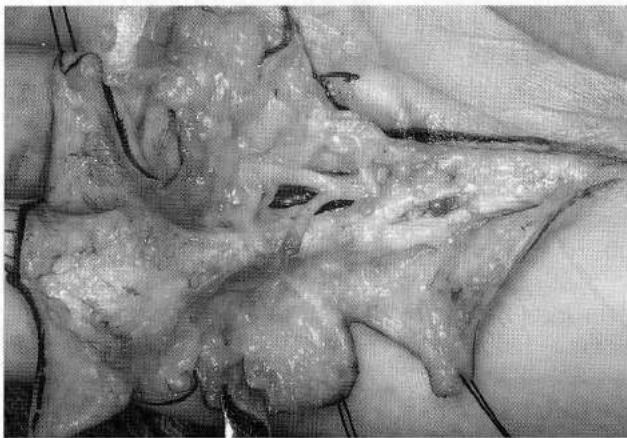


FIGURE 26-21 At the base of the proximal phalanges any anatomic arrangement can be encountered. Illustrated is a digital nerve crossing over and spiraling around a diseased pretendinous fascial band. Dissection in this area should be just deep to the skin until there has been positive identification of the neurovascular bundles.

removal of this include opposing short V flaps or a longitudinal incision over the bands, corrected subsequently with a Z-plasty at the MP joint level. Occasionally a transverse ellipse of skin graft is required at the MP joint level.

The second pattern of Dupuytren's disease of the thumb is that of contracted dense bands in the web between the thumb and the index finger. These tissues are a continuation of the transverse palmar fascia, but unlike those in the palm, those in the thumb-finger web are submitted to longitudinal stressing. When correction is needed, the best approach to this area is through one or two Z-plasties, often of rather large size.

Technical Considerations for Z-plasties

For many situations, Z-plasties offer the best solution, but because maintaining adequate vascularization of flaps is one of the greatest problems in treating Dupuytren's disease, we must constantly be mindful that flaps of Z-plasties are kinked as they are rotated, and thus circulation in the flaps is reduced.

In designing a Z-plasty for correction of a longitudinal line crossing either an MP or PIP joint skin crease, I first study which elevated skin is thinnest and thus least well vascularized. The proximally based flap should be cut from the thinnest tissues, and the distally based flap of the Z-plasty should be cut from the thicker and better vascularized skin. When a Z-plasty is required at both the MP and PIP joints of a finger, selection based on tissue vascularity may be initially planned at either the MP or PIP joint level. However, once a Z-plasty is planned at one, there is no choice for the direction of the flaps at the other joint. The distally based flap of the Z at each of the joints must be from the same side of the longitudinal finger incision. This results in the eventual scar being continuous and oblique across the proximal phalanx from one side to the other side of the finger. If the distally based flaps of the Z-plasties at the MP and PIP joints are from opposite sides of the finger, the scar on the proximal phalanx will pass from one joint to the middle of the phalanx, then back to the second joint on the same side of the finger. Because all scars contract, a scar that fails to be continuous and oblique completely across the finger will with contraction inevitably change into almost a straight longitudinal scar. As contraction continues, it can cause a recurrence of joint flexion contracture (see Fig. 26-14). Design has to be modified from time to time to accommodate existing scars, but the rules governing acceptable elective incisions must still be thoughtfully applied in formulating any plan.

There are no options in the design of Z-plasties in the palm to correct the line of a longitudinal incision crossing the distal palmar skin crease. The flap cut

from the tissues on the lateral side of the longitudinal incision must be based distally and that from the medial side based proximally. This places the incision for one flap parallel to the crease at the base of the thenar eminence and that of the other or medial flap parallel to the distal palmar crease. These are favorable lines with respect to skin tension (Fig. 26-22).

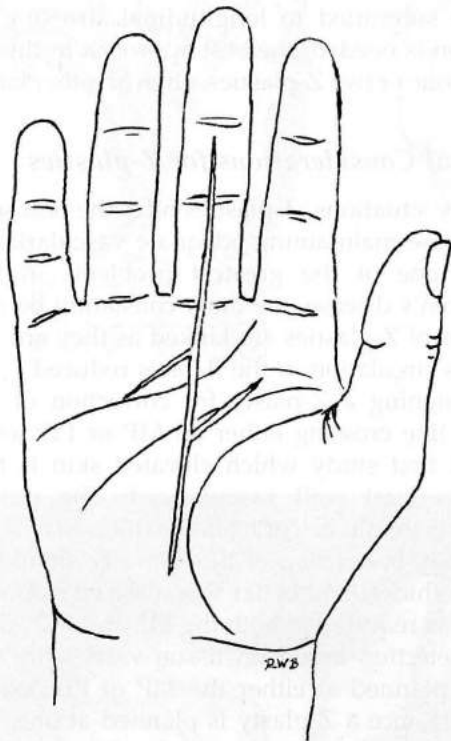


FIGURE 26-22 (A). There are no options in the placement or direction of Z-plasty correction of longitudinal incision across palmar skin creases. The incision for the lateral flap must be parallel to the crease at the base of the thenar eminence. If placed in the other direction, it would result in a web of scar across the palm.

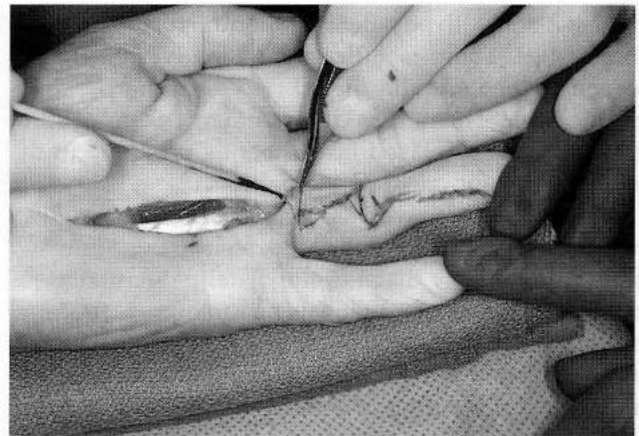


FIGURE 26-24 To avoid a surprising misfit in a Z-plasty, only one flap should be cut initially. It is then rotated across the tissues from which the second flap is to be cut, and the level that it covers should be marked for incision there. With this technique, the flaps always fit comfortably without tension.

In doing a Z-plasty, the surgeon should cut and undermine only the portion of the flap necessary for its rotation. This will be chiefly at the corner opposite its direction of rotation, which is the limiting point as with a rotation flap. Usually only half or less of the flap has to be undermined, which preserves much of its vascularity (Fig. 26-23).

The surgeon should be careful to cut only one flap of a Z-plasty at a time. After the first flap has been cut and undermined to the extent necessary, it should be rotated over the opposite tissues from which the second flap will be cut. The area that it covers easily without tension should be marked (Fig. 26-24). The second flap of the Z-plasty is then cut along that line; the resulting defect from its rotation will be satisfactorily covered by the first flap. Cutting both flaps at once can lead to some very awkward problems of wound closure.

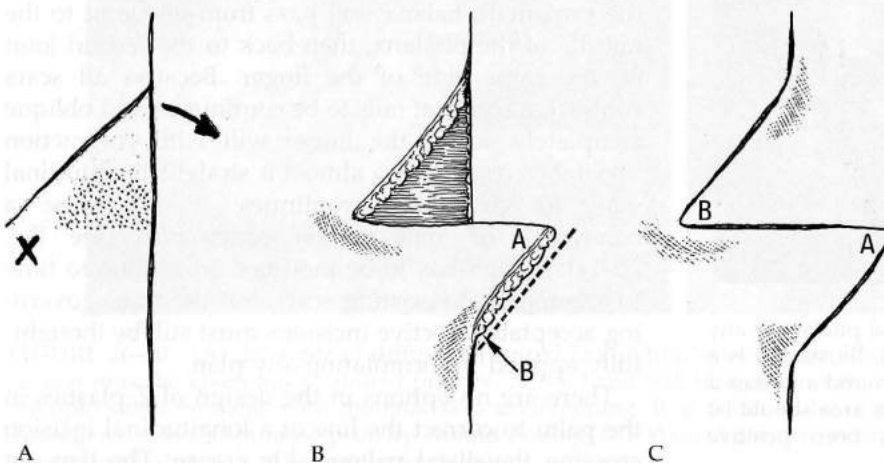


FIGURE 26-23 (A). Z-plasty flaps have to be rotated. X marks the restricting corner, which must be thoroughly undermined to allow rotation. The stippled area will be redundant with rotation, so it does not need to be undermined, but it should be saved intact for maximum vascularity of the flap. Also note that only one flap is initially elevated and rotated to see where it covers easily. This is marked and then cut to create the second flap. (B). Flap elevated only as necessary for rotation leaves in fact about 50% of their subcutaneous derived blood supply. (C). Z-plasty completed with 90° correction of the longitudinal line.

The Release of Contracted Joints

Metacarpophalangeal Joints

A severely contracted MP joint with Dupuytren's disease generally can be released to gain its full extension. This is in contrast to MP joint contractures that have developed subsequent to trauma. In most cases, the MP joint will be found to be held in flexion by well-defined pretendinous bands of diseased fascia, and their resection results in a good correction of deformity. Because stability of MP joints is essentially from the elastic interosseous muscles passing along each side, MP joint is not the problem of PIP joints which have no release stabilizing system secondary to their collateral ligaments.

Interphalangeal Joints

Unlike the loosely fitting MP joints, the complete release of PIP joints rigidly fixed in flexion is very difficult or may even be impossible. PIP joints are tight fitting and have no secondary lateral support system, which the intrinsic muscles provide for the MP joints. Volar plate attachments and the collateral ligaments stabilize the IP joints. Thus, if these structures are too radically resected to regain joint extension, a disastrous instability can result. It is far better to accept some persistent PIP joint contracture than to create by overly zealous ligament resection joint instability or restricted flexion due to scarring of the volar plate.

Release of PIP joint flexion contractures is approached in an orderly step-wise manner. First is resection off the joint capsule of all diseased fascial bands traversing the joint. At least one of the small vincular arteries that pass from the digit artery under the check-reining ligament at the proximal attachment of the volar plate should be preserved if possible (see Color Plate 11). Rendering the flexor tendons ischemic by interruption of the vincular arteries will favor tendon adhesions or even tendon rupture.

If more extension is desired, gentle extension stretching is applied to the joint. In most cases after 10 minutes or so of stretching, satisfactory joint extension will be gained without rupture of the important volar plate.

If greater extension is needed for a PIP joint after the above steps, the surgeon may be tempted to resect the proximal attachments of the volar plate, the check-reining ligaments at the neck of the proximal phalanx. However, this should be avoided or at least done in a most conservative manner to minimize creation of a restricting scar of the volar plate. The check-reining ligaments at the proximal end of the volar plate must remain pliable to let the volar plate flex and shift proximally if the PIP joint is to have full flexion.

Surgical or other damage to the volar plate or its ligaments has a high probability of restricting subsequent joint flexion as well as extension.

Ideally, correction of PIP joint flexion contractures should be to about 10 to 15 degrees short of neutral. If the joint is brought to full extension, not only will flexion probably be restricted, but there is danger of the PIP joint's hyperextending backwards into a disastrous recurvatum deformity in accordance with the zigzag phenomenon elaborated by Landsmeer.

PIP joints relieved of chronic extreme flexion always have an extensor tendon lag or redundancy of the extensor tendon system. Placing a Kirschner pin to hold the released joint in extension is appealing, but transarticular pinning gives inferior results compared with extension by splinting, with eventual rebalancing by intrinsic muscle exercising. Splinting starts with the initial surgical dressing, and eventually vigorous intrinsic muscle exercises. Postoperative management is most important. If there had been a severe flexion contracture and therefore substantial extensor lag, extension splinting is continuous for 4 to 6 weeks, except for specific flexion exercise sessions, and afterwards continued at night until all tendency for recurrence of flexion contracture has passed.

Finally, skin shortage or contracture of the flexor tendon sheath, especially when scarred in cases of recurrent disease, may require release for sufficient correction of contractures. Skin shortages are usually treated by appropriately placed and shaped full-thickness skin grafts. However, when a section of tendon sheath has to be resected, the coverage problem may be more difficult and require a flap for wound closure. When feasible, local flaps are rotated over the denuded tendons, with skin grafts being applied to other areas that have suitably vascularized beds. The surgeon must be prepared in some difficult situations to use a cross-finger or other flap to achieve satisfactory wound closure with healthy, mobile tissues (Fig. 26-25).

Release of Distal Interphalangeal Joints

Most frequently digital DIP joints are a problem because of limited flexion from a hyperextended position rather than involvement in a primary flexion contracture (see Fig. 26-5). Satisfactory release of a DIP joint from a hyperextended position is often met with frustration and less than desired correction. A dorsal incision over the middle phalanx is used to expose the extensor system, and fascial bands from the volar side of the finger entering it should be resected from each side. However, this often results in a disappointing degree of relief. A tenotomy of the extensor system, distal to the central slip's attach-

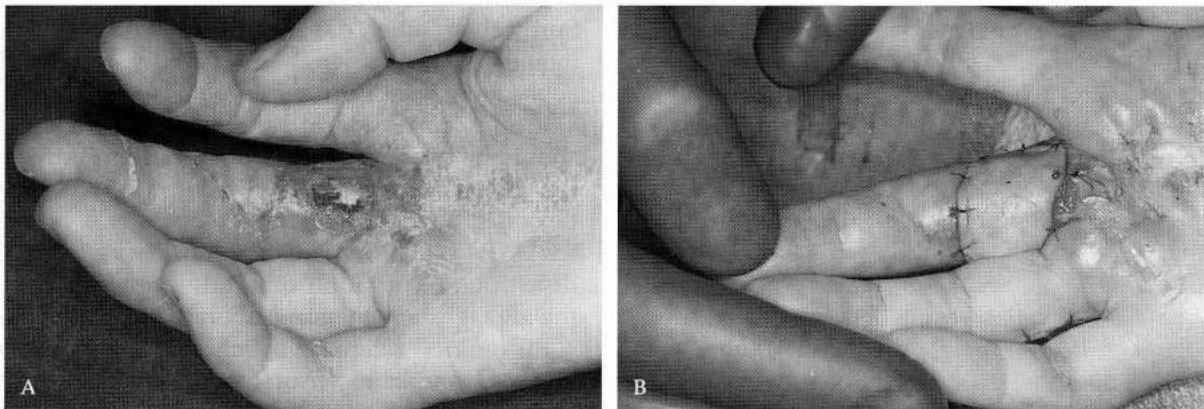


FIGURE 26-25 (A). Disease-infiltrated hand with flap necrosis exposing denuded flexor tendons unsuitable for skin grafting; prompt flap coverage is required. With advanced and especially recurrent disease, a flap is often necessary. (B). For the majority of cases needing a flap, a cross-finger or other local flap can be devised. A classic cross-finger flap is illustrated.

ment, is the next step, but correction very often is still incomplete.

Wound Closures

Wounds are closed by accurately coapting their margins with interrupted vertical mattress sutures of fine monofilament nylon. Only on the rarest occasion is it necessary to place drains in the wounds, but if there is any doubt, this should be done. Leaving wounds in the palm open as advocated by McCash (1964) to allow free drainage is rarely needed. Because the ultimate characteristics of a scar are related to its relation to the lines of skin tension rather than the method of suturing, a well-designed palmar incision will heal satisfactorily without being closed with sutures. However, the open palm requires several weeks of dressing changes and maintenance of good wound hygiene. I employ the open wound technique only if there is a small gap in the palmar wounds that cannot be closed without tension and that does not warrant skin grafting. Unlike the palm, the open wound technique is not satisfactory for fingers because it perpetuates the inflammatory reaction that so greatly increases tendon adhesions and small joint stiffening.

Especially in treating recurrent disease, the surgeon must be prepared to encounter a wound bed that is not suitable for revascularizing skin grafts, such as a substantial segment of flexor tendons without their sheath. Most often the defects are small, so a cross-finger flap will be suitable for wound closure (Fig. 26-25).

With aggressive recurrent disease, radical skin excision with the diseased fascia may leave major wound defects unsuitable for skin grafting or local flap closure. Such cases can be closed only with distant flaps (Fig. 26-26).

Postoperative Care

Attention to the details of postoperative care is important for a smooth and uncomplicated recovery from any hand problem, but especially in the treatment of Dupuytren's disease. The postoperative management logically lends itself to three phases: immediate postoperative, recovery, and maintenance.

If there are no medical contraindications, intraoperative and short-term postoperative administration of systemic steroids is helpful. Not only is pain noticeably reduced, but edema is minimized, which enhances the critical vascularity of the skin flaps.

Exercising of the shoulder and unoperated fingers, to the extent compatible with wound protection, is encouraged after the period of potential bleeding, about 24 hours postoperative. If a hand had minimal disease, active finger exercising is encouraged after 48 hours. If skin grafts were required, a minimum of 6 days of strict immobilization is needed.

The importance of initial and absolutely constant elevation of the hand well above the heart level cannot be overstated. Strict elevation should be continued until effective muscle-pumping action has been recovered. Any throbbing in the hand is an indication of swelling and the need for more or higher elevation, after checking to be certain there are no restricting dressings. Beginning about 8 to 10 days after the surgery, progressive suture removal can be initiated. For skin grafts, the sutures are undisturbed, along with the inner, precisely fitted dressings that had been taped in place, for about 2 weeks.

During the recovery phase, about 10 to 14 days after the surgery, the hand therapist can be most helpful. Any finger that had been in an acutely flexed position will have substantial "extensor lag," or redundancy of its overstretched extensor system. The solution to this is vigorous intrinsic muscle

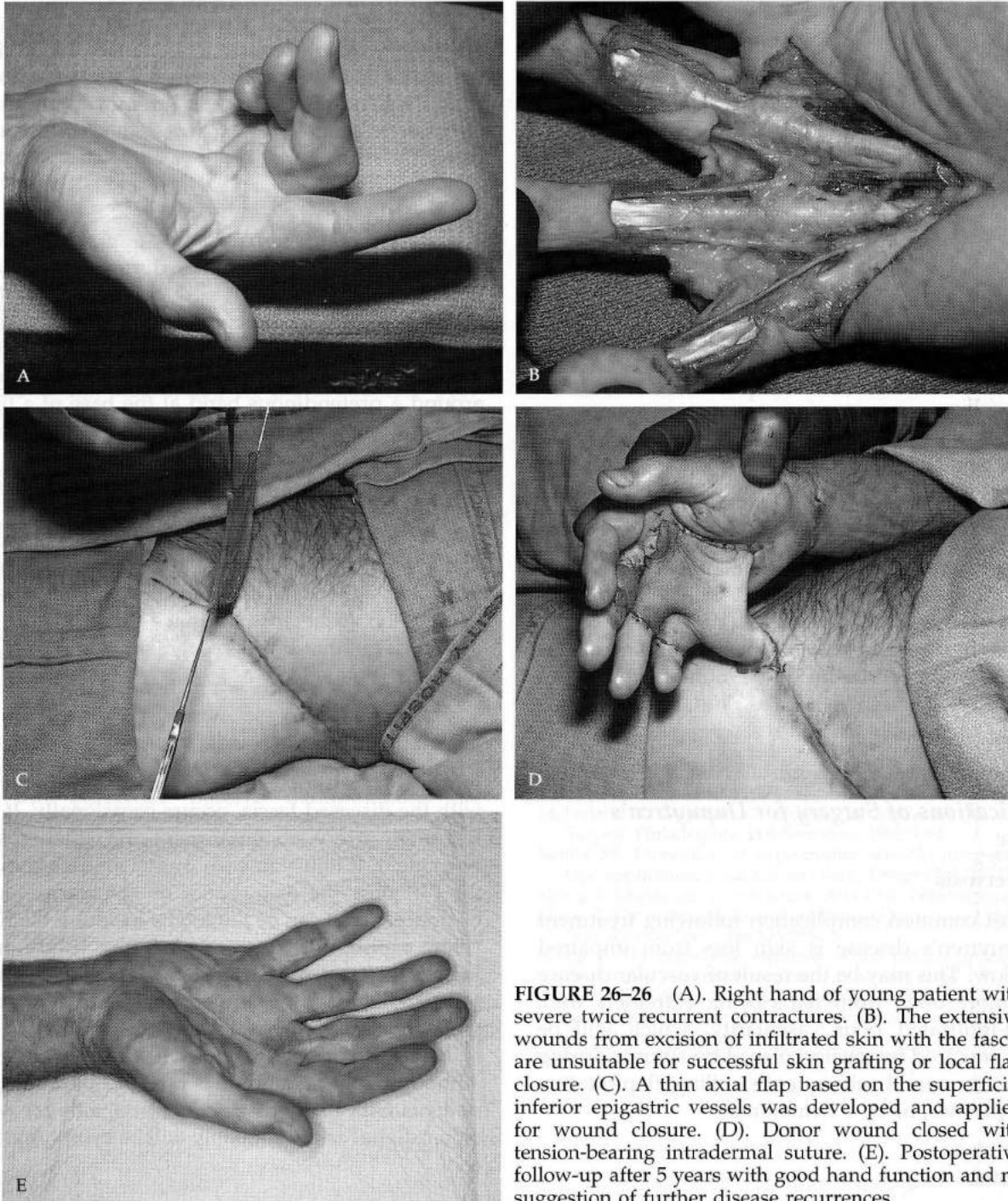


FIGURE 26-26 (A). Right hand of young patient with severe twice recurrent contractures. (B). The extensive wounds from excision of infiltrated skin with the fascia are unsuitable for successful skin grafting or local flap closure. (C). A thin axial flap based on the superficial inferior epigastric vessels was developed and applied for wound closure. (D). Donor wound closed with tension-bearing intradermal suture. (E). Postoperative follow-up after 5 years with good hand function and no suggestion of further disease recurrences.

exercising, with unforced extension splinting, except for specific exercise periods, until the tendency for recurrence of contracture has passed. Power building is important for restoring muscle-pumping action for venous return. A carefully designed home program should be provided. Day splinting can be less for a patient who promptly uses his or her hand very actively, but all patients should use a night resting splint until scars are soft and the tendency to contract has passed. This usually is about 6 months.

For cases with skin grafts or any showing a tendency to scar hypertrophy, a form-fitting silicone elastomer lining can be added to the splints (Fig. 26-27). Initially, the splints are worn between specific exercise periods, but they can be phased out during waking hours as active use of the hand is recovered.

If a patient shows a tendency to scar hypertrophy, a sheet of silicone should be kept directly on the wound. The sheet should be used continuously for a minimum of 8 weeks. No pressure is required. The

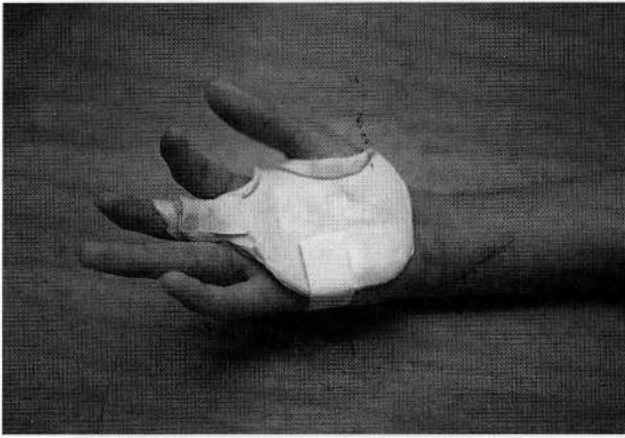

FIGURE 26-27 Insert for postoperative split can be made from form-fitting silicone elastomers. Because there is no slippage, longitudinal stretching of the scar is minimized, which reduces scar hypertrophy.

adhesive character of the silicone rubber minimizes the longitudinal, not transverse, stretching of the scars, as demonstrated by Reiffel (1995).

The maintenance phase of postoperative care is continued over a period of 6 to 8 months. Splints are replaced or adjusted as needed, and any questions that may have arisen are addressed.

Complications of Surgery for Dupuytren's Disease

Skin Necrosis

The most common complication following treatment of Dupuytren's disease is skin loss from impaired blood flow. This may be the result of vascular disease but is more often from flaps being extremely thin. Disease-infiltrated poor vascularity, which will be further impaired by tension placed by sutures during wound closure and subsequent swelling, flap rotation with Z-plasties, or by a hematoma.

Hematoma

Hematoma in a wound following fasciectomy for Dupuytren's disease may cause skin loss and always perpetuates the inflammatory reaction, which is a chief factor leading to development of a stiff and often permanently painful hand. Most patients who develop a large hematoma would have been better off never to have been operated upon.

When the dissection of fasciectomy is finished, I deflate the arm tourniquet to clear acidosis, to check hemostasis, and to observe the adequacy of circulation in all flaps. This also activates the clotting factors. The arm is then again compressed, and the tourniquet

reinflated to take the pressure in all vessels back to zero for wound closure. This causes blood in the wound to be significantly reduced. After the dressing is applied and the tourniquet is removed, the strictest attention should be given to continuous, maximum elevation of the hand.

Nerve Injuries

Fasciectomy for Dupuytren's disease is one of the most technically difficult surgical procedures (sweat producing tumor). Regardless of the skill of the surgeon, injury to a nerve occasionally will occur.

A digital nerve often crosses superficial to and around a pretendinous band at the base of a finger's proximal phalanx. Only at the transverse palmar fascia can the surgeon be completely confident that a nerve crossing the diseased fascial bands will not be encountered. In most instances, damage to a nerve will be recognized before the operation is completed, and a repair should be made. Recovery usually will be favorable although never absolutely complete. The patient should be advised that "damage" to a nerve occurred, but that it was recognized and meticulously repaired.

Arterial Injuries

Injury to the digital arteries, which are intertwined with the diseased fascia, occurs occasionally. If this is to a single artery, no impairment of circulation should be evident. If injury to both digital arteries is distal to the PIP joint, the disturbance of vascularity may not be noticeable. It can be judged by examining the finger's color, capillary refilling, and tissue turgor several minutes after the tourniquet has been deflated. If prominent circulatory impairment persists after treatment for vessel spasm, a determined effort to locate and repair at least one artery should be made. Although finger gangrene is rare except among those patients with badly diseased vessels, a finger without either digital artery probably will be symptomatic and cool.

Incomplete Correction of Deformities

In general, the surgical release of MP joints from flexion is satisfactorily achieved, whereas the correction of PIP joint flexion contractures and DIP hyperextension is very much more difficult and less satisfactory. Efforts to extend an acutely flexed PIP joint must be judicious. It is better that the surgeon leaves moderate deformity than for excessively zealous efforts to result in an unstable joint, an ischemic digit, or restricted flexion from volar plate injury.

Volar Plate Rupture

In releasing acute PIP flexion contractures, correction to more than about 15° can result in volar plate rupture. If this occurs early mobilization must be with an extension blocking splint to maximize a disastrous recurvation deformity.

Persistent Inflammatory Reaction

Some patients even without a hematoma will exhibit a protracted and very stormy postoperative course characterized by persistent pain, swelling, and stiffness with vasomotor instability. This "flare reaction" typically is not manifested in the immediate postoperative period, but becomes apparent 10 to 14 days later and is extremely common among female patients.

Management of the flare reaction is supportive. Because it is not an RSD, stellate ganglion blocks will be of no help. When there are no medical contraindications, use of systemic steroids in short or "flash" courses is indicated. If small joint soreness is prominent, injection of a low-soluble steroid into each joint is helpful.

The hand is splinted in the protective position for rest, but frequent active exercises within tolerance are important, as is use of the hand. Very judicious passive extension to maintain surgical gains can be done, but otherwise passive manipulations are avoided. Although recovery is agonizingly slow, it does follow, in contrast to an RSD.

Anticipated Results of Treatment

The results of treatment are related not only to the patient's diathesis but also to the skill and good judgment of the surgeon, as well as the quality of postoperative care and the patient's intrinsic healing capabilities. Yet the disorder is such that some

individuals may have disappointing results regardless of all efforts and attention to details.

The recurrence rate after primary treatment averages about 4% without skin excision and grafting. Following treatment, considerably more patients will develop the disease in untreated areas. Primary excision of disease-infiltrated skin and grafting are advocated for selected cases with a high diathesis.

The basic treatment goal should be to relieve the patient of restrictions and awkwardness, not to eliminate all signs of the disease. Although incomplete correction of contractures remains one of the most common complications, the consequences of overzealous surgery can be so disastrous that the temptation for perfect correction must be judiciously dampened.

SUGGESTED READINGS

- Breed CM, Smith PJ. A comparison of methods of treatment of PIP joint contractures in Dupuytren's disease. *J Hand Surg [Br]*. 1996;21(2):246-251.
- Dupuytren G. Permanent retraction of the fingers produced by an affliction of the palmar fascia. *Lancet*. 1834;2:222.
- Gabbiani G, Majno G. Dupuytren's contracture: fibroblast contraction? An ultrastructural study. *Am J Pathol*. 1972;66(1):131-146.
- Hueston J. *Dupuytren's Contracture*. Baltimore: Williams and Wilkins; 1963.
- McCash CR. The open palm technique in Dupuytren's contracture. *Br J Plast Surg*. 1964;17:271.
- McFarland R. Dupuytren's disease. In: McCarthy JG, ed. *Plastic Surgery*. Philadelphia: WB Saunders; 1990:5064.
- Reiffel RS. Prevention of hypertrophic scars by long-term paper tape application. *Plast Reconstr Surg*. 1995;96(7):1715-1718.
- Skoog T. Dupuytren's contracture. *Acta Chir*. 1948;96(Suppl).
- Skoog T. The pathogenesis and etiology of Dupuytren's contracture. *Plast Reconstr Surg*. 1963;31:258-267.
- Skoog T. The transverse elements of the palmar aponeurosis in Dupuytren's contracture. *Scans J Plast Surg*. 1967;1:51.
- Tubiana R, Fahrner M, McCullough CJ. Recurrence and other complications in surgery of Dupuytren's contracture. *Clin Plast Surg*. 1981;8(1):45-50.
- Wakefield AR. *Surg Clin North Am*. 1960;40:483.



FIGURE 26-1 The patient had released and splinted the hand in extension for 2 weeks. The contracture is now 15°. The patient had released and splinted the hand in extension for 2 weeks. The contracture is now 15°. The patient had released and splinted the hand in extension for 2 weeks. The contracture is now 15°.