

Palmar Fasciitis and Arthritis Syndrome Associated With Metastatic Ovarian Carcinoma: A Report of Four Cases

Edgar A. Martorell, MD, Peter M. Murray, MD, Jeffrey J. Peterson, MD,
David M. Menke, MD, Kenneth T. Calamia, MD, Jacksonville, FL

Palmar fasciitis and polyarthritis syndrome (PPFAS) is an uncommon paraneoplastic syndrome associated with several malignant neoplasms. We identified 4 patients with PPFAS and ovarian carcinoma. Palmar fasciitis, at times severe, and inflammatory polyarthritis dominated the clinical presentation in all 4 patients. In 3 of our 4 patients the presentation of palmar fasciitis and inflammatory polyarthritis preceded the diagnosis of ovarian carcinoma. Magnetic resonance scanning and biopsy examination of palmar nodules in one patient revealed findings of inflammation and fibrosis. A literature review found 10 other cases of PPFAS associated with ovarian carcinoma. Improvement in palmar fasciitis and inflammatory arthritis often occurs after successful treatment of the ovarian carcinoma. Digital contractures, however, can persist. We recommend a gynecologic examination in any woman presenting with the sudden onset of unexplained hand pain, palmar inflammatory fasciitis, palmar fibromatosis, and digital contractures. (*J Hand Surg* 2004;29A:654–660. Copyright © 2004 by the American Society for Surgery of the Hand.)

Key words: Palmar fasciitis, paraneoplastic syndrome, ovarian cancer, polyarthritis.

Palmar fasciitis and polyarthritis syndrome (PPFAS) is a paraneoplastic syndrome characterized by rapidly progressive flexion contractures of both hands, inflammatory fasciitis, fibrosis, a generalized inflammatory arthritis syndrome, and the diagnosis of a

neoplasm.^{1–4} Rheumatoid factor and antinuclear antibodies (ANAs) usually are negative. Treatment with steroids, nonsteroidal anti-inflammatory drugs, or hand therapy has little effect on PPFAS, whereas successful treatment of the underlying tumor can affect symptoms favorably. In 1967 Bremer⁵ reported the first case of PPFAS specifically associated with ovarian carcinoma. The hand symptoms and findings, however, were diagnosed as reflex sympathetic dystrophy. It was not until the report of Medsger et al¹ in 1982 that the condition of PPFAS was recognized as a condition apart from reflex sympathetic dystrophy and Dupuytren's contracture. Diagnosis of the underlying neoplasm may be overlooked initially because the musculoskeletal symptoms and findings may resemble rheumatologic disorders.⁶ The hand and upper-extremity manifestations often appear before the tumor is clinically evident. The purpose of this study was to review our experience with PPFAS

From the Department of Internal Medicine, Division of Hand and Microvascular Surgery/Department of Orthopedic Surgery, Department of Radiology, Department of Pathology, and the Division of Rheumatology/Department of Internal Medicine, Mayo Clinic, Jacksonville, FL.

Received for publication December 19, 2003; accepted in revised form April 6, 2004.

No benefits in any form have been received or will be received from a commercial party related directly or indirectly to the subject of this article.

Reprint requests: Peter M. Murray, MD, Associate Professor and Consultant, Mayo Clinic, 4500 San Pablo Rd, Jacksonville, FL 32224.

Copyright © 2004 by the American Society for Surgery of the Hand
0363-5023/04/29A04-0016\$30.00/0

doi:10.1016/j.jhsa.2004.04.012

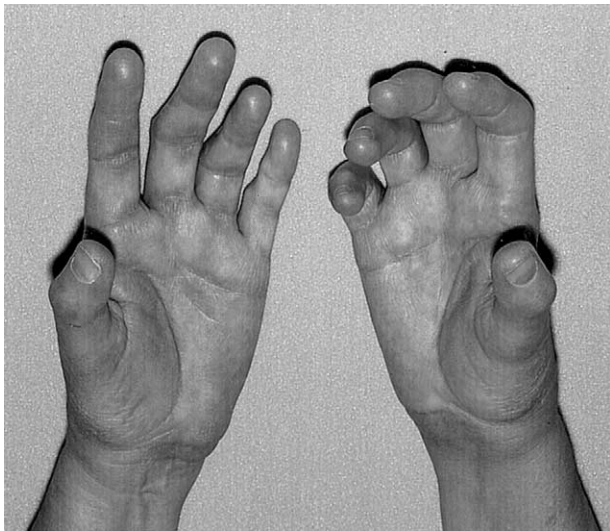


Figure 1. A 62-year-old woman with palmar fasciitis, swelling, and palmar erythema.

associated with ovarian carcinoma, showing the importance of early recognition of this condition.

Case Reports

Patient 1

A 62-year-old woman presented with a 4-month history of bilateral progressive digital stiffness, swelling, and pain, followed by palmar erythema, thickening, nodules, and proximal interphalangeal (PIP) joint and metacarpophalangeal (MCP) joint contractures (Fig. 1). She developed pain, loss of shoulder motion, and synovitis of the wrists. There was no improvement with prednisone (15 mg/d) and she experienced a 22-lb weight loss. A pelvic examination revealed a large left-lower-quadrant mass.

Laboratory testing revealed a normal complete blood count, sedimentation rate, and routine chemistry results. Antinuclear antibody, extractable nuclear antigen antibodies, and rheumatoid factor testing were normal. Cancer antigens 27.29 and 125 were increased at 65.6 U/mL (normal, 0–38) and 188.8 U/mL (normal, 0–34.9), respectively.

Hand radiography showed PIP flexion deformities, degenerative changes of the carpometacarpal joint, and minimal erosions of the ring and small proximal phalanges bilaterally. Shoulder radiographs were unremarkable. A left ring finger nodule biopsy examination performed earlier showed fibroblastic proliferation and fibromatosis (Fig. 2). A magnetic resonance image of the hand showed diffuse fibrosis (Fig. 3). A computed tomography scan of the abdomen and pelvis revealed a 6.7- × 4.4-cm left adnexal

mass with omental caking. There was no adenopathy or free fluid.

The patient had exploratory laparotomy and pelvic tumor debulking. Hand treatment included an occupational therapy referral for home adaptive aids and stretching exercises. Microscopic examination of the adnexal mass and omentum revealed grade IV serous cystadenocarcinoma of the ovary. (Stage IV ovarian carcinoma implies distant metastatic involvement such as the lung or liver parenchyma.) Adjuvant chemotherapy was started with tamoxifen and carboplatin. At the 1-year follow-up evaluation the patient's ovarian carcinoma was in remission. Symptoms of polyarthritis resolved, including pain, and there was an improvement in total active finger motion of the right hand, and the digital contractures resolved on the left hand.

Patient 2

A 70-year-old woman presented with a 7-month history of rapidly progressive spontaneous left-hand digital contractures (Fig. 4) and bilateral heel pain. Approximately 3 months after the onset she was hospitalized for pneumonia and was found to have a pelvic mass. A computed tomography scan showed a 20-cm pelvic neoplasm. A biopsy examination and work-up revealed a stage III papillary serous cystadenocarcinoma of the ovary. (Stage III ovarian carcinoma implies peritoneal metastases outside the pelvis, with or without retroperitoneal lymph nodes, and with or without superficial liver metastases.) The patient was treated with surgical debulking of the tumor as well as tamoxifen and carboplatin chemotherapy.

Three months after the initiation of chemotherapy the patient developed symptoms of an inflammatory polyarthritis. Physical examination was significant for synovitis of PIP and MCP joints of the hand, wrists, elbows, knees, ankles, and feet. There were marked flexion contractures and there was palmar thickening of the fingers of the left hand.

The patient's musculoskeletal symptoms did not respond to nonsteroidal anti-inflammatory agents and required prednisone (15 mg/d) for partial suppression. The carcinoembryonic antigen normalized after chemotherapy but increased again 2.5 years later when pulmonary metastasis developed. One year later the generalized inflammatory MCP and PIP symptoms were controlled with prednisone 5 mg/d. She had no hand pain originally. Contractures of the left hand MCP and PIP joint remained severe and early contractures of the right hand developed. De-

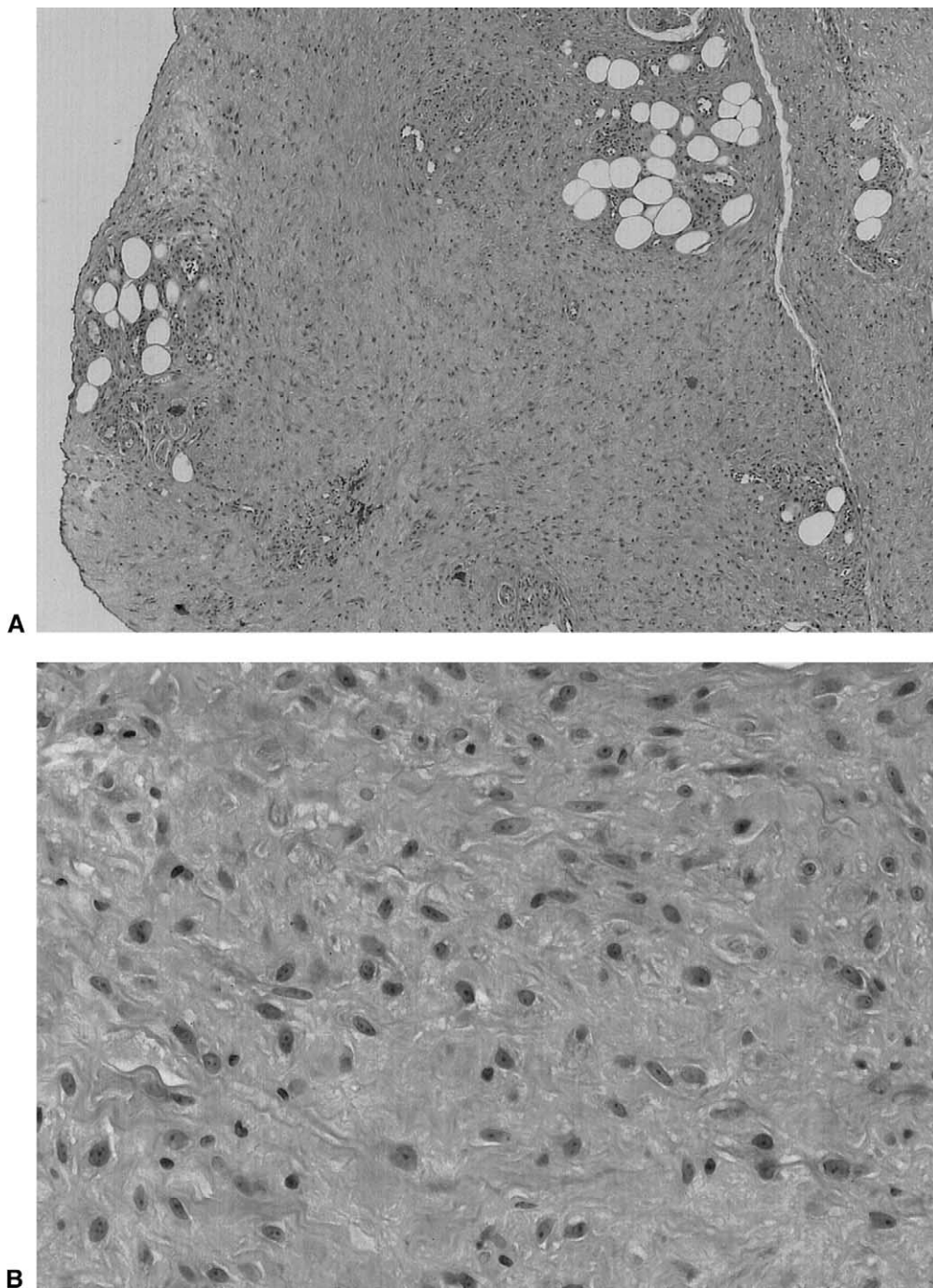


Figure 2. Biopsy specimen of digital nodular fasciitis from patient 1 showing fibroblastic proliferation, perivascular inflammatory cell infiltration, and diffuse fibrosis. (A) Low power, (B) high power.

spite additional chemotherapy there was slow progression of pulmonary metastasis leading to the patient's death 2 years later, 5.5 years after the initial surgery.

Patient 3

A 73-year-old woman developed symptoms of a right trigeminal neuropathy. Three months later ascites developed and a right adnexal pelvic mass was

found. The patient had exploratory laparotomy with bilateral salpingo-oophorectomy and tumor debulking for stage IV ovarian carcinoma with peritoneal metastases. The patient subsequently was treated with carboplatin and cytoxan. Two months later she developed symptoms of carpal tunnel syndrome and Raynaud's phenomenon accompanied by finger joint pain, swelling, stiffness, palmar erythema, induration,

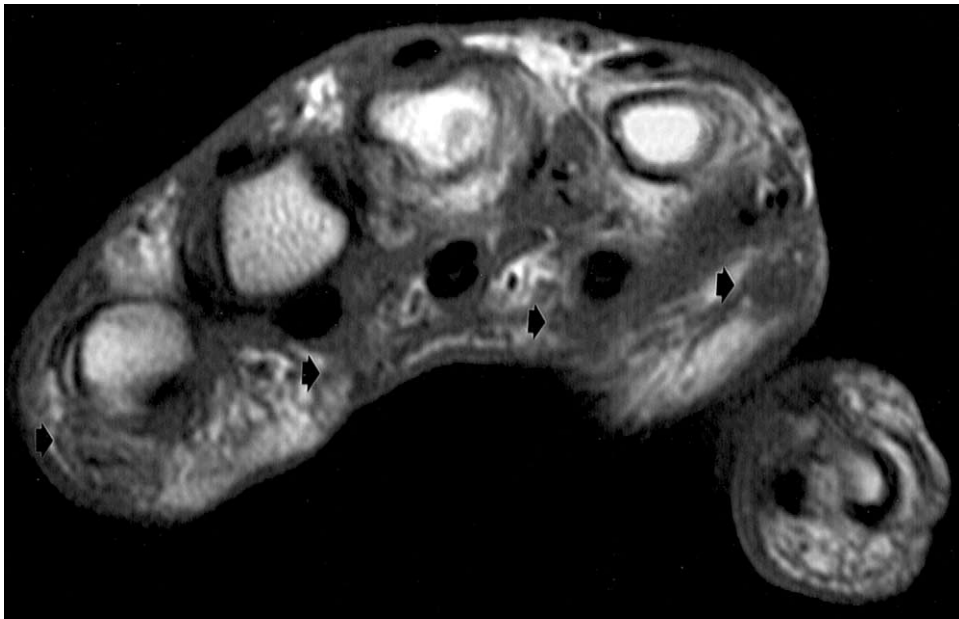


Figure 3. Axial T1-weighted images of the hand of patient 1 showed an ill-defined area of low signal intensity within the subcutaneous tissues of the palmar aspect of the hand and digits (black arrows) consistent with diffuse fibromatosis. This abnormal signal extends to involve the flexor tendons as they course through this region.

and digital contractures. The ANA titer was positive (1:10,000) but the rheumatoid factor was negative. The patient experienced no significant improvement of symptoms with prednisone (15 mg/d) or nortriptyline (40 mg/d). Despite chemotherapy the patient died 1 year after the diagnosis of ovarian malignancy.

Patient 4

A 51-year-old woman presented with a history of a mild inflammatory myopathy for 5 years that had been controlled with low-dose prednisone and methotrexate. She developed symptoms of hand pain and

swelling as well as palmar erythema. No pelvic mass was noted on gynecologic examination. Laboratory studies included negative ANA, rheumatoid factor, and extractable nuclear antigen antibodies. Nine months later she developed increased abdominal girth and a right adnexal mass was noted. She had exploratory laparotomy and debulking of the mass. A biopsy examination confirmed a grade III papillary serous cystadenocarcinoma of the ovary with omental metastasis. The patient was treated with cytoxan, carboplatin, and cisplatin.

Physical examination 7 months after surgery re-

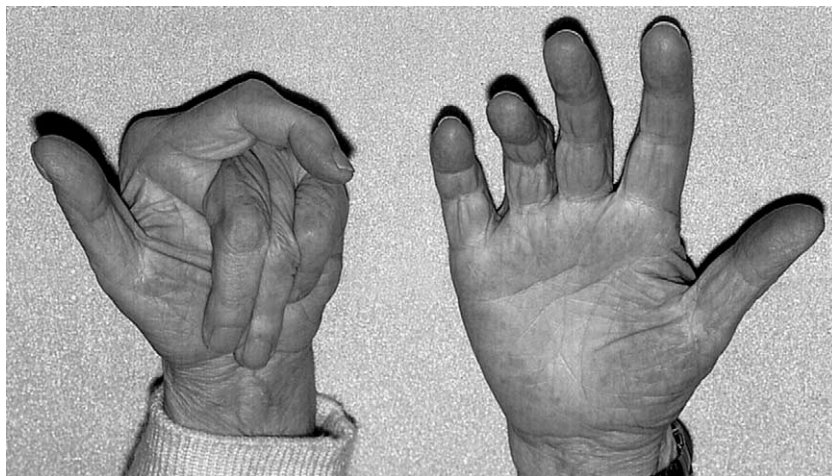


Figure 4. A 70-year-old woman with a 7-month history of spontaneous left-hand digital contractures.

vealed palmar thickening, induration, and digital contractures. At the 4-year follow-up evaluation the patient's cancer was in remission, her palmar erythema and induration had improved, and her hand pain resolved; her digital contractures persisted.

Discussion

Palmar fasciitis and polyarthritis is an uncommon paraneoplastic syndrome that has been associated with a variety of malignancies including chronic lymphocytic leukemia, pancreatic adenocarcinoma, squamous cell carcinoma of the lung, chondrosarcoma, and Hodgkin's disease.³ Naschitz et al⁴ have found a 23% incidence of occult malignancy in 108 patients with undiagnosed rheumatoid disorders. Other paraneoplastic musculoskeletal syndromes are hypertrophic pulmonary osteoarthropathy, dermatomyositis, and carcinomatous polyarthritis.⁶ Polymyalgia rheumatica also may be the presenting manifestation of malignancy. The differential diagnosis for PFPAS includes rheumatoid arthritis, Dupuytren's contracture, scleroderma, eosinophilic fasciitis, and reflex sympathetic dystrophy.⁷ In a literature review we found 10 reported cases of PFPAS associated with ovarian carcinoma, bringing the total number of reported cases to 14 when our cases are considered (Tables 1, 2).

The average age of our 4 patients was 64 years. The onset of musculoskeletal symptoms preceded the diagnosis of ovarian carcinoma in 3 of 4 patients by an average of 5.6 months. Patient 3 was the only patient who developed hand symptoms after the diagnosis of the malignancy and she died 8 months after the diagnosis of ovarian carcinoma. Symptoms of polyarthritis improved after tumor resection and chemotherapy in 3 of our 4 patients. Pain completely resolved in 2 of 3 patients who presented with pain. One patient had no pain relief after treatment and one patient had no pain originally. Contractures, however, were less predictably improved. One patient experienced improvement of hand contractures after treatment of the carcinoma but complete resolution of fibrosis did not occur. Contractures in the remaining 3 patients did not improve. A positive ANA or a positive rheumatoid factor was found in 2 of 4 patients. Inflammatory fasciitis limited to the hands occurred in 2 patients. Systemic polyarthritis with hand synovitis was present in 2 patients.

The average age of the 10 previously reported patients with PFPAS and associated ovarian carcinoma was 56 years (range, 25–75 y), somewhat younger than in our 4 patients. Also our 4 patients

were older than the peak age for ovarian carcinoma diagnosis, 56 years.⁸ Similar to our patients all 8 patients (diagnosis delay time was not available in 2 patients) developed musculoskeletal manifestations before the diagnosis of the ovarian carcinoma, with the diagnosis of ovarian carcinoma coming at an average of 9 months after the onset of hand symptoms. Two patients had musculoskeletal symptoms limited to the hands and 8 patients had hand symptoms plus additional musculoskeletal complaints. Hand therapy was not found useful in any of these patients. Eight of 9 patients died at a mean follow-up time of 7.4 months (follow-up information not available in 1 patient). Four of the 7 patients who died had no improvement in their hand symptoms (follow-up data on hand symptoms not available in 1 patient). The only surviving patient of these 10 patients had improvement in hand symptoms at follow-up evaluation. Considering all 14 cases, 9 of the 10 deceased patients had developed systemic joint complaints.

The cause of PFPAS is unknown. Hormones or neuronal factors produced by the neoplasm are believed to induce the syndrome.⁶ PFPAS may have an immunologic cause owing to the presence of immunoglobulin (IgG, IgM) and complement (C3) deposits on affected tissue.⁹ Medsger et al¹ suggested that a fibroblast proliferative factor was secreted by the tumor. They were unsuccessful, however, in their attempt to show a proliferative factor in the laboratory using the tissue from one affected patient.¹ Considering all reported paraneoplastic syndromes and associated neoplasms the majority of affected patients have been women, which suggests that the female hormonal state may predispose to this syndrome as is the case in most autoimmune diseases.¹⁰ Additionally serum estrogen levels were found to be increased in several cases of PFPAS.^{1,10} Previous reports have confirmed improvement in paraneoplastic musculoskeletal symptoms after chemotherapy but it is unclear whether this is a result of tumor necrosis, immunomodulation, or anti-inflammatory effects.³

When considering all 14 reported cases of PFPAS with associated ovarian carcinoma certain characteristics are apparent. The reported cases of PFPAS and ovarian carcinoma all have in common the development of palmar fibrosis and inflammatory fasciitis with or without digital contractures. The majority of patients developed hand symptoms before the diagnosis of ovarian carcinoma with a mean delay of 8.6 months. The reason that this condition does not respond to anti-inflammatory medications and steroids is unclear. More than half the patients experienced improvement of PFPAS after treatment of the ovar-

Table 1. Summary of 10 Previously Reported Cases of the PFPAS

Study	Age/Gender	Neoplasm	Signs and Symptoms Distribution	Onset of PFPAS Before Neoplasm Diagnosis	Serology ANA/RF	Treatment	Responsiveness of PFPAs to Treatment	Hand Imaging/Pathology	Condition After Neoplasm Diagnosis
Bremer ⁵	50 F	Metastatic ovarian carcinoma	Palmar, shoulder, knee	N/A	Negative/negative	Radiotherapy	Improved	N/A	Deceased at 2 mo
Medsgers ¹	65 F	Metastatic poorly differentiated endometrioid ovarian adenocarcinoma	Palmar, shoulder, elbow, knee	10 mo	N/A	Resection and chemotherapy	No improvement	X-rays: osteoporosis of hands	Deceased at 2 mo
Medsgers ¹	50 F	Poorly differentiated ovarian endometrioid adenocarcinoma with metastasis	Palmar, shoulders, plantar	+4 mo	N/A	Resection and chemotherapy	No improvement	X-rays: osteoporosis with erosions	Deceased at 2 mo
Medsgers ¹	62 F	Anaplastic metastatic ovarian adenocarcinoma	Palmar, knees, shoulder	5 mo	N/A	Resection, chemotherapy, and radiotherapy	Improved	N/A	Deceased at 12 mo
Medsgers ¹	58 F	Poorly differentiated ovarian serous cystadenocarcinoma	Palmar, plantar, wrist, ankle	6 mo	N/A	Chemotherapy and resection	No improvement	X-rays: osteoporosis	Deceased at 4 mo
Medsgers ¹	60 F	Metastatic endometrioid ovarian carcinoma	Palmar, shoulder, knees, ankles	15 mo	N/A	Resection, chemotherapy, and radiotherapy	Improved	X-rays: osteoporosis	Deceased at 10 mo
Medsgers ¹	57 F	Metastatic anaplastic ovarian endometrioid adenocarcinoma	Palmar, shoulder, knees, ankle	23 mo	N/A	Resection, radiotherapy, and chemotherapy	No improvement	N/A	Deceased at 9 mo
Vinker ⁹	25 F	Metastatic ovarian serous papillary carcinoma	Palmar, shoulder, knee	6 mo	Negative/NA	NSAIDs/steroids, resection, and chemotherapy	Mild improvements with NSAIDs/steroids and with resection and chemotherapy	Biopsy: diffuse fibrosis and perivascular mononuclear infiltrate with IgM deposition	Deceased at 18 mo
Shiel ¹⁰	75 F	Metastatic papillary ovarian serous cystadenocarcinoma	Palmar	1 mo	ANA: low titers/NA	Resection and chemotherapy	Improved	X rays: diffuse soft-tissue swelling. Biopsy: acellular dense collagenous connective tissue and lymphocytes and IgG deposition on vessels	Remission at 6 wk
Pfinsgraff ³	57 F	Metastatic ovarian carcinoma	Palmar	N/A	N/A	0	N/A	Pronounced fibrosis with little mononuclear infiltrate	N/A

RF, rheumatoid factor; NSAIDs, nonsteroidal anti-inflammatory drugs.

Table 2. Four Patients With PFPAS and Associated Ovarian Carcinoma From the Mayo Clinic

Patient	Age/Gender	Neoplasm	Signs and Symptoms Distribution	Duration of PFPAS Before dx Neoplasm	Serology ANA/RF	Treatment	Responsiveness to Treatment	Hand Imaging	Outcome
1	62 F	Stage IV ovarian serous cystadenocarcinoma stage III	Palmar erythema, shoulders, wrists, digital swelling and pain, digital contractures, palmar nodules	4 mo	Negative/negative	Steroids, resection, chemotherapy	Contractures resolved, polyarthritis improved, pain resolved	X rays: minor erosions in phalanges	Remission at 1 y
2	70 F	Stage III ovarian serous cystadenocarcinoma stage III	Palms, soles, shoulders, knees, wrist, elbow, digital contractures, digital swelling, palmar fibrosis	4 mo	Negative/positive	NSAIDs, steroids, resection, chemotherapy	Contractures unimproved, polyarthritis improved, no pain originally	X rays: contraction deformities and erosions	Deceased at 5.5 y
3	73 F	Stage IV ovarian carcinoma	Palmar erythema, digital swelling, digital contractures	+2 mo	Positive/positive	Steroids, resection, chemotherapy	Contractures unimproved, pain unimproved	X rays: normal	Deceased at 8 mo
4	51 F	Stage III ovarian serous cystadenocarcinoma	Palmar erythema	9 mo	Negative/negative	Resection, chemotherapy	Contractures unimproved, polyarthritis improved, pain resolved	N/A	Remission at 4 y

dx, diagnosis; NSAIDs, nonsteroidal anti-inflammatory drugs.

ian carcinoma (8 of 13; follow-up data were not available in 1 patient). At an average of 19 months after ovarian carcinoma 9 of 13 patients had died of ovarian cancer. Follow-up evaluation was not available in 1 patient.

In the United States ovarian cancer is the fifth leading cause of cancer deaths among women.¹¹ Currently there are no effective screening methods for ovarian carcinoma and the malignancy frequently remains undiagnosed until metastasis has occurred.¹² Awareness and recognition of the palmar fasciitis and polyarthritis syndrome may allow for earlier diagnosis and treatment of an occult ovarian carcinoma. We recommend a thorough neoplastic work-up including gynecologic examination for any woman presenting with the sudden onset of unexplained hand pain, inflammatory fasciitis, or palmar fibromatosis with or without digital contractures.

References

1. Medsger TA, Dixon JA, Garwood VF. Palmar fasciitis and polyarthritis associated with ovarian carcinoma. *Ann Intern Med* 1982;96:424–431.
2. Leslie BM. Palmar fasciitis and polyarthritis associated with a malignant neoplasm: a paraneoplastic syndrome. *Orthopedics* 1992;15:1436–1439.
3. Pfingraff J, Buckingham RB, Killian PJ, Keister SR, Breton WF, Weinblatt ME, et al. Palmar fasciitis and arthritis with malignant neoplasms: a paraneoplastic syndrome. *Semin Arthritis Rheum* 1986;16:118–125.
4. Naschitz JE, Yeshurun D, Rosner I. Rheumatic manifestations of occult cancer. *Cancer* 1995;75:2954–2958.
5. Bremer C. Shoulder-hand syndrome. A case of unusual aetiology. *Ann Phys Med* 1967;9:168–171.
6. Farhey Y, Luggen M. Seropositive, symmetric polyarthritis in a patient with poorly differentiated lung carcinoma: carcinomatous polyarthritis, hypertrophic osteoarthropathy, or rheumatoid arthritis? *Arthritis Care Res* 1998;11:146–149.
7. Champion GD, Saxon JA, Kossard S. The syndrome of palmar fibromatosis (fasciitis) and polyarthritis. *J Rheumatol* 1987;14:1196–1198.
8. Memarzadeh S, Berek JS. Advances in the management of epithelial ovarian cancer. *J Reprod Med* 2001;46:621–630.
9. Vinker S, Dgani R, Lifschitz-Mercer B, Stoeber ZM, Green L. Palmar fasciitis and polyarthritis associated with ovarian carcinoma in a young patient. A case report and review of the literature. *Clin Rheumatol* 1996;15:495–497.
10. Shiel WC Jr, Prete PE, Jason M, Andrews BS. Palmar fasciitis and arthritis with ovarian and non-ovarian carcinomas. New syndrome. *Am J Med* 1985;79:640–644.
11. Jemal A, Murray T, Samuels A, Ghafoor A, Ward E, Thun MJ. Cancer statistics, 2003. *CA Cancer J Clin* 2003;53:5–26.
12. Barker LR, Burton JR, Zieve PD, Fiebach NH, Kern DE, Thomas PA, et al. *Principles of Ambulatory Medicine*. (6th ed). Philadelphia: Lippincott Williams & Wilkins, 2002: xvi, 1814.