

## TECHNIQUE

# An Alternative Approach in the Treatment of Dupuytren's Contracture Skin Defects: First Dorsal Metacarpal Artery Island Flap

Oguz Ozdemir, MD, E. Coskunol, MD, and T. Ozalp, MD

Departments of Orthopedics and Traumatology

Hand Surgery Divisions

Ege University

Izmir and Celal Bayar University

Manisa, Turkey

## ■ ABSTRACT

Skin defects are often present following surgery for Dupuytren's contracture. The first dorsal metacarpal artery island flap (FDMA) has been used by others for soft tissue reconstruction about the radial and dorsal aspect of the hand, thumb and fingers. We have used it successfully to fill the skin defects often seen following palmar fasciectomy for Dupuytren's contracture. The thin nature of the flap makes it suitable for this application. The FDMA arises from the radial artery just before the radial artery enters the first dorsal interosseous muscle and divides into three branches: 1 to the thumb, 1 to the index finger (radiodorsal branch) and a muscular branch. It is the radiodorsal branch that supplies the skin over the index finger. The island flap based on this artery includes the dorsal terminal branches of the radial nerve and venae comitantes. The flap is formed to include the fascia of the first dorsal interosseous muscle to avoid injury to a possible deep artery and to yield sufficient fat to promote venous drainage. The flap is passed subcutaneously through the first web space and sutured in place to cover the skin defect in the palm. A full thickness skin graft is used to cover the defect over the proximal phalanx of the index finger.

**Keywords:** dorsal metacarpal flap, FDMA, Dupuytren's skin defects

## ■ HISTORICAL PERSPECTIVE

Holevich was the first to report the use of a dorsal metacarpal artery flap in the treatment of hand defects.<sup>1</sup>

Address correspondence and reprint requests to Dr. Oguz Ozdemir, Ege Universitesi Tıp Fakultesi, Ortopedi ve Travmatoloji AD, El Cerrahisi Bolumu, Bornova—Izmir, Turkey. E-mail: oguz@med.ege.edu.tr.

Foucher and Braun described a neurovascular island flap with the first dorsal interosseous artery, which they named the "kite flap."<sup>2</sup> Earley and Milner in 1987 investigated the anatomy and the indications of the first dorsal metacarpal artery flap (FDMA).<sup>3</sup> After the description of the web space anastomoses between the palmar and dorsal arterial network, the flap was used with a distal pedicle.<sup>4</sup> The FDMA island flap based on this branch was used for thumb injuries.<sup>5–7</sup> Some authors also proposed the use of the reverse dorsal metacarpal flap for Dupuytren's contracture skin defects as well.<sup>8,9</sup> We report a different successful application of this flap in a case of skin defect due to Dupuytren's disease.

## ■ INDICATIONS AND CONTRAINDICATIONS

The FDMA is often used in hand injuries for soft tissue coverage. The arc of rotation of the flap allows coverage of the thumb and partial coverage of the dorsal aspect of the four proximal phalanges. Gebhard and Miessl used an extended variation of the FDMA flap including the skin distal to proximal phalanx.<sup>5</sup> Skin loss on the dorsal aspect of the thumb and the hand are good indications for this flap. The palmar aspect of the thumb is another good indication, but due to thin nature of the flap and the relative lack of discriminating sensitivity, it is not ideal.<sup>4</sup>

## ■ ANATOMY

The FDMA arises from the radial artery just before the radial artery enters the first dorsal interosseous muscle and divides into 3 branches: 1 to the thumb, 1 to the index finger (radiodorsal branch), and a muscular branch.<sup>7</sup> The radiodorsal branch of the FDMA supplies the proximal portion of the index finger. The first dorsal

metacarpal artery continues along the second metacarpal over the fascia of first interosseous muscle and gives a nutrient branch to the metacarpal near its head.

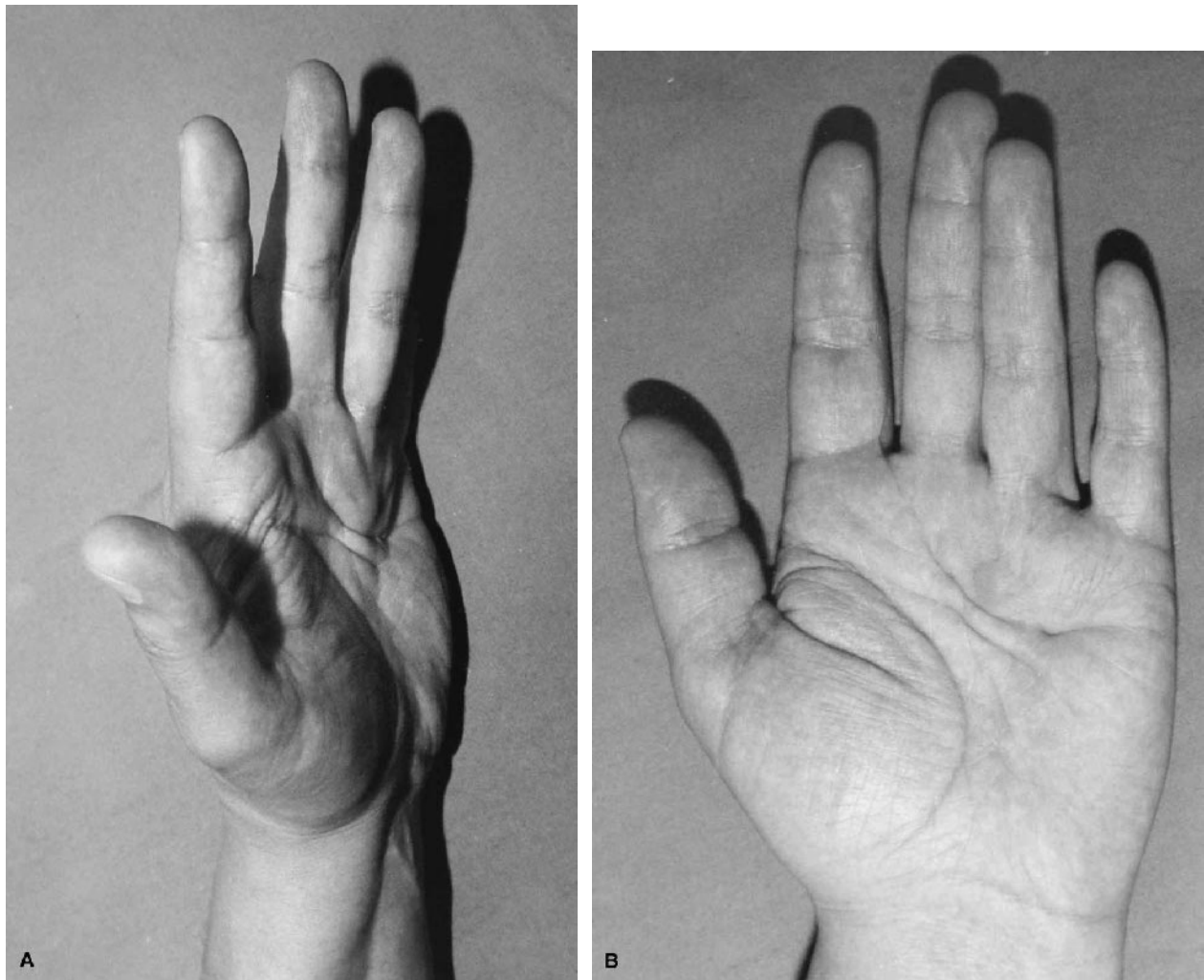
### ■ CASE REPORT AND SURGICAL TECHNIQUE

A 42-year-old male public employee was evaluated with Dupuytren's disease in his nondominant left hand. He had a 30-degree flexion contracture of the ring finger at the MP joint and subcutaneous cords in the palmar area of his left hand (Fig. 1). A partial fasciectomy with a Z-plasty incision was performed. The skin defect was covered with a FDMA island flap from the dorsum of the index finger. The skin island flap was designed using a "lazy" s-shaped incision over the dorsal aspect of the proximal phalanx (Fig. 2A). The island flap, including the dorsal terminal branches of the radial nerve and the

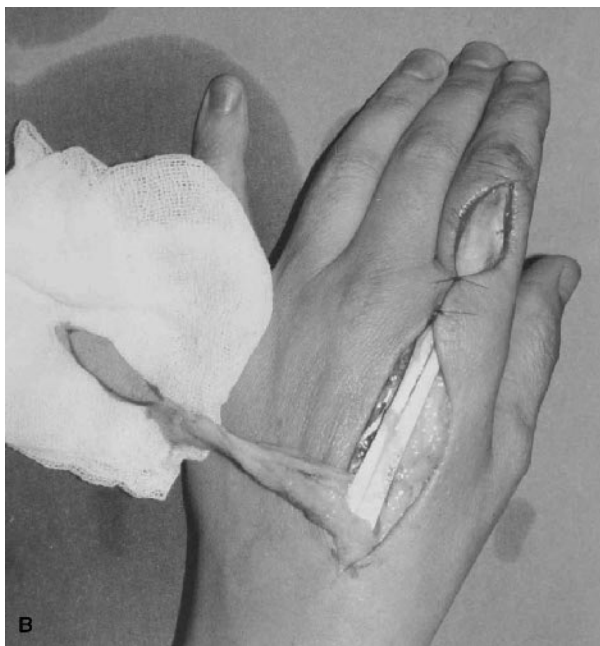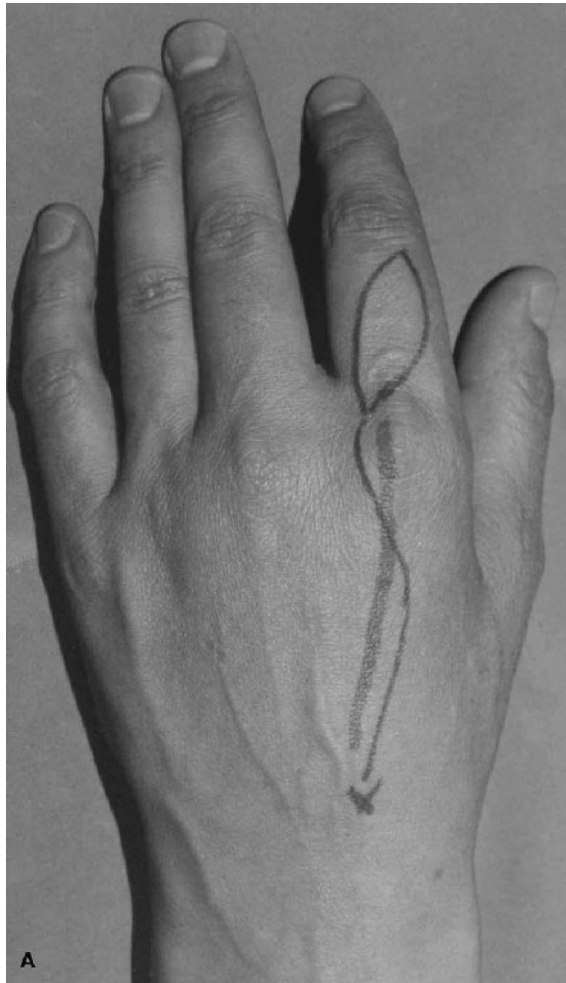
venae comitantes, was dissected to its arterial origin between the 2 heads of the first dorsal interosseous muscle without difficulty (Fig. 2B). The island flap and pedicle included the fascia of the first dorsal interosseous muscle to avoid injury to a possible deep artery and to yield sufficient fat to promote venous drainage. The flap was then passed through the first web space subcutaneously and sutured in place to cover the skin defect in the palm (Fig. 3). A full thickness skin graft was applied to the defect over the proximal phalanx. A vacuum drainage system was used to prevent hematoma formation. A short-arm plaster splint was applied for 2 weeks and a rehabilitation program begun at its removal.

### ■ RESULTS

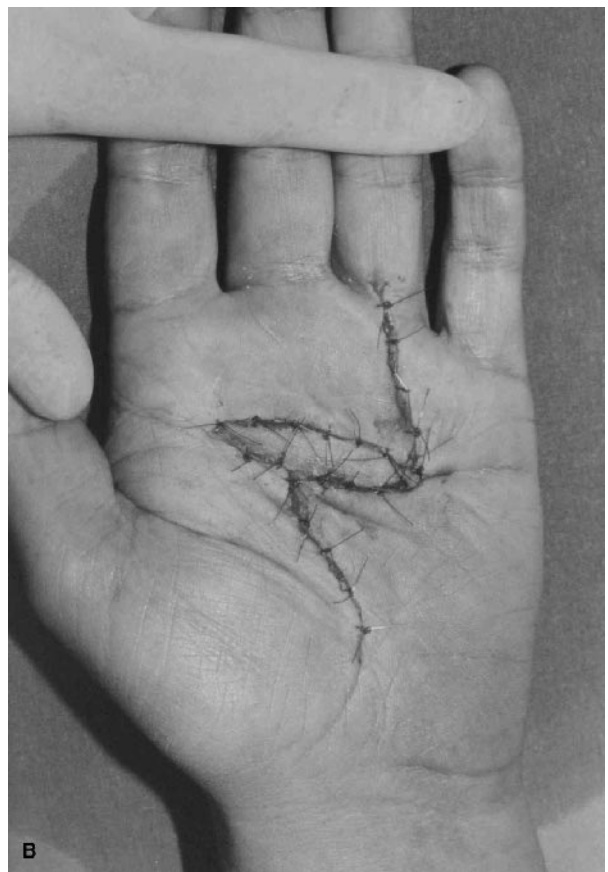
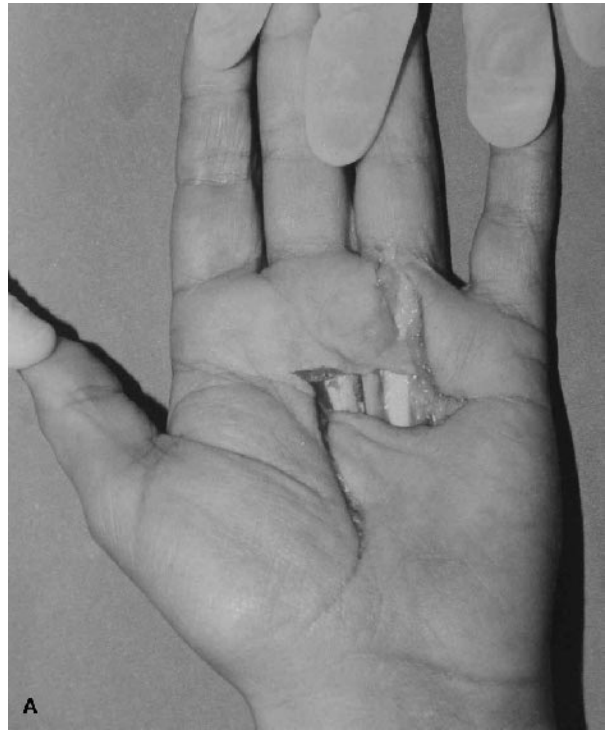
The flap survived completely and the overall postoperative result is depicted in Figure 4.



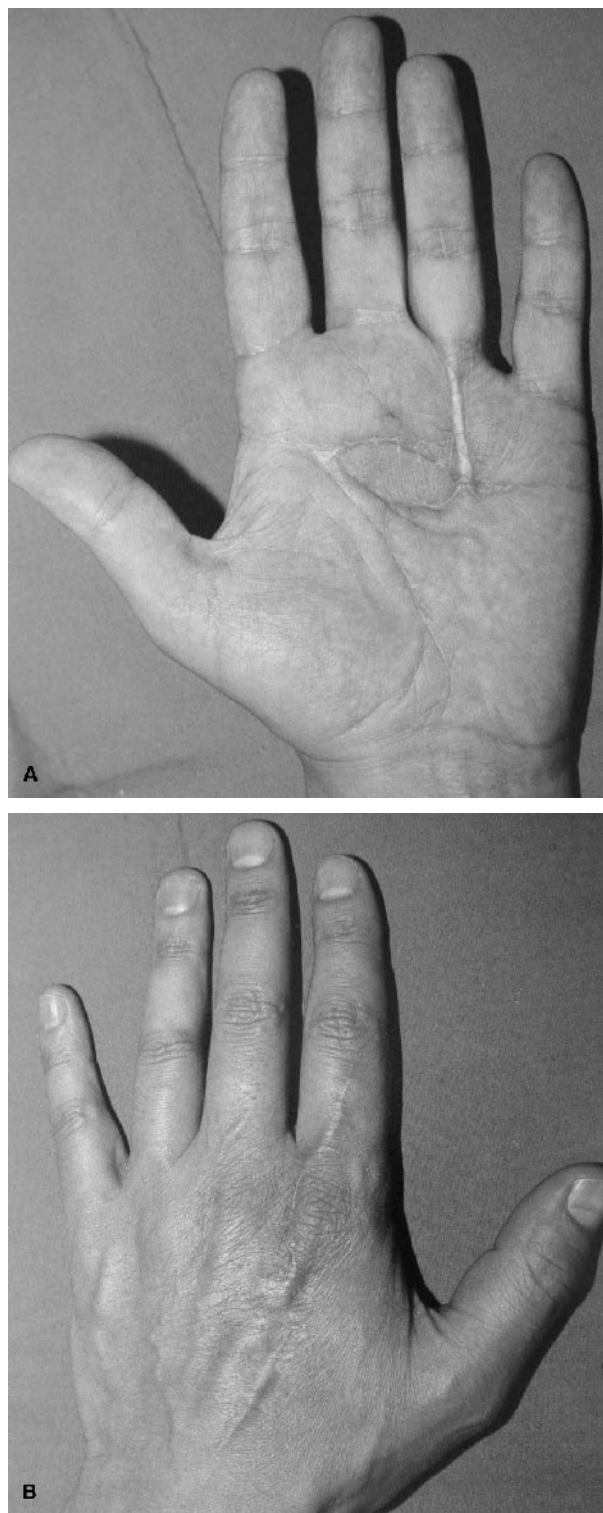
**FIGURE 1.** A Dupuytren's contracture with flexion deformity of the left hand in a 42-year-old male.



**FIGURE 2.** A, First dorsal metacarpal artery island flap design. B, The elevated flap and its pedicle.



**FIGURE 3.** A, The resultant defect after excision of the diseased palmar fascia and (B) the first dorsal metacarpal artery sutured in place.



**FIGURE 4.** Postoperative result at 6 months showing full finger extension.

## ■ DISCUSSION

Dupuytren's autosomal dominant, genetically inherited disease is more common in Nordic people and in Western Europe, and it is rarely seen in the Middle East.<sup>10,11</sup> The recurrence rate of Dupuytren's disease is high. Many authors propose the use of free skin grafts for the skin defects that result from the fasciectomy.<sup>11,12</sup> Ketchum, in his study, concluded that a free skin graft, even if the nodule was left in place after fasciotomy, prevents the recurrence.<sup>12</sup> However, the loss of the elasticity, increased risk of a future scar contracture, and hematoma formation under the graft, are all potential complications of skin grafts.<sup>8</sup> In some cases, after the excision of the unhealthy tissue, neurovascular bundles and flexor tendons need coverage that is better than a free skin graft could provide. Pedicle flaps are good alternatives for the resolution of this problem.

Reverse dorsal third or especially fourth metacarpal artery flaps are proposed and used by some authors.<sup>8,9,13</sup> However, these flaps have some technical problems. The fourth metacarpal artery can be absent in some cases.<sup>3,6,14</sup> To reach the palmar aspect of the hand, the intertendinous connection between the extensor tendons, and in some cases, to free the pedicle more distally, 1 of the extensor tendons to fifth finger must be severed. In addition, the use of this flap could be aesthetically inconvenient for men with hairy dorsal hand skin.<sup>8,13</sup>

With the use of the FDMA island flap, these problems can be avoided. It was reported that first and second metacarpal arteries were found in 100% of cases, but their anatomic positions could be varied.<sup>3,6</sup> Although passing the FDMA flap through the first web space causes some loss of length, using the second web is difficult because of the extensor tendons of the index finger. To compensate for this loss of length, the island flap may be extended distally, as needed, based on the subdermal plexus.<sup>5,7</sup> In this way, the flap can be extended to the palmar surface of the fifth metacarpal. It is difficult to reach the volar part of the proximal phalanx due to the length limitations. Another disadvantage is the need for the skin graft to cover the donor site. However, we believe that the first dorsal metacarpal artery flap represents a good option to cover palmar skin defects, including those located on the ulnar part of the hand.

## ■ REFERENCES

1. Holevich J. A new method of restoring sensibility to thumb. *J Bone Joint Surg.* 1963;45B:496–502.
2. Foucher G, Braun JB. A new island flap transfer from the dorsum of the index to the thumb. *Plast Reconstr Surg.* 1979;63:333–341.
3. Earley MJ, Milner RH. Dorsal metacarpal flaps. *Br J Plast Surg.* 1987;40:333–341.

4. Dautel G., Merle M. Direct and reverse dorsal metacarpal flaps. *Br J Plast Surg.* 1992;45:123–130.
5. Gebhard B., Meissl G. An extended first dorsal metacarpal artery neurovascular island flap. *J Hand Surg.* 1995;20:529–531.
6. Germann G, Hornung R, Raff T. Two new applications for the first dorsal metacarpal artery pedicle in the treatment of severe hand injuries. *J Hand Surg.* 1995;20B:525–528.
7. El-Khatib HA. Clinical experiences with the extended first dorsal metacarpal artery island flap for thumb reconstruction. *J Hand Surg.* 1998;23A:647–652.
8. Ekerot L. The distally-based dorsal hand flap for resurfacing skin defects in Dupuytren's contracture. *J Hand Surg.* 1995;20B:111–114.
9. Ozdemir O, Coskunol E, Isik B. The surgical treatment of Dupuytren contracture with the reverse flow dorsal metacarpal island flap. *Tech Hand Upper Extrem Surg.* 2000;4-2:137–140.
10. Hueston JT. Dupuytren's contracture and occupation. *J Hand Surg.* 1987;12A:657–658.
11. Armstrong JR, Hurren JS, Logan AM. Dermofasciectomy in the management of Dupuytren's disease. *J Bone Joint Surg.* 2000;82B:90–94.
12. Ketchum LD, Hixson FP. Dermofasciectomy and full-thickness grafts in the treatment of Dupuytren's contracture. *J Hand Surg.* 1987;12A:659–663.
13. Benito JR, Ferreres A, Rodriguez-Baeza A, et al. Is the reversed fourth dorsal metacarpal flap reliable? *J Hand Surg.* 2000;25B:135–139.
14. Santa-Comba A, Amarante J, Silva A, et al. Reverse dorsal metacarpal osteocutaneous flap. *Br J Plast Surg.* 1997;50:555–558.