

ORIGINAL ARTICLE

## Ulnar-based skin flap for Dupuytren's fasciectomy

SYED N. ALI, ANDREW MCMURTRIE, SUKH RAYATT & JEREMY O. ROBERTS

*Department of Plastic and Reconstructive Surgery, University Hospitals of North Staffordshire, City General Hospital, Stoke on Trent, Staffordshire, United Kingdom*

### Abstract

The mainstay of treatment for symptomatic Dupuytren's disease is operation. Various skin incisions have been described, showing that there is no single best incision. We describe an ulnar-based skin flap for excision of palmar disease. This flap allows excellent exposure of the diseased area, and provides good access to the palmar aponeurosis including the difficult area on the ulnar side of the little finger. Healing is reliable and digital disease can be approached with a skin extension as required. Recurrent disease can be treated by raising the same flap again.

**Key Words:** *Dupuytren's disease, fasciectomy, skin incisions*

### Introduction

Dupuytren's disease is a benign fibroproliferative disorder of the palmar fascia that causes thickening and contracture of the fascia. It is inherited as an autosomal dominant condition with variable penetrance. The exact aetiology remains controversial, but operation is the mainstay of treatment [1–5].

Many techniques have been used in the management of Dupuytren's disease. Selective regional fasciectomy is currently the most common procedure [1–3].

We describe the use of an ulnar-based skin flap which has been used by the senior author for the past 15 years. We think that this incision provides superior access to the palmar aponeurosis with reliable healing, and allows extension as required. Recurrent disease can also be excised by raising this flap again.

### Patients and methods

#### Method

A list of the patients who had had a Dupuytren's fasciectomy by the senior author was retrieved from the PAS (Patient Administration System). This list was confirmed from the theatre records. We reviewed the notes of these patients, and collected data

including the history of Dupuytren's, details of the operation, any relevant medical history, and details of any postoperative complications.

#### Patients

We have used this method successfully on 35 hands in 32 patients during the past seven years (1995–2002). Of these 32 patients, one patient required a further operation for recurrence. There were six women and 26 men. The mean age at the time of operation was 62 years (range 41–80). The commonest indication for operation was that the fingers were getting in the way ( $n=21$ ), five had weak grip, and five complained of pain. The mean time at which they were reviewed postoperatively was 6 months (range 2–13). The past medical histories included rheumatoid arthritis ( $n=7$ ), diabetes ( $n=4$ ), and one patient misused alcohol. Dupuytren's diathesis was recorded in eight patients.

#### Procedure

The operation is done under general anaesthesia with a tourniquet on the arm, and using a lead hand. A transverse incision is made proximal to the distal palmar crease, and continued parallel to the

crease, curving proximally at the radial border of the middle finger along the thenar crease towards the carpal tunnel (Figure 1a, b). The flap is raised

towards the ulnar border and sutured to maintain retraction. This incision provides excellent exposure for the operation (Figure 1c). Where needed,

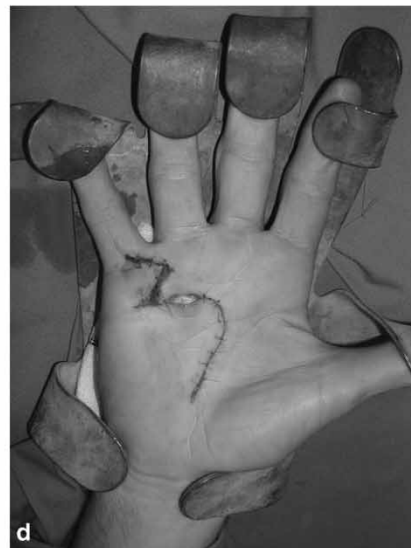
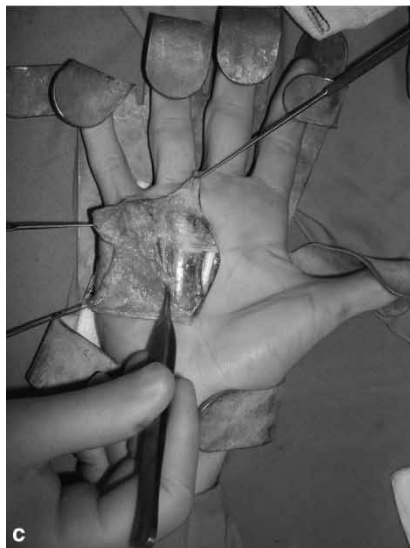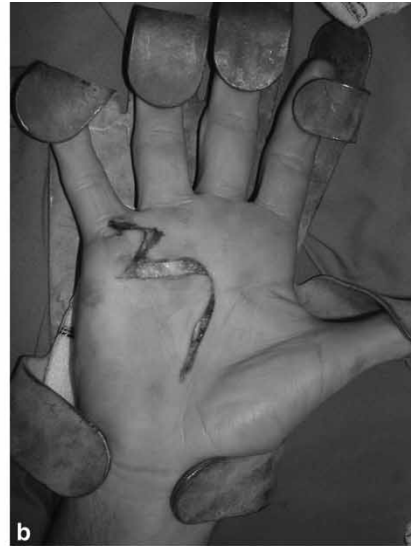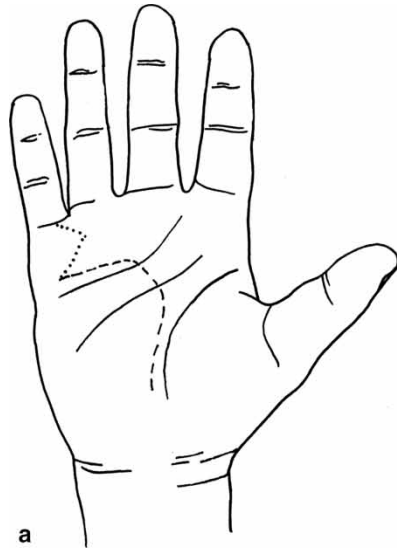


Figure 1. (a) Diagram of ulnar-based skin flap for Dupuytren's fasciectomy. (b) Photograph showing the skin incision with an extension into the little finger. (c) Photograph showing the excellent exposure of the hypothenar area affected by Dupuytren's disease. (d) Photograph showing closure of the wound. Note the opening left for drainage. (e) Photograph showing the samosa dressing.

extension into the finger is made by zigzag extension (Figure 1*a, b*).

The diseased palmar aponeurosis is excised. The wound is closed with interrupted 4/0 non-absorbable nylon sutures, leaving a 2 cm area for drainage proximally (Figure 1*d*). This is covered with tulle and gauze dressing. A triangular arrangement of wool is then applied fashioned like a samosa (Figure 1*e*). This is covered with a firm crepe dressing, with a minimum of two hours elevation postoperatively. The patient is reviewed by the hand therapist before discharge for mobilisation exercises. The dressing is de-bulked at one week and sutures are removed two weeks postoperatively. Splints are used in selected cases.

## Results

There were no major complications. We had one wound infection and one case of flap tip necrosis, both of which were managed conservatively. No further operations were required immediately postoperatively. One patient required further treatment for recurrence five years later, and an ulnar-based skin flap was again raised, based on the original incision.

## Discussion

Many different techniques and incisions have been described for excision of palmar disease, and they differ in the method of release, skin incision, and closure. Skin incisions used for fasciectomy include transverse, longitudinal, or a combination of the two. They may also be used with a combination of local advancement flaps [1–4]. Longitudinal incisions allow wide dissection and visualisation along the length of the digit, and good vascularity is ensured to the local advancement flaps that are required to lengthen the skin and interrupt the linear scar. Though they give good access, however, they are more likely to lead to later contractures. McGregor advocated converting the incision to a zigzag, by incorporating Z-plasties at the end of the operation [1,2,4,5].

The Bruner zigzag incision is also widely used and allows lengthening of the skin with V-Y plasties, but the circulation of the skin flaps may be questionable in cases where the underlying cord is densely adherent to the skin [1–3].

Transverse incisions lie parallel to the palmar creases but may not allow adequate exposure of diseased tissue or of the neurovascular bundles. Those in the palm are useful for treating multiple contractures in the metacarpophalangeal joints, and they may be combined with longitudinal incisions to

explore involved digits. After excision of disease and release of the contracture, closure may be under tension and McCash advocated leaving the wound open to minimise potential compromise of skin flaps and the development of a haematoma [1,4,6]. These incisions may be closed primarily, grafted, or left open. The palmar V-Y plasty allows excision of confluent diseased cords from adjacent fingers with primary closure of skin. The open palm technique is associated with a reduced risk of postoperative haematoma and skin loss, but does require the compliance of the patient with postoperative wound care and splinting [1–3,6,7].

All these incisions and techniques have their merits and disadvantages. The ulnar flap incorporates the helpful elements of most. It is simple to design, simple to close, provides good exposure, and the horizontal part of the incision can be left open if required. Our results indicate complication rates at least comparable with those of other studies [8–12]. The blood supply to the palmar skin is by numerous direct perforating arteries. Recent studies have identified suitable perforators that run along the web fat proximal to the web space [13]. These perforators are adequate to support a large area of surrounding skin. Different versions of V-Y flaps based on these web space perforators have been described [13]. The distal half of the ulnar aspect of the hypothenar eminence that is located over the abductor and flexor digiti minimi muscles, has a constant vascular supply from the ulnar palmar digital artery of the little finger [14,15]. The exact pattern of blood vessels within the flap is not known, but these recent studies may explain the vascular supply to our skin flap [13–15].

No technique can claim to solve all the problems of Dupuytren's fasciectomy, but we think that an ulnar-based skin flap deals with most of them. We used this technique successfully in 35 hands with no serious complications. The type of skin incision used in Dupuytren's disease depends on the severity of disease, type of operation, and the experience of the surgeon. It is important that the surgeon has a number of different techniques at his or her disposal to tailor the operation to the individual patient.

## References

- [1] Conolly WB. Dupuytren's contracture. In: Conolly WB, editor. Atlas of hand surgery. Melbourne: Churchill Livingstone; 1997. p 301–9.
- [2] McGrouther DA. Dupuytren's contracture. In: Green DP, Hotchkiss RN, Pederson WC, editors. Operative hand surgery. 4<sup>th</sup> ed. New York: Churchill Livingstone; 1998. p 563–91.
- [3] Masson JA. Dupuytren's disease. In: Masson JA, editor. Hand IV: Extensor tendons, Dupuytren's disease, and

- rheumatoid arthritis. Selected readings in plastic surgery. University of Texas Southwestern Medical Centre and Baylor University Medical Centre, Dallas, Texas: 2003. Vol. 9. No: 35. p 14–23.
- [4] Saar JD, Grothaus PC. Dupuytren's disease: an overview. *Plast Reconstr Surg* 2000;106:125–34.
- [5] McGregor IA. The Z-plasty in hand surgery. *J Bone Joint Surg* 1967;49B:448–57.
- [6] McCash CR. The open palm technique in Dupuytren's contracture. *Br J Plast Surg* 1964;17:271–80.
- [7] Skoff HD. The surgical treatment of Dupuytren's contracture: a synthesis of techniques. *Plast Reconstr Surg* 2004;113:540–4.
- [8] Rajesh KR, Rex C, Mehdi H, Martin C, Fahmy NR. Severe Dupuytren's contracture of the proximal interphalangeal joint: treatment by two-stage technique. *J Hand Surg* 2000;25B:442–4.
- [9] Bryan AS, Ghorbal MS. The long-term results of closed palmar fasciotomy in the management of Dupuytren's contracture. *J Hand Surg* 1988;13B:254–6.
- [10] Rodrigo JJ, Niebauer JJ, Brown RL, Doyle JR. Treatment of Dupuytren's contracture. Long-term results after fasciotomy and fascial excision. *J Bone Joint Surg* 1976;58A:380–7.
- [11] Tonkin MA, Burke FD, Varian JP. Dupuytren's contracture: a comparative study of fasciectomy and dermofasciectomy in one hundred patients. *J Hand Surg* 1984;9B:156–62.
- [12] Sennwald GR. Fasciectomy for treatment of Dupuytren's disease and early complications. *J Hand Surg* 1990;15A:755–61.
- [13] Rider MA, Riaz M, Small JO. The V-Y palmar flap. *J Hand Surg* 1998;23B:669–72.
- [14] Omokawa S, Ryu J, Tang JB, Han JS. Anatomical basis for a fasciocutaneous flap from the hypothenar eminence of the hand. *Br J Plast Surg* 1996;49:559–63.
- [15] Omokawa S, Yajima H, Inada Y, Fukui A, Tamai S. A reverse ulnar hypothenar flap for finger reconstruction. *Plast Reconstr Surg* 2000;106:828–33.

Copyright of Scandinavian Journal of Plastic & Reconstructive Surgery & Hand Surgery is the property of Taylor & Francis Ltd and its content may not be copied or emailed to multiple sites or posted to a listserv without the copyright holder's express written permission. However, users may print, download, or email articles for individual use.