

Dupuytren's contracture is associated with sprouting of substance P positive nerve fibres and infiltration by mast cells

T E O Schubert, C Weidler, N Borisch, C Schubert, F Hofstädter, R H Straub

Ann Rheum Dis 2006;**65**:414–415. doi: 10.1136/ard.2005.044016

Dupuytren's contracture is a benign proliferative disease of connective tissue. It is characterised by an abnormal fibroblast proliferation and matrix deposition affecting the palmar fascia. There is evidence of genetic predisposition, but the precise cause remains unclear.¹ Inflammatory infiltration of palmar tissue from Dupuytren's contracture has been reported by several authors, who concluded that Dupuytren's contracture may be a chronic inflammatory disease.^{2–4}

To support the inflammatory hypothesis of Dupuytren's contracture we characterised inflammatory elements such as nerve fibres and mast cells in palmar fascias affected by Dupuytren's contracture. We compared 10 specimens from normal palmar fascia excised from subjects with idiopathic carpal tunnel syndrome (age 37–73 years) with 20 specimens from patients with fascias affected by Dupuytren's contracture (age 48–78 years). Patients with diabetes or alcoholism were excluded from the study in order to avoid neuropathic alterations. Immunohistochemical stains were performed on paraffin embedded tissue. After antigen retrieval, primary monoclonal antibody against c-kit, CD45 or S100 (DAKO, Hamburg, Germany) in a dilution of 1:100 was applied. The streptavidin-biotin-peroxidase method was used for visualisation. Cells were counted in 10 high power fields ($\times 400$). The determination of the substance P (SP) positive sensory nerve fibres and sympathetic tyrosine hydroxylase (TH) positive nerve fibres has been described previously.³ TH and

SP positive fibres were counted in 17 randomly selected high power fields ($\times 400$). Statistical analysis was performed by the Mann-Whitney test.

We found a 12-fold increase in the number of mast cells in Dupuytren's contracture in comparison with normal fascia tissue (fig 1A). The number of SP positive nerve fibres in Dupuytren's contracture was also increased (fig 1A). Tissue from both normal palmar fascia and fascia affected by Dupuytren's contracture was devoid of TH positive nerve fibres (data not shown). The number of mast cells correlated positively with the number of SP positive nerve fibres (fig 1B). In 13 Dupuytren samples small lymphocytic infiltrations were found in subcutaneous tissue next to the fibrotic nodules. CD45 and S100 positive Langerhans' cells were only found occasionally within the nodules (table 1).

The presence of inflammatory cells in fascia affected by Dupuytren's contracture was described recently.^{2–4} T lymphocytes² and macrophages⁴ have been found in the diseased tissue. Increased numbers of Langerhans' cells and CD45 positive leucocytes were found both in nodules and at dermoepidermal junctions above the palmar fascia.³ Moreover, an increased expression for mRNA of the proinflammatory cytokines interleukin 1 α , interleukin 1 β , transforming growth factor β , and basic fibroblast growth factor in palmar fascias was observed in Dupuytren's contracture.⁶ Our findings of increased numbers of mast cells and SP positive

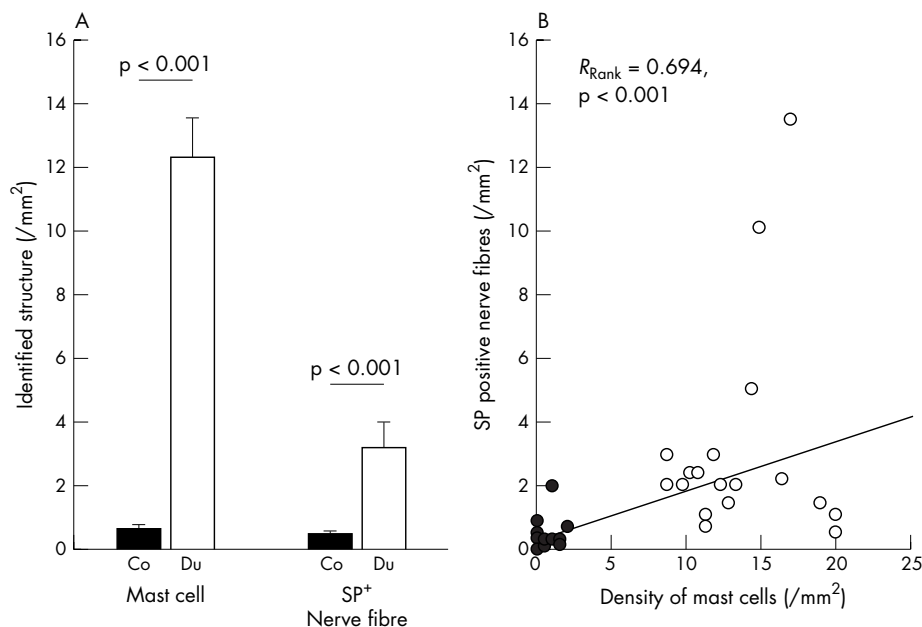


Figure 1 Determination of mast cells and nociceptive nerve fibres in normal palmar fascia tissue and fascia tissue affected by Dupuytren's disease. (A) The numbers of mast cells and nociceptive nerve fibres were determined by immunohistochemistry in 10 control specimens (Co, black bars) and 20 specimens affected by Dupuytren's contracture (Du, white bars) and are expressed per square millimetre. (B) Correlation of density of mast cells and nociceptive nerve fibres in control specimens (black circles) and specimens from Dupuytren's contracture (white circles). The linear regression line, the Spearman rank correlation coefficient, and its p value are given.

Table 1 Density of different types of inflammatory cells present in control fascia tissue and Dupuytren's contracture nodules

Group	Cells in 10 high power fields		Foci of lymphocytic infiltration
	CD45 positive	S100 positive	
Control	0.41 (0.69)	0.16 (0.37)	Absent in all specimens
Dupuytren	*4.91 (3.28)	1.24 (1.26)	Present in 13/20 specimens

Results are shown as mean (SD).
* $p < 0.01$ for the comparison v control.

nerve fibres in Dupuytren's contracture add a new fibrogenic inflammatory component to the already described inflammatory infiltration. Mast cells outnumber the CD45 positive inflammatory cells and S100 positive Langerhans' cells within the fibrotic tissue.

Both mast cells and nociceptive nerve fibres can contribute to the proliferation of fibroblasts on their own and in a coordinated fashion. Mast cells are known to be a source of several fibrogenic mediators such as platelet derived growth factor, transforming growth factor β , and basic fibroblast growth factor that can be released upon stimulation of mast cells.⁷ Mast cell degranulation can be elicited by SP released from nociceptive nerve fibres.⁸ Additionally, SP stimulates the proliferation of fibroblasts and the production of transforming growth factor β by fibroblasts.⁹

A strikingly similar inflammatory condition, termed interstitial cystitis, can take place in the urinary bladder of middle aged white women.¹⁰ It is characterised by fibrosis of the bladder wall, a mast cell rich inflammation, and sprouting of SP positive nerve fibres.¹⁰ We propose that Dupuytren's contracture is an inflammatory disease dominated by mast cells, bearing similarities to interstitial cystitis.

Supported by the DFG (Str 511/10-1) and the University of Regensburg funding programme ReForM C.

Authors' affiliations

T E O Schubert, C Schubert, F Hofstädter, Department of Pathology, University of Regensburg, Regensburg, Germany
C Weidler, R H Straub, Department of Internal Medicine I, University of Regensburg, Regensburg, Germany

N Borisch, Department of Orthopaedic Surgery, University of Regensburg, Bad Abbach, Germany

Competing interest. None.

Correspondence to: Dr T E O Schubert, Department of Pathology, University of Regensburg, Franz-Josef-Strauss-Allee 11, 93053 Regensburg, Germany; thomas.schubert@klinik.uni-regensburg.de

Accepted 21 July 2005

REFERENCES

- 1 **Saar JD**, Grothaus PC. Dupuytren's disease: an overview. *Plast Reconstr Surg* 2000;**106**:125-34.
- 2 **Baird KS**, Alwan WH, Crossan JF, Wojciak B. T-cell-mediated response in Dupuytren's disease. *Lancet* 1993;**341**:1622-3.
- 3 **Qureshi FI**, Hornigold R, Spencer JD, Hall SM. Langerhans cells in Dupuytren's contracture. *J Hand Surg [Br]* 2001;**26**:362-7.
- 4 **Meek RM**, McLellan S, Crossan JF. Dupuytren's disease. A model for the mechanism of fibrosis and its modulation by steroids. *J Bone Joint Surg Br* 1999;**81**:732-8.
- 5 **Miller LE**, Justen HP, Scholmerich J, Straub RH. The loss of sympathetic nerve fibers in the synovial tissue of patients with rheumatoid arthritis is accompanied by increased norepinephrine release from synovial macrophages. *FASEB J* 2000;**14**:2097-107.
- 6 **Baird KS**, Crossan JF, Ralston SH. Abnormal growth factor and cytokine expression in Dupuytren's contracture. *J Clin Pathol* 1993;**46**:425-8.
- 7 **Beer TW**, Baldwin H, West L, Gallagher PJ, Wright DH. Mast cells in pathological and surgical scars. *Br J Ophthalmol* 1998;**82**:691-4.
- 8 **Mori N**, Suzuki R, Furuno T, McKay DM, Wada M, Teshima R, et al. Nerve-mast cell (RBL) interaction: RBL membrane ruffling occurs at the contact site with an activated neurite. *Am J Physiol Cell Physiol* 2002;**283**:C1738-44.
- 9 **Lai XN**, Wang ZG, Zhu JM, Wang LL. Effect of substance P on gene expression of transforming growth factor beta-1 and its receptors in rat's fibroblasts. *Chin J Traumatol* 2003;**6**:350-4.
- 10 **Selo-Ojeme DO**, Onwude JL. Interstitial cystitis. *J Obstet Gynaecol* 2004;**24**:216-25.

Arterial stiffness in Behçet's disease: increased regional pulse wave velocity values

H K Chang, S K Kim, S S Lee, M Y Rhee

Ann Rheum Dis 2006;**65**:415-416. doi: 10.1136/ard.2005.043430

Diverse vascular lesions occur in about one third of patients with Behçet's disease (BD). Endothelial dysfunction is known to have an important role in the development of these lesions.¹ Acute systemic inflammation and chronic systemic vasculitis are associated with endothelial dysfunction.^{2,3} Moreover, inflammation is an important risk factor for future cardiovascular events.⁴ These findings have led to the hypothesis that acute and chronic inflammatory processes associated with BD may cause endothelial dysfunction, which can then lead to a subsequent increase of arterial stiffness and vascular damage that are

closely related to the clinical course of BD. Arterial stiffness is a reliable predictor of subsequent cardiovascular mortality and vascular damage. Pulse wave velocity (PWV) is an ideal indicator of arterial stiffness.^{5,6} Most investigators have studied PWV only in the aorta, although PWV should be measured along the entire arterial tree.⁶ Therefore we investigated PWV of different regions in patients with BD.

This study included 53 patients with BD who fulfilled the International Study Group criteria⁷ and 65 controls. Subjects with hypertension, diabetes mellitus, or a previous history of coronary artery disease or myocardial infarction were