

ORIGINAL ARTICLE

Immunohistochemical evidence for Zic1 coexpression with β -catenin in the myofibroblast of Dupuytren disease

ILSE DEGREEF¹, LUC DE SMET¹, RAF SCIOT², JEAN-JACQUES CASSIMAN³ & SABINE TEJPAR⁴

¹Orthopaedic Department, Hand Unit, University Hospitals Leuven, Pellenberg Campus, Pellenberg, ²Department of Pathology, University Hospitals, Leuven Campus Sint-Raphael, Leuven, ³Department of Human Genetics, ⁴Internal Medicine, Gastroenterology, University Hospitals, Leuven Campus Gasthuisberg, Leuven, Belgium

Abstract

The active cellular component in Dupuytren disease (DD) is the α smooth muscle actin (α SMA) containing myofibroblast. The underlying regulatory processes in activation of myofibroblasts resemble the pathophysiology of certain types of cancer. Accumulation of β catenin has been shown in many fibroproliferative processes, including DD and recent findings attributed a possible role to the Zic1 transcription factor. To assess Zic1 expression in DD and investigate its relation with the accumulation of β catenin, neighbouring tissue samples in 20 patients with DD were stained immunohistochemically with monoclonal antibodies for β catenin, α SMA, and Zic1. Histological appearance was staged according to Luck. Cell rich areas with accumulation of β catenin in myofibroblasts that stained for α SMA and showed apparent Zic1 coexpression were obvious. This coexpression seemed independent of proliferative or involutinal histological staging. We found only Zic1 expression in residual stages. A different pattern of expression of protein in the residual stage may support earlier suggestions of a cellular heterogeneity with the existence of different cell (sub)populations in nodules and cords. On the other hand coexpression of Zic1 and β catenin may indicate a relation between Zic1 and the Wnt pathway. Further studies are needed to elucidate cellular origin, potential heterogeneity and activity of the myofibroblasts in DD, and to define the exact role of Zic1 in fibroproliferative processes, wound healing, and cancer. The fibroblast in DD is an interesting model for future experiments.

Key Words: Zic, β -catenin, Dupuytren disease, myofibroblast, histology

Introduction

Dupuytren disease (DD) affects mainly northern Europeans of Celtic descent, and has a prevalence of 40% in the Scandinavian population [1,2]. Epidemiological surveys have shown family clustering, raising even more suspicion that there are underlying genetic factors [3]. Its common association with oncological diseases or early death and its tendency to local recurrence after resection have lead to basic research on overlapping pathophysiological processes and certain types of cancer [3,4].

The underlying fibroproliferative process features nodules (focus of proliferating fibroblasts) and cords (cell-poor densely packed collagen fibres) in the palmar fascia [5]. The cellular component in the nodules is the myofibroblast that stains for α -smooth

muscle actin (α -SMA) often referred to as 'active' fibroblast [6,7].

Several immunohistochemical, microarray analyses, and PCR studies in DD have shown that β -catenin is dysregulated with increased concentrations in cytoplasm [8–10]. β -catenin is a central signaling molecule in the canonical Wnt-pathway [8]. By regulating proliferation of fibroblasts and the fate or differentiation of cells, the Wnt-pathway has an important role in fibrous tumours such as desmoid tumours [11,12]. In contrast to desmoids, however, no alterations in expression of upstream regulating Wnt genes have been found, nor have mutations been identified [9,13,14].

An important role in neural, muscle, and skeletal development has been attributed to the Zic gene

family [15]. The Zic1 gene is involved in early patterning and dorsal neural tube development by regulating cellular proliferation and differentiation, contributing to the oncogenesis of medulloblastoma [16]. It has been suggested that Zic1 is an upstream regulator of several Wnt-genes [17]. Recently, Zic1 was given a role in fibroproliferative processes because its expression had been isolated in desmoid tumours, hypertrophic scars, and DD [18].

To define the myofibroblast in DD further and explore β -catenin and Zic1 expression patterns, neighbouring sections of 20 surgical samples were stained with three different markers (β -catenin, Zic1, and α -SMA) to study their regional distribution and cellular coexpression.

Material and methods

Biopsy material of nodules from the palmar fascia and cords of 20 patients with DD were collected, and five neighbouring samples (5 μ m) were prepared for simultaneous immunohistochemical staining (6%-formalin-fixed and paraffin-embedded). After deparaffinising and rehydrating the samples, endogenous peroxidase activity was quenched by a 0.3% hydrogen peroxide/methanol solution for 30 minutes. In the samples for β -catenin staining this was done with citric acid 10 mmol/l (pH 6) for 30 minutes on a 98° water bath. Blocking with serum bovine albumin was followed by incubation with mouse monoclonal antibodies for β -catenin (Transduction Laboratories, San Diego, CA), monoclonal antibodies for Zic1 [18], α -SMA (DAKO, Denmark), a negative control without antibody, and a positive control to show stainability of the cells with fibroblastic origin with vimentin (Sigma, St. Louis, USA). Controls for antibody specificity of Zic1 and β -catenin were done as in preceding studies [18].

Antibodies were visualised with Envision anti-mouse immunoglobulin (DAKO, Denmark). After the samples had been washed in phosphate buffered saline and bovine serum albumin, they were stained with diaminobenzidine under direct control using the microscope. Before the samples were mounted they were further stained with haematoxylin.

Neighbouring slides were compared under the microscope, with histological staging as described by Luck (proliferative, involutional, and residual stage) and attention was paid to the distribution of stained cells and antibody coexpression [2].

Results

All but the negative control samples stained immunohistochemically for vimentin, β -catenin, Zic1, and

α -SMA. All cells with a fibroblastic origin stained diffusely for vimentin.

β -catenin, Zic1, and α -SMA were profuse, but restricted to certain areas of the tissue samples. Zic1 staining was most obvious, with prominent nuclear and some cytoplasmic expression. It was seen in bundles of somewhat larger and organised spindle shaped cells with prominent nuclei and few intercellular matrix. These areas were categorised as histological zones of proliferation (few oriented cell groups) or involution (clearly oriented cell groups) according to Luck [2]. Although slightly less apparent, β -catenin and α -SMA staining areas grossly corresponded with similar areas in neighbouring samples (Figure 1). The cytoplasm and nucleus stained for β -catenin, where it was prominent.

Around and in between these zones there were areas that did not stain and were categorised as proliferative or involutional zones.

The third histological zone consisted of Luck's [2] residual stage with many parallel collagen fibres and few embedded cells, which showed some nuclear Zic1 staining with none for α -SMA or β -catenin (Figure 2).

There were two clearly different histological images: a cell-rich and a cell-poor zone. The latter was clearly Luck's residual zone, in which there were cords with few cells and meticulous collagen orientation [2]. The cell-rich zone showed alternating regions of cells that stained for antibody or not in a more or less oriented fashion (Figure 3). The neighbouring samples indicated coexpression of Zic1, β -catenin, and α -SMA in mainly matching regions. These stained regions contained somewhat larger cells with bigger nuclei that had variable orientation and few intercellular matrices and consisted of alternating proliferative and involutional stages. In between them were regions with similar cell-rich patterns that contained only non-staining cells.

Discussion

Myofibroblasts are considered to be phenotypical modified fibroblasts as they feature typical smooth muscle cell properties, such as bundles of α -SMA positive microfilaments, and can be found in inflammatory tissues, tumour stroma, wound healing, and in Dupuytren disease, and are often referred to as the 'activated' fibroblasts [7,19]. Further definition of myofibroblasts is needed to understand the activation processes that lead to its collagen production, tissue contraction, and permanent finger contractures in DD [6].

A crucial role has been attributed to the well-studied signalling Wnt-pathway in embryonic

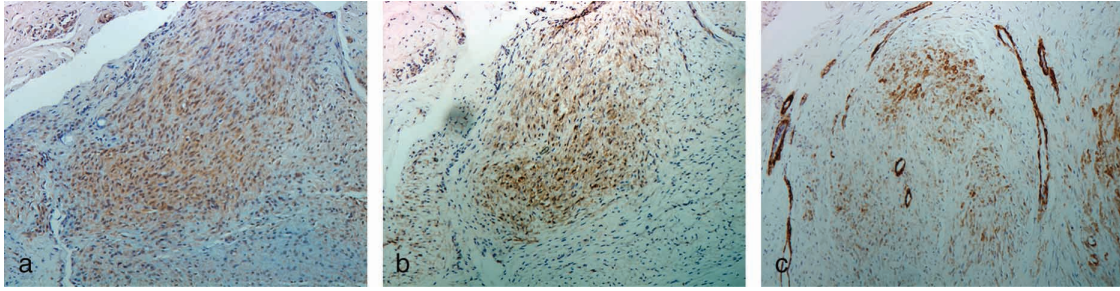


Figure 1. Immunohistochemical micrographs (original magnification $\times 400$) of a selected nodular region in a proliferative stage, with advanced cellularity and poor orientation. Immunohistochemical staining shows (a) corresponding Zic1, (b) β catenin, and (c) α SMA expression in neighbouring samples, showing Zic1 and β catenin coexpression in myofibroblasts (secondary staining with haematoxylin). The staining region is embedded in surrounding non staining fibroblasts.

development [8]. Accumulation of its key-protein β -catenin has been shown in many fibroproliferative processes, including different types of cancer as well as DD [5,8,11,18,19]. Cellular tension may modulate β -catenin expression in DD, as was shown both in vivo and in vitro [5].

In contrast to epithelial cells, in which a purely membranous β -catenin-staining pattern is present, membranous and cytoplasmatic β -catenin staining is seen in endothelial cells and normal fibroblasts [14]. In the present study, high-level nuclear staining of β -catenin was shown in DD, which indicates a possible dysregulation of the Wnt-pathway with accumulation of β -catenin and secondary nuclear translocation [12]. The prominent nuclear β -catenin staining was also present in deep fibromatosis (desmoid tumour), in contrast to most other fibroproliferative and mesenchymal tumours, in which only cytoplasmatic accumulation is seen [20].

Zic genes are a common theme in embryonic development as is the Wnt-pathway [20]. A regulating role in cell proliferation has been attributed to the Zic1 gene during the embryonic stage [15]. No Zic1 has been reported in adult tissue outside the brain, and brain tumours, until recently when our group described its expression in fibroproliferative

diseases and proliferating skin fibroblasts through an epigenetic mechanism [18].

In cerebellar development and brain tumours Zic staining is usually limited to the nucleus [16]. Here also clear nuclear Zic1 staining was present, but it was associated with cytoplasmatic staining to some extent, as was also previously noticed in other studies [18]. Zic1 translocation to the cytoplasmatic compartment in the presence of I-mfa has recently been described in mice [21].

Our immunohistochemical study of β -catenin, α -SMA, and Zic1 in DD has shown largely overlapping staining patterns, which suggest coexpression of Zic1 and β -catenin in clusters of activated myofibroblasts. Although neighbouring samples are closely related and histologically similar tissues, in reality there is a slight difference in the site, which is inevitable. This, in combination with an inherent antibody-specific distinction in the intensity of staining and different tissue preparation (the 98° quenching bath necessary for β -catenin) may explain minor differences in the intensity of antibody expression and slightly incomplete overlap (Figure 1).

The α -SMA staining shows that the cells that accumulate β -catenin and Zic1 are myofibroblasts in their 'active' state. Recently, an upstream regulating

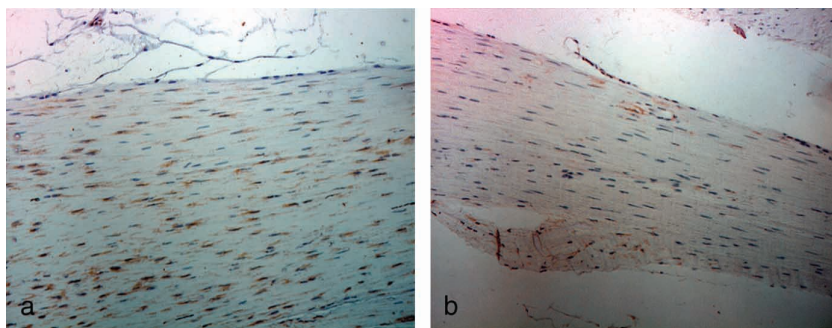


Figure 2. Immunohistochemical micrographs (original magnification $\times 400$) of well orientated collagen rich and cell poor cords in a residual stage of Dupuytren disease. (a) Some nuclear Zic1 expression, (b) without β catenin accumulation (secondary staining with haematoxylin).

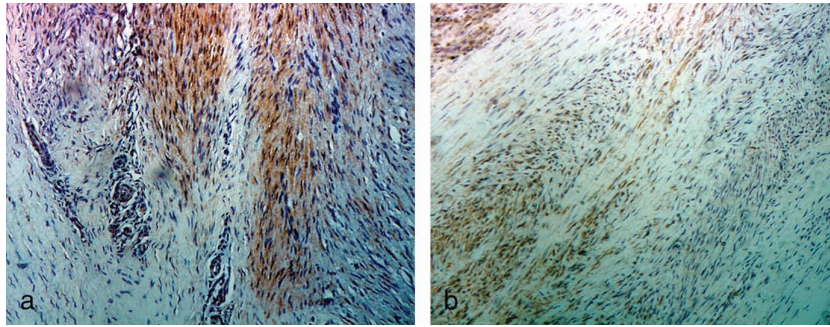


Figure 3. Examples of tissue samples of different patients showing cell rich regions with obvious cellular alignment and orientation, containing Zic1 stained areas alternating with areas that did not stain for Zic1 (original magnification $\times 400$, secondary staining with haematoxylin).

role of several Wnt-genes for Zic1 has been suggested [17]. Although recent reports have failed to correlate Wnt expression with the known β -catenin dysregulation in DD, our findings of Zic1 and β -catenin coexpression do not rule out an indirect, possibly upstream, relation between Zic1 and the Wnt-pathway [12,17]. The signal transduction pathway of Zic is not yet well understood, but a potential modulating role for it has been suggested in the Hedgehog pathway, which, similarly to the Wnt-pathway, is involved in development, formation of body pattern, and tumorigenesis [22]. Antagonism between Hedgehog and Wnt signaling pathways has been shown in colorectal cancers [23]. Zic family proteins may function as transcriptional coactivators, as its prominent nuclear site suggests involvement in RNA processing or transport from the nucleus to the cytoplasm [24].

As well as variable fibroblastic activity within a single lesion, the striking inconsistency in cellular Zic1 and β -catenin expression with cellular clustering of these markers could also indicate cellular heterogeneity with the existence of different cell (sub-)populations. The isolated Zic1 expression pattern in the fibroblasts at the residual stage may even point to a different cellular origin in cords and nodules of DD, as was suggested earlier based on differences in the metabolic activity of these fibroblasts [25].

Further studies are needed to elucidate cellular origin, potential heterogeneity, and activity of the myofibroblasts, and to define the exact role of Zic1 in fibroproliferative processes including its potential relation with the Wnt-pathway. To explore myofibroblastic activation mechanisms in fibroproliferative processes or even in cancer and wound healing, the fibroblast in DD may be an interesting model for future experiments.

Acknowledgements

Monoclonal antibodies for Zic1 were kindly supplied by Professors K. Mikoshiba and J. Aruga, Molecular

Neurobiology Laboratory, Tsukuba Life Science Center, Inst. of Phys. and Chemical Research, Tsukuba, Ibaraki, Japan

References

- [1] Gudmundsson KG, Arngrimsson R, Sigfusson N, Bjornsson A, Jonsson T. Epidemiology of Dupuytren's disease: clinical, serological and social assessment. The Reykjavik Study. *J Clin Epidemiol* 2000;53:291–6.
- [2] Luck V. Dupuytren's contracture. *J Bone Joint Surg* 1959; 41A:635–64.
- [3] Hindocha S, John S, Stanley JK, Watson SJ, Bayat A. The heritability of Dupuytren's disease: familial aggregation and its clinical significance. *J Hand Surg* 2006;31A:204–10.
- [4] Wilbrand S, Ekblom A, Gerdin B. A cohort study linked increased mortality in patients treated surgically for Dupuytren's contracture. *J Clin Epidemiol* 2005;58:68–74.
- [5] Tomasek JJ, Vaughan MB, Haaksma CJ. Cellular structure and biology of Dupuytren's disease. *Hand Clin* 1999;15: 21–34.
- [6] Cordova A, Tripoli M, Corradino B, Napoli P, Moschella F. Dupuytren's contracture: an update of biomolecular aspects and therapeutic perspectives. *J Hand Surg* 2005;30B: 557–62.
- [7] Kalluri R, Zeisberg M. Fibroblasts in cancer. *Nat Rev Cancer* 2006;6:392–401.
- [8] Bowley E, O'Gorman DB, Gan BS. Beta catenin signaling in fibroproliferative disease. *J Surg Res* 2007;138:141–50.
- [9] O'Gorman DB, Wu Y, Seney S, Zhu RD, Gan BS. Wnt expression is not correlated with beta catenin dysregulation in Dupuytren's Disease. *J Negat Results Biomed* 2006;30: 5–13.
- [10] Varallo VM, Gan BS, Seney S, et al. Beta catenin expression in Dupuytren's disease: potential role for cell matrix interactions in modulating beta catenin levels in vivo and in vitro. *Oncogene* 2003;22:3680–4.
- [11] Bhattacharya B, Dilworth HP, Iacobuzio Donahue C, et al. Nuclear beta catenin expression distinguishes deep fibromatosis from other benign and malignant fibroblastic and myofibroblastic lesions. *Am J Surg Pathol* 2005;29:653–9.
- [12] Ng TL, Gown AM, Barry TS, et al. Nuclear beta catenin in mesenchymal tumors. *Mod Pathol* 2005;18:68–74.
- [13] Alman BA, Li C, Pajerski ME, Diaz Cano S, Wolfe HJ. Increased beta catenin protein and somatic APC mutations in sporadic aggressive fibromatoses (desmoid tumors). *Am J Pathol* 1997;151:329–34.

- [14] Tejpar S, Nollet F, Li C, et al. Predominance of beta catenin mutations and beta catenin dysregulation in sporadic aggressive fibromatosis (desmoid tumor). *Oncogene* 1999;18:6615–20.
- [15] Aruga J. The role of ZIC genes in neural development. *Mol Cell Neurosci* 2004;26:205–21.
- [16] Yokota N, Aruga J, Takai S, et al. Predominant expression of human ZIC in cerebellar granule cell lineage and medulloblastoma. *Cancer Res* 1996;56:377–83.
- [17] Merzdorf CS, Sive HL. The ZIC1 gene is an activator of Wnt signaling. *Int J Dev Biol* 2006;50:611–7.
- [18] Pourebrahim R, Van Dam K, Bauters M, et al. ZIC1 gene expression is controlled by DNA and histone methylation in mesenchymal proliferations. *FEBS Lett* 2007;581:5122–6.
- [19] Montgomery E, Lee JH, Abraham SC, Wu TT. Superficial fibromatosis are genetically distinct from deep fibromatoses. *Mod Pathol* 2001;14:695–701.
- [20] Carlson JW, Fletcher CD. Immunohistochemistry for beta catenin in the differential diagnosis of spindle cell lesions: analysis of a series and review of the literature. *Histopathology* 2007;51:509–14.
- [21] Ishiguro A, Inoue T, Mikoshiba K, Aruga J. Molecular properties of Zic4 and Zic5 proteins: functional diversity within Zic family. *Biochem Biophys Res Commun* 2004;324:302–7.
- [22] Taipale J, Beachy PA. The hedgehog and Wnt signaling pathways in cancer. *Nature* 2001;411:349–54.
- [23] Van den Brink GR, Hardwick JC. Hedgehog Wnteraction in colorectal cancer. *Gut* 2006;55:912–4.
- [24] Mizugishi K, Aruga J, Nakata K, Mikoshiba K. Molecular properties of zic proteins as transcriptional regulators and their relationship to GLI proteins. *J Biol Chem* 2001;276:2180–8.
- [25] Seyhan H, Kopp J, Schultze Mosgau S, Horch RE. Increased metabolic activity of fibroblasts derived from cords compared with nodule fibroblasts sampling from patients with Dupuytren's contracture. *Plast Reconstr Surg* 2006;117:1248–52.

Copyright of Scandinavian Journal of Plastic & Reconstructive Surgery & Hand Surgery is the property of Taylor & Francis Ltd and its content may not be copied or emailed to multiple sites or posted to a listserv without the copyright holder's express written permission. However, users may print, download, or email articles for individual use.