



ELSEVIER



CASE REPORT

Long-term follow-up of flaps for extensive Dupuytren's and Ledderhose disease in one family

Hester J. Kan*, Steven E.R. Hovius

Department of Plastic and Reconstructive Surgery and Hand Surgery, Erasmus Medical Center Rotterdam, 3000 CA Rotterdam, The Netherlands

Received 12 March 2012; accepted 30 April 2012

KEYWORDS

Dupuytren's diathesis;
Recurrence;
Ledderhose disease;
Surgical treatment;
Reversed upper radial forearm flap;
Free flap

Summary Dupuytren's and Ledderhose disease can be a cumbersome condition in patients with a severe diathesis with a very early onset. Two brothers are described with a reversed radial forearm flap on both hands and two upper lateral arm flaps on both feet with a long-term follow-up ranging from 14 to 25 years. They had multiple procedures of both hands before the flaps were considered.

No recurrence occurred under the flap. In very severe diathesis flaps should be considered in an earlier phase to prevent multiple procedures and early recurrence.

© 2012 British Association of Plastic, Reconstructive and Aesthetic Surgeons. Published by Elsevier Ltd. All rights reserved.

Introduction

Patients with a severe diathesis in Dupuytren's disease (DD) are known to have a poor surgical outcome after long-term follow-up with a recurrence rate of the disease ranging from 12%¹ to 47%² after dermofasciectomy. All depends of course on the definition of recurrence. Furthermore most authors report no recurrent disease under the full thickness graft.^{3,4} In addition, recurrent surgeries lead to high complication rates and social burden. Also the financial implications for society are high.⁵

In the search for less recurrence different kind of free flaps have been described as alternative treatment for severe DD cases.^{6,7} However, no long-term follow-up has been reported following extensive surgery.

The aim of this report is to describe the long-term follow-up in two brothers with a severe diathesis following flap surgery for both hands and feet.

Patients

Case 1

In 1978 a 30-year-old Caucasian male with a history of DD was referred to our hospital. In the following eight years twelve faciectomies combined with full thickness skin grafts (FTG)

* Corresponding author. Tel.: +31 10 70 43291.
E-mail address: h.kan@erasmusmc.nl (H.J. Kan).

were performed on his right hand, left hand and left foot. He is a smoker and consumes 4 units of alcohol per day.

In 1986 the severity of his diathesis and the frequent recurrence of the disease prompted us to perform a reversed radial forearm flap (Rev. RFF), to cover the palm and the proximal phalanges of all fingers of the left hand excluding the thumb (Figure 1).

In 1991 his right hand was also operated with a Rev. RFF. In 1988 and 1996 both feet were operated with a free vascularised upper lateral arm flap (ULAF) following excision of painful large nodules impeding normal gait (Figure 3). Additional surgeries over the years were for an arthrodesis of the PIP joint of the fifth finger due to a painful degenerative arthritis, to resolve the residual syndactylies of both hands

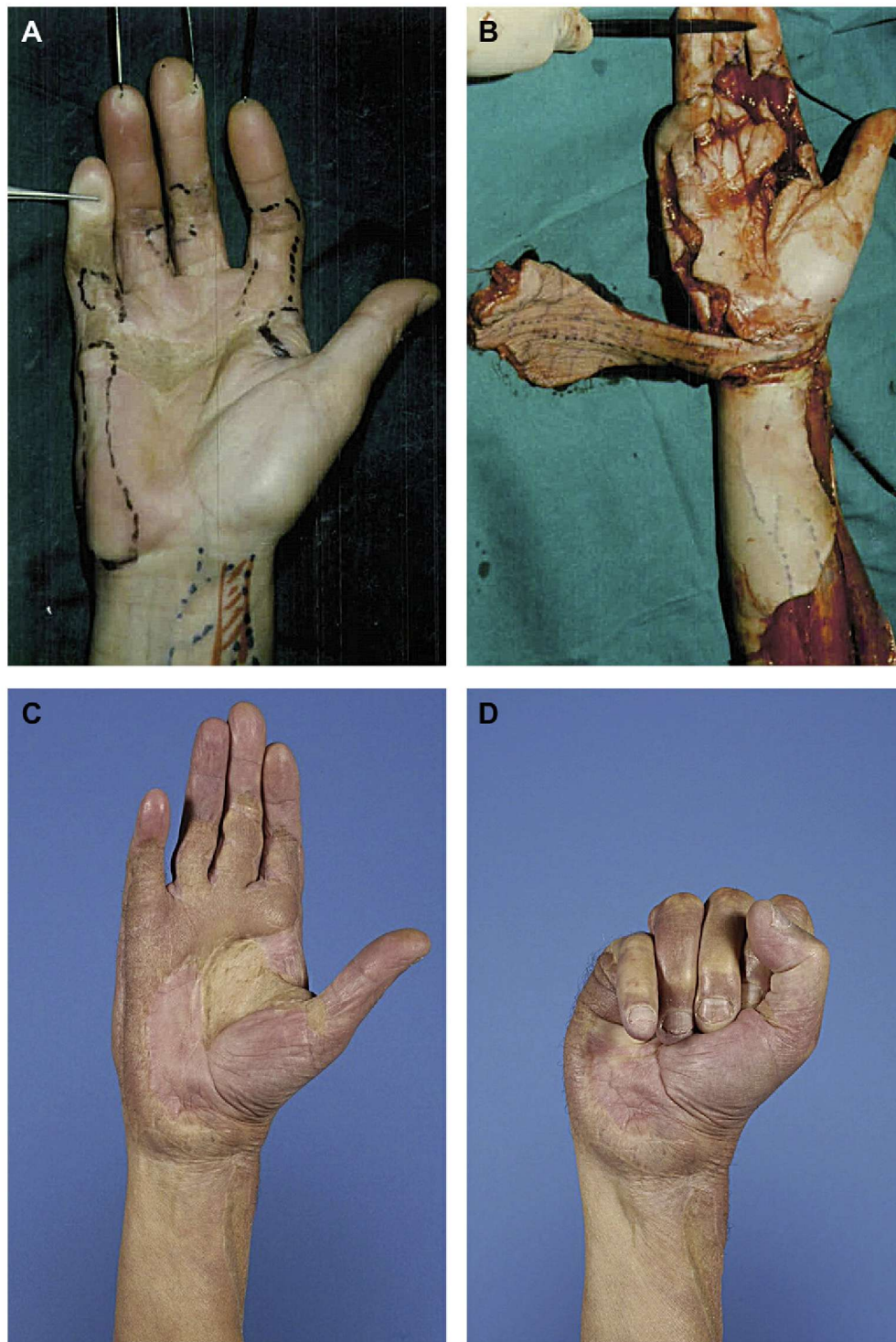

Figure 1 Surgical course of the first patient. This figure shows the preoperative (A) and peroperative (B) photograph of the right hand of our first patient. At that time he was 43 years old. Twenty years after surgery the patient is able to extend the fingers (C) and to make a fist (D).

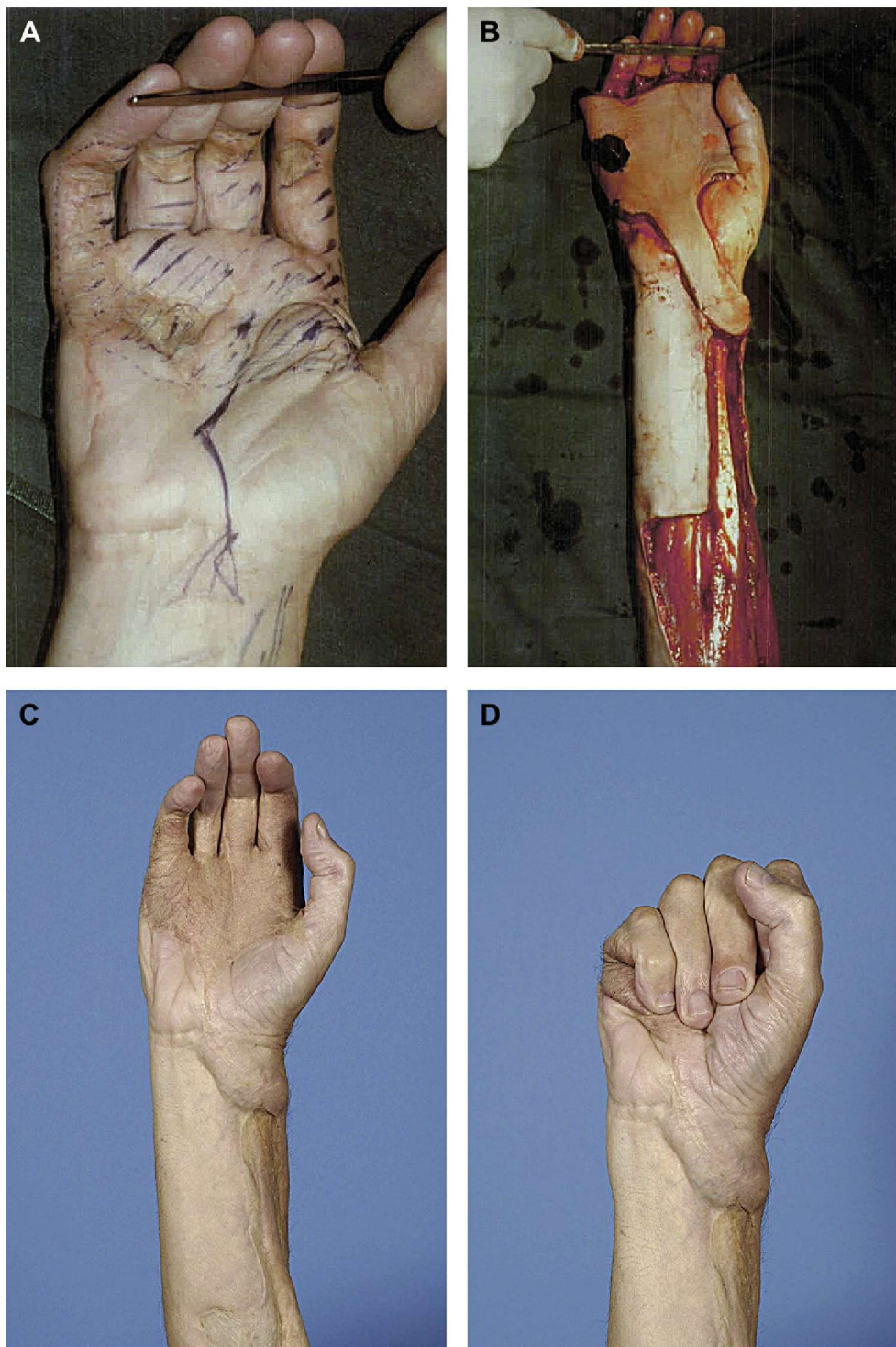


Figure 2 Surgical course of the second patient. This figure shows the preoperative (A) and peroperative (B) photograph of the right hand of our second patient. At that time he was 37 years old. Twenty-five years after surgery the patient is able to extend the fingers (C) and to make a fist (D).

following flap surgery and to bury a pre-existent painful neuroma in the palm of the right hand.

In 2010, 24-years after surgery of the left hand and nearly 20 years after surgery of the right hand, no recurrent DD tissue has been noted under the flaps. The feet, respectively 15 and 22 years postoperatively, have been free of recurrence since the initial free flap.

Case 2

In 1986 a 37-year-old Caucasian male, brother of case one, was operated on both hands by using a Rev. RFF, after an extensive history of recurrent surgeries (over 30 for both hands and 2 for both feet) for DD since 1974 (Figure 2). He consumed 5–8 units of alcohol per day and has no history of

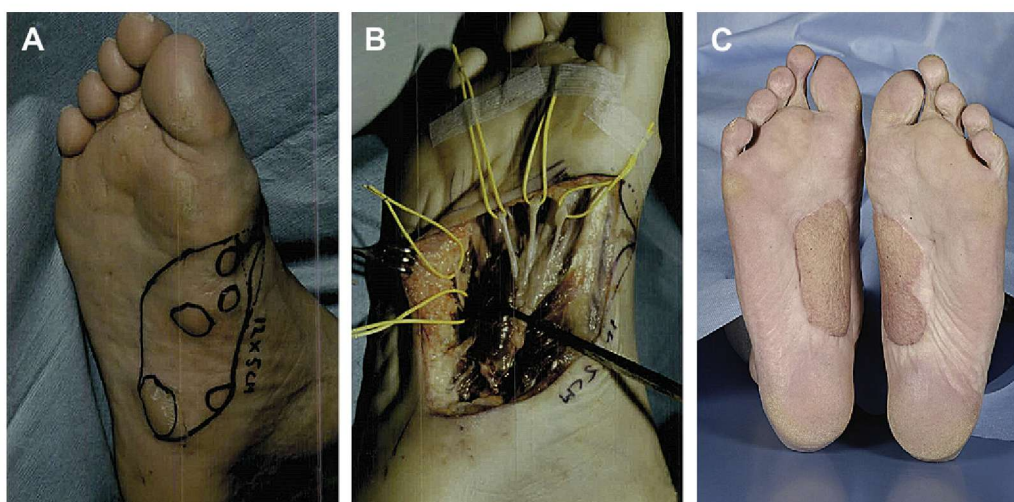


Figure 3 Surgical course of the feet of both patients. Not all photographs were available. Therefore we can only show preoperative (A) and peroperative (B) photographs of the second patient and the 22-year follow-up photograph (C) of the first patient.

smoking. The residual syndactylies of both hands following flap surgery were resolved in 1988 and in 1990.

Between 1986 and 1990 two fasciectomy with FTG were performed on the first web space of his left hand and on his right foot outside the area of the flap. Arthrodesis of his DIP joint from his fifth finger of his left hand was performed in 1994, due to a painful hyperextension.

The right foot was operated with a free vascularised ULAF in 1997, with a complicated postoperative recovery due to systemic co-morbidity, i.e. heart failure and jaundice. The flap survived. The left foot was therefore not operated (Figure 3).

After 25 years, the patient had no recurrence of DD tissue under the Rev. RFF, but he did suffer from extensions at the sides of the flaps. Fourteen years postoperative the right foot has been free of recurrence since the initial free flap. He still suffers from painful noduli in his left foot.

Methods

In both patients extensive measurements were performed during regular follow-up. The passive range of motion (ROM), grip strength (Jamar), and sensibility (Semmes and Weinstein monofilaments) were measured. Furthermore the Disability for Arm Shoulder and Hand (DASH), Cold

Intolerance Scale (CISS), VAS pain scale and a satisfaction questionnaire were completed by both patients.

Results

Both patients cannot fully extend the fingers. Flexion is possible except the small finger of the right hand of the first patient and the small finger of the left hand of the second patient (Table 1 and Figures 1 and 2). Grip strength was diminished with on average 10 kg compared to their age group (C1: 26.02 kg right hand; 26.65 kg left hand and C2: 32.22 kg right hand; 32.06 kg left hand).⁸

The first patient reports pain only when using his hands (VAS score 5 to 7.9 out of 10). This pain is especially in his right hand. The second patient had no pain in his right hand, but does suffer from a constant pain of 2.2 out of 10 in his left hand. During daily activity this pain rises to 4.6 out of 10. The feet were not painful, except the left foot of the second patient who was not operated. Both brothers scored above 30 points on the CISS and the DASH score was 36 out of 100 for the first and 25 out of 100 for the second patient. They experience some difficulties in daily activity, but overall they are very satisfied with the outcome of the surgery (8.4 out of 10 and 8.7 out of 10 VAS scale) and would

Table 1 Passive goniometric results of both patients. This table shows the passive extension and passive flexion of the fingers of both hands of both patients. Both patients can extend and flex the fingers. Our second patient received an arthrodesis for his PIP5 of the left hand.

	Digit:	Case 1					Case 2				
		1	2	3	4	5	1	2	3	4	5
		Extension/Flexion					Extension/Flexion				
Right hand	MCP	0°/38°	-17°/90°	0°/53°	-18°/74°	-5°/70°	-3°/37°	6°/102°	-10°/96°	-11°/90°	-13°/94°
	PIP	-18°/54°	34°/99°	10°/97°	5°/94°	45°/45°	-12°/71°	40°/98°	13°/100°	6°/84°	20°/86°
	DIP		-23°/47°	-20°/31°	-5°/43°	-12°/10°		-1°/54°	0°/0°	-15°/4°	20°/38°
Left hand	MCP	-12°/42°	-18°/78°	-13°/90°	-10°/88°	-13°/87°	-5°/48°	2°/86°	8°/87°	45°/97°	30°/88°
	PIP	-12°/47°	5°/90°	4°/90°	32°/102°	17°/90°	-25°/56°	25°/83°	23°/86°	26°/64°	28°/36°
	DIP		-27°/38°	-10°/22°	-14°/10°	-7°/32°		3°/32°	-17°/24°	5°/7°	45°/45°

not hesitate to do it again. They advised to perform the surgery earlier in the course of the disease.

Discussion

Two patients with a severe diathesis of Dupuytren's Disease (DD) are described, in which reversed radial forearm flaps (Rev. RFF) were used for both hands and free vascularised upper lateral arm flaps for the feet, as an ultimate treatment solution after multiple procedures. Their hand function is acceptable and the patients are very satisfied with the overall results following the flap surgery in both hands and feet. No recurrence developed under the flap since the use of the flaps and patient burden was reduced extensively. It should be noted that these patients have been operated multiple times and therefore demonstrate pain, cold intolerance and disability regardless of the use of flaps. The pain already existed prior to flap surgery. In the first patient a neuroma was buried in the palm of the right hand.

Skin grafts have been reported to act as a local 'fire-break' to prevent recurrence. Extensive dermofasciectomy with FTG is therefore treatment of choice for patients with a severe diathesis.^{9,10} However, the recurrence rate of dermofasciectomy, after mean follow-up of 13 years, is reported to be up to 47%.² Dermofasciectomy compared with fasciectomy even show the same recurrence rates of 12% after 36 months.¹

In studies using free vascular flaps for soft tissue coverage after palm and digit defects in two DD patients are mentioned, although survival of the flap and not recurrence of DD was the outcome.^{6,11} However, the circumflex scapular artery perforator flap has been described with good clinical outcome in one patient with a one-year- follow-up.⁷

Any large flap is an aggressive but alternative treatment for patients with severe DD, we used the Rev. RFF for this purpose. In very severe diathesis of DD's with an early onset (3rd to 4th decade) we offer this kind of extensive surgery to these patients. Nearly all patients decline this type of surgery, however in a very early stage. Only after multiple corrections the need for a different treatment is recognised. We have performed four more flaps to the hand for

severe diathesis but with far less long-term follow-up when compared to the patients described. All these patients have not demonstrated recurrence under the flap until now. To reduce the patient burden and to lower costs it can be a good option to consider large flaps covering the palm of the hand and proximal fingers earlier.

References

1. Ullah AS, Dias JJ, Bhowal B. Does a 'firebreak' full-thickness skin graft prevent recurrence after surgery for Dupuytren's contracture?: a prospective, randomised trial. *J Bone Jt Surg Br* 2009 Mar;**91**(3):374–8.
2. Kelly C, Varian J. Dermofasciectomy: a long term review. *Ann Chir Main Memb Super* 1992;**11**(5):381–2.
3. Brotherton TM, Balakrishnan C, Milner RH, Brown HG. Long term follow-up of dermofasciectomy for Dupuytren's contracture. *Br J of Pltic Sery* 1994;**47**(6):440–3.
4. Ketchum LD, Hixson FP. Dermofasciectomy and full-thickness grafts in the treatment of Dupuytren's contracture. *Trnal of Hand Surgery* 1987;**12**(5 Pt 1):659–64.
5. Maravic M, Landais P. Dupuytren's disease in France—1831 to 2001—from description to economic burden. *J Hand Surg [Br]* 2005 Oct;**30**(5):484–7.
6. Brandt K, Khouri RK, Upton J. Free flaps as flow-through vascular conduits for simultaneous coverage and revascularization of the hand or digit. *Plast Reconstr Surg* 1996 Aug;**98**(2):321–7.
7. Branford OA, Davis M, Schreuder F. The circumflex scapular artery perforator flap for palm reconstruction in a recurrent severe case of Dupuytren's disease. *J Plast Reconstr Aesthet Surg* 2009 Dec;**62**(12):e589–91.
8. Werle S, Goldhahn J, Drerup S, Simmen BR, Sprott H, Herren DB. Age- and Gender-Specific Normative Data of grip and Pinch strength in a Healthy adult Swiss Population. *J Hand Surg Eur Vol* 2009 Mar 12.
9. Tubiana R. *Dupuytren's disease*. London: Martin Dunitz; 2000.
10. Hindocha S, Stanley JK, Watson S, Bayat A. Dupuytren's diathesis revisited: Evaluation of prognostic indicators for risk of disease recurrence. *J Hand Surg Am* 2006 Dec;**31**(10):1626–34.
11. Kuntscher MV, Erdmann D, Homann HH, Steinau HU, Levin SL, Germann G. The concept of fillet flaps: classification, indications, and analysis of their clinical value. *Plast Reconstr Surg* 2001 Sep 15;**108**(4):885–96.