



ELSEVIER



## CASE REPORT

# Surgical treatment of a case of congenital Dupuytren's disease

Huai Yuan Zheng, Juan Liu\*

Department of Hand Surgery, Union Hospital, Huazhong University of Science and Technology, No. 1277 Jiefang Avenue, Wuhan 430022, People's Republic of China

Received 13 July 2012; accepted 15 November 2012

**KEYWORDS**

Dupuytren's disease;  
Paediatric;  
Hand;  
Fasciectomy

**Summary** Dupuytren's disease in infants has been rarely reported. We present a congenital case with the onset of the disorder since his birth. A 31-month-old boy with congenital flexion contracture of his left long and ring finger was suspected to the diagnosis. To correct the deformity and confirm the diagnosis, fasciectomy was performed. Postoperative histopathological examination proved the diagnosis. No recurrence and functional disturbance of the hand were observed at 21 months' follow-up.

© 2012 British Association of Plastic, Reconstructive and Aesthetic Surgeons. Published by Elsevier Ltd. All rights reserved.

Dupuytren's disease is generally considered to be a disease that occurs in adulthood, which is rarely reported in children. To date, there are only 13 cases of Dupuytren's disease documented in the English literature in children <13 years and only seven cases histologically diagnosed in those under 10 years.<sup>1–5</sup> Only two cases of Dupuytren's disease occurring in infants have been reported. One is a 10-month-old boy with a flexion deformity of the distal interphalangeal joint of the long finger.<sup>1</sup> The other is a 6-month-old boy with a palpable palmar plaque and flexion contracture of the ring finger.<sup>2</sup> Due to a progressive contracture of the finger and increasing palmar mass, both

the infants received fasciectomy and postoperative histology confirmed the diagnosis of Dupuytren's disease. We report a case of histologically proven Dupuytren's in a 31-month-old boy with the onset of the disorder since his birth.

## Case report

A 31-month-old boy was referred to our department with flexion contracture of both the long finger and the ring finger of his left hand. The contracture existed since his birth. There was no family history of Dupuytren's disease or other congenital deformities. Physical examination revealed a palpable plaque of tissue deep to the skin with a cord extending to the opposite side of proximal phalanx of the long and ring fingers. A deepening single transverse

\* Corresponding author.

E-mail address: liujuan\_1018@126.com (J. Liu).

palmar crease was observed. Both the two fingers could not be passively extended to a straight position and the ring finger showed more severe flexion contracture (Figure 1). The features were similar to Dupuytren's in an adult and the diagnosis was suspected. Due to poor co-operation of conservative treatment with this child, an operation of fasciotomy was indicated.

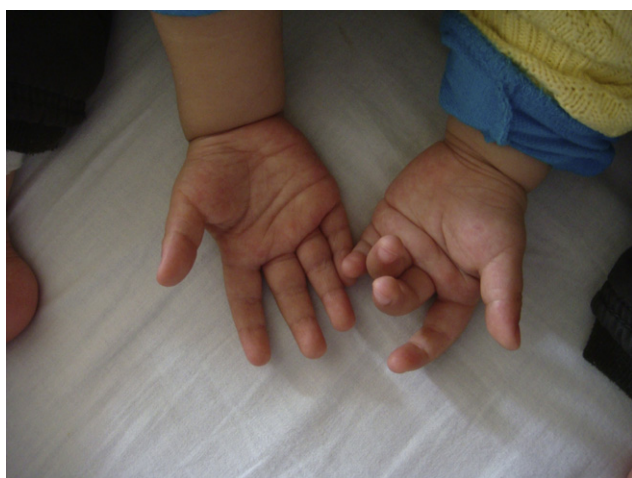A Bruner incision and 'Z' plasty were designed in the palm, extending into the proximal phalanx of the long and the ring finger. The fibrotic mass was excised. It did not involve the digital nerves or the vessels, but appeared to involve the flexor tendon sheath from the PA pulley to the A2. An unusual tendinous band originated from the midpalm and inserted at the proximal phalanx was observed and restricted the extension (Figure 2). It was excised together with the mass. After the release, the long finger and the ring finger could be passively extended to the straight position.

Histological findings showed a marked increase of fibrous tissue with fibroblasts encircling fat lobules and nervous branches. The lesion had diffusely infiltrated the fibrofatty and muscular tissue (Figure 4). It showed no evidence of granulomatous tissue or foreign-body encapsulation. There were no mitoses in the fibroblasts or intracytoplasmic inclusions as seen in digital infantile fibromatosis. The features were consistent with Dupuytren's fibromatosis. The histology of the specimen was reviewed by an independent histologist and was typical of Dupuytren's disease.

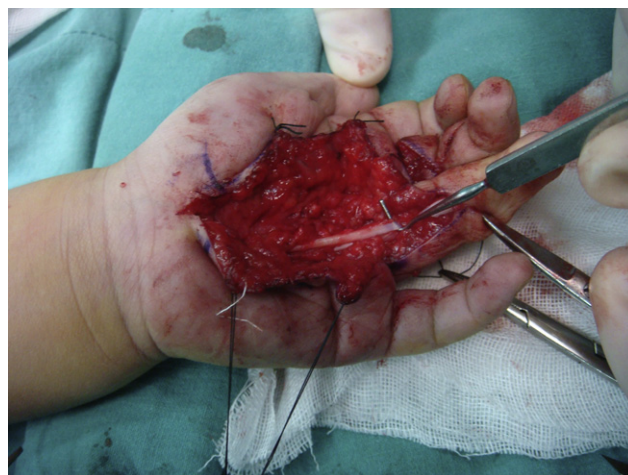There were no perioperative complications. At 21 months' follow-up, the child had no functional disturbance of the hand. There was no recurrence and full range of motion was present, but abduction of the ring finger was partially limited (Figure 3).

## Discussion

Dupuytren's disease in infants is exceedingly rare. Only six cases of histologically proven Dupuytren's disease have been reported worldwide in children under 10 years of age,



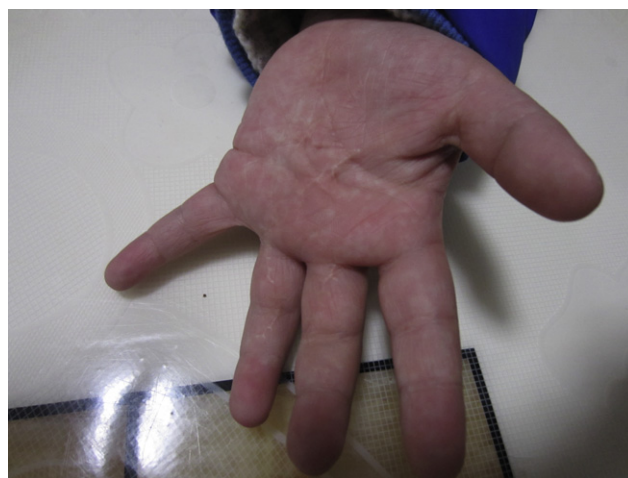**Figure 1** Preoperative manifestation. Flexion contracture of the left long and ring fingers. A deepening single transverse palmar crease was observed.



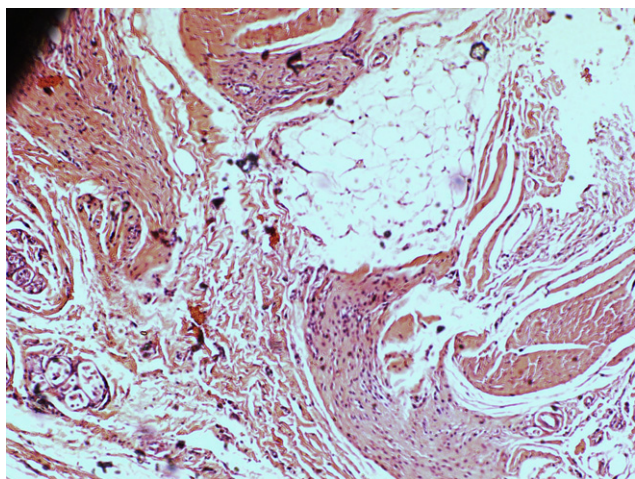
**Figure 2** Intraoperative findings. The fibrotic mass and unusual tendinous band were excised.

including two infants aged 6 and 10 months.<sup>3</sup> The reasons for operating in our case were not only to correct the contracture deformity but also to exclude malignancy. Rhomberg et al. reported a 9-year-old boy who was diagnosed initially as Dupuytren's disease but finally was confirmed to be an epithelioid sarcoma.<sup>4</sup> Despite the infiltrative nature of the tissue plaque the pathologist was certain of the histological diagnosis of Dupuytren's. A diagnosis of Dupuytren's disease should not be made without histology.

The aetiology of Dupuytren's disease is multifactorial and the two infants' involvement suggests a genetic causation. Some of the common causes of childhood finger flexion contracture include camptodactyly, congenital ulnar drift, burns, extra-abdominal fibromatosis, infantile digital fibromatosis (recurring digital fibroma of childhood), epithelioid sarcoma, juvenile aponeurotic sarcoma, infantile fibrosarcoma, giant cell tumour of tendon sheath (localised nodular tenosynovitis), fibrous hamartoma of infancy and infantile myofibromatosis.<sup>2,4,5</sup> Infantile digital



**Figure 3** 21 months' follow-up showed no functional disturbance.



**Figure 4** Histological microscopic observation of the mass showing increase of fibrous tissue with proliferative fibroblasts encircling fat lobules. (hematoxylin and eosin stain,  $\times 100$ ).

fibromatosis typically presents in the first year of life as a single, firm, pink or red nodule on the dorsum of the fingers or toes. These nodules have the characteristic histological appearance of eosinophilic inclusion bodies in the cell cytoplasm.<sup>6</sup>

The management of Dupuytren's disease has been challenging because of its high recurrence rate. However, the risk of recurrence of disease in a paediatric age group and the optimal timing for surgery of this rare condition are still uncertain.<sup>1</sup> It has been suggested that aggressive dermofasciectomy should be performed. Urban et al. described a 9-year-old boy who was treated initially by fasciectomy but required a dermofasciectomy 19 months later for recurrence.<sup>5</sup> The two reported infantile cases

were treated by fasciectomy and no recurrence was observed with 21 and 27 months' follow-up. Foucher et al. recommended that fasciectomy was sufficient unless there was any evidence of skin involvement to warrant dermofasciectomy.<sup>1</sup> In our case, simple excision of diseased fascia results in complete release of the contracture and no recurrence was noted. Partial abduction loss of the ring finger may be caused by poor co-operation of rehabilitative procedure.

### Financial disclosure

None of authors has a financial interest in any of the products, devices or drugs mentioned in this article.

### Conflict of interest statement

None.

### References

1. Foucher G, Lequeux C, Medina J, Garcia RN, Nagel D. A congenital hand deformity: Dupuytren's disease. *J Hand Surg Am* 2001 May; **26**(3):515–7.
2. Bebbington A, Savage R. Dupuytren's disease in an infant. *J Bone Jt Surg Br* 2005 Jan; **87**(1):111–3.
3. Usmar S, Peat B. Paediatric Dupuytren's disease. *ANZ J Surg* 2010 Apr; **80**(4):298–9.
4. Rhomberg M, Rainer C, Gardetto A, Piza-Katzer H. Dupuytren's disease in children – differential diagnosis. *J Paediatr Surg* 2002; **37**:E7.
5. Urban M, Feldberg L, Janseen A, Elliot D. Dupuytren's disease in children. *J Hand Surg (Br)* 1996; **21B**:112–6.
6. Spingardi O, Zoccolan A, Venturino E. Infantile digital fibromatosis: our experience and long-term results. *Chir Main* 2011 Feb; **30**(1):62–5.