

# The Rationale for Treating the Nodule in Dupuytren's Disease

Lynn D. Ketchum, MD

**Background:** Dupuytren's disease encompasses a spectrum of fibroblastic disorders from the presence of 1–2 nodules in the palm of a hand with no joint contracture to grotesque, crippling and disabling deformities of hands. Over the last 50 years, many enlightening studies have been forthcoming, which, through techniques of histopathology, biochemistry, tissue culture, and electron microscopy, have shed pearls of light on various aspects of the disease process.

**Methods:** A comprehensive review of the literature on Dupuytren's disease was undertaken, stringing together results from numerous studies to establish a table of events and their location in the development of the disease.

**Results:** What will be seen is a credible scenario of events which will enable the clinician to be more proactive in the earlier treatment of the disease and more aware of factors that increase or decrease recurrence rates postoperatively.

**Conclusions:** The most effective management of Dupuytren's disease is early recognition and treatment of the nodule, before the development of a joint contracture, particularly of a proximal interphalangeal joint. As there is evidence of a significant inflammatory role in the development of the nodule, the process of fibroplasia can be minimized by altering the macrophage > fibroblast > collagen cascade by the intralesional injection of a potent anti-inflammatory agent such as triamcinolone, which also blocks tissue inhibitors of collagenase, thus enhancing the action of native collagenase, and reduces the size and firmness of nodules and, at least temporarily, arrests their progression. (*Plast Reconstr Surg Glob Open* 2014;2:e278; doi: 10.1097/GOX.0000000000000249; Published online 23 December 2014.)

Dupuytren's disease encompasses a spectrum of fibroblastic disorders in the hands and feet (rarely in the penis) that range from a

single nodule in the palm of a hand to a progressive mass of nodules and cords that coalesce with normal structures, and through the process of contracture, produce crippling deformities.

The process always begins with a nodule, which is the engine of the disease. Over the last 50 years, there has been a chain of studies concerning Dupuytren's disease that have shed light on what is transpiring in the development of the nodule. In 2006, Al-Qattan<sup>1</sup> published a review of factors in the pathogenesis of Dupuytren's disease. The article, an extension and amplification of those concepts, has as its goal the focus on the initial events and their location in the development of the disease, highlighting factors that will allow the clinician to be more proactive in the

*From the Department of Plastic Surgery, University of Kansas Medical Center, Kansas City, Kans.*

*Received for publication July 9, 2014; accepted November 6, 2014.*

*Presented, in part, at the Symposium on Dupuytren's Disease, Stony Brook Medical Center, Stony Brook, N.Y., March, 2012.*

*Copyright © 2014 The Authors. Published by Lippincott Williams & Wilkins on behalf of The American Society of Plastic Surgeons. PRS Global Open is a publication of the American Society of Plastic Surgeons. This is an open-access article distributed under the terms of the Creative Commons Attribution-NonCommercial-NoDerivatives 3.0 License, where it is permissible to download and share the work provided it is properly cited. The work cannot be changed in any way or used commercially.*

DOI: 10.1097/GOX.0000000000000249

**Disclosure:** *The author has no financial interest to declare in relation to the content of this article. The Article Processing Charge was paid for by the author.*

early treatment of Dupuytren's disease and provide a rationale for the treatment of the nodule, as well as to improve recurrence rates, postoperatively.

The article represents the author's interpretation of the results of the studies to be presented and is influenced by his personal experience of 48 years with wound healing and the management of patients with Dupuytren's disease with intralesional injections of nodules with triamcinolone and with expanded dermofasciectomy and full-thickness grafts for patients with extensive and significant contractures.

### DEVELOPMENT OF THE NODULE

As Luck<sup>2</sup> pointed out over 50 years ago, from its inception, a nodule of Dupuytren's disease undergoes 3 stages of development; in the first stage (the proliferative stage), the nodule is densely hypercellular with little collagen and with most of the cells being myofibroblasts.

Next, in the involutinal or contractile phase, the cells are smaller and rounder, and there is an abundance of collagen, particularly the immature type III collagen, and contraction of the nodule/cord complex is occurring (Fig. 1). In the third stage (the residual stage), the nodule is hypocellular with the cells appearing mature, senescent, and almost deplete of peripheral bundles of microfilaments containing  $\alpha$ -smooth muscle actin.<sup>2</sup>

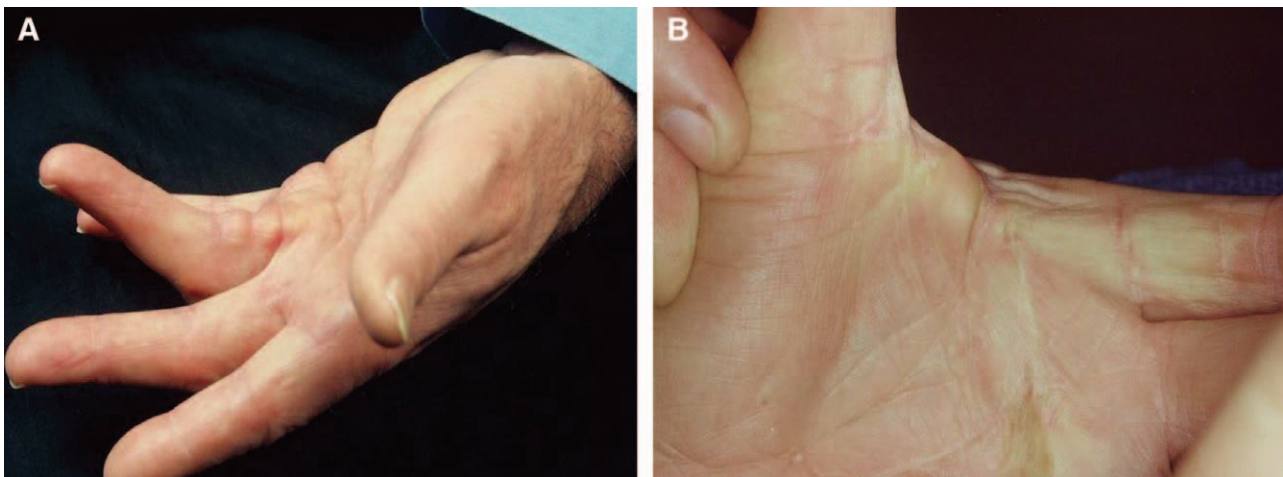
The process begins with the embryonic nodule. Whether the nodule originates in the dermis of the skin,<sup>3-5</sup> in the subcutaneous tissue, or on the ventral side of the palmar aponeurosis, Murrell<sup>6</sup> found that fibroblasts begin proliferating around microvessels that are thicker with narrower lumens and in various states of occlusion when compared with control palmar tissues. This finding, so common in the palmar skin and

subcutaneous tissue of hands involved with Dupuytren's disease, was also found by Vracko<sup>7</sup> in the hands of patients with diabetes mellitus. This microangiopathy produces mild ischemia in these tissues. Hands of older patients and smokers have similar findings, and it has been shown that their fibroblasts have fewer antioxidants.<sup>6</sup> To initiate this process, something is activating the DNA for Dupuytren's disease. Although it is conjecture at this point, theoretically this hypoxia credibly acts as a common pathway for the gene(s) for Dupuytren's disease to be activated or its expression enhanced.<sup>8</sup> Patients with a positive family history have a genetic predisposition to Dupuytren's disease, so that set of genes is more readily activated or enhanced.

### TRANSENDOTHELIAL MIGRATION IN PATHOLOGICAL VESSELS

Once the gene for Dupuytren's disease has been activated, what is seen in and around those pathological vessels is a transendothelial migration of macrophages and T lymphocytes. This has been demonstrated by Meek et al<sup>9</sup> who could also prevent that transepithelial migration by the intralesional injection of steroids. This is important because blocking the migration of macrophages stops the macrophage cascade of macrophages > fibroblasts > collagen and arrests or diminishes the process of fibroplasia.

Macrophages and T lymphocytes produce cytokines and growth factors, especially the cytokine interleukin-1, and the transforming growth factor- $\beta$ 1 (TGF- $\beta$ 1), which are found in and around the pathological vessels in the embryonic nodule or at the periphery of the growing nodule and produce a cauldron of subcellular biochemical reactions, beginning with the dephosphorylation of adenosine tri-phosphate as shown by Badalamente and Hurst.<sup>10</sup>



**Fig. 1.** A, The contractual phase of Dupuytren's contracture, with nodules at the metacarpal-interphalangeal joint and proximal phalanx, producing a contracture of the fourth digit proximal inter-phalangeal joint. B, Nodule in the natatory ligament, producing a contracture of the web space.

## RELEASE OF FREE RADICALS

Hypoxanthine is produced by this process, and xanthine dehydrogenase is converted to xanthine oxygenase, which catalyzes hypoxanthine into xanthine and uric acid with the release of superoxide and hydroxyl free radicals (Fig. 2). In vitro, free radicals are unstable and toxic. Murrell<sup>6</sup> have shown that free radicals in lower concentrations stimulate a 6-fold increase in fibroblast production in cords, but they produce a 40-fold increase of fibroblast production in nodules. They also showed that as the density of fibroblasts increases, so does the production of collagen type III.<sup>1,6</sup> Fibroblast production was inhibited when free-radical scavengers were added to the culture system. Endothelial xanthine-oxidase-derived free radicals can damage the stroma of microvessels and stimulate fibroblast proliferation.<sup>9</sup>

Free radicals and inflammatory cells also stimulate the release of cytokines, particularly interleukin-1, which was shown by Baird et al<sup>11</sup> to be the most abundant cytokine in Dupuytren's tissue.<sup>10</sup>

## CYTOKINES

Cytokines act as signals between cells to mediate the cellular response to injury and inflammation.<sup>1</sup> Cytokines also directly stimulate fibroblast proliferation, stimulate macrophages and platelets to produce growth factors, and incite the migration of Langerhans epidermal dendritic cells from the strata spinosum and basale to the epidermal/dermal junction where they incite an immune reaction with the influx of macrophages and T lymphocytes, which also produce growth factors, especially TGF- $\beta$ 1 (Fig. 3A) as described by Al-Qattan.<sup>1</sup>

## GROWTH FACTORS

TGF- $\beta$ 1 is the main agent involved in differentiating fibroblasts into myofibroblasts, and, along with

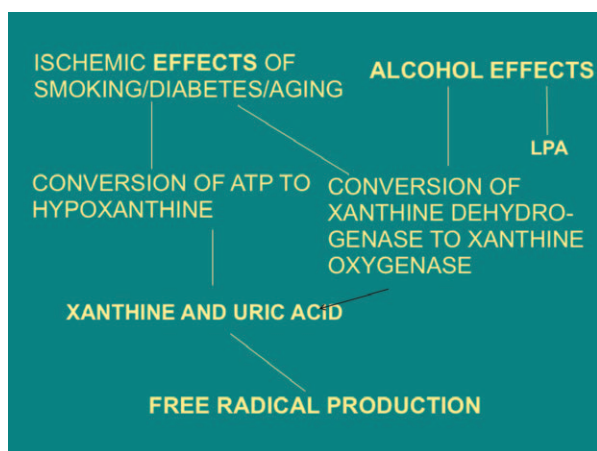


Fig. 2. Effects of ischemia and alcohol on free-radical production.

mechanical stress, contributes to the contraction of the myofibroblast and the nodule/cord complex.<sup>1,12,13</sup> TGF- $\beta$ 1 is a very potent recruiter of inflammatory cells and promotes their survival by delaying or prolonging their programmed cell death, that is, apoptosis, which is one of the reasons for the sustained growth of the nodule. TGF- $\beta$ 1 also plays an important role in increasing the synthesis of the components of the extracellular matrix, such as integrin, and in promoting cell adhesion and stimulating further release of cytokines, thus refueling the cycle<sup>10</sup> (Fig. 3B).

## LYSOPHOSPHATIDIC ACID


TGF- $\beta$ 1 activates platelets to release lysophosphatidic acid (LPA), the most potent agonist in producing myofibroblast contraction. LPA does this by binding to a receptor on the myofibroblast and initiating a reaction that increases intracellular  $\text{Ca}^{++}$  and decreases cyclic AMP, and it leads to the activation and contraction of the actin-myosin complex by the combining of the increased intracellular  $\text{Ca}^{++}$  with calmodulin. This process activates myosin light chain kinase that catalyses the actin-myosin reaction<sup>14</sup> (Fig. 3).

## MYOFIBROBLASTS

Fibroblasts, when stimulated by TGF- $\beta$ 1, develop the following distinguishing features of myofibroblasts, as demonstrated by Gabbiani and Majno.<sup>15,16</sup>

1. Large accordion-like indentations of the nucleus, suggestive of contraction.
2. Large bundles of microfilament fibrils, which stain positive for  $\alpha$ -smooth muscle actin (not small bundles seen in normal fibroblasts) and which are located near the cell membrane.
3. A structure called the fibronexus (located at the cell membrane) is composed of glycoprotein receptors known as integrins. The fibronexus mediates attachment between a cell and its surrounding tissue, which may be another cell or the extracellular matrix, that is, fibrin and fibronectin which, in turn, attach to collagen fibrils.

Fibronectins, also composed of glycoproteins, are derived from fibroblasts, platelets, and keratinocytes and act as a matrix for the attachment of migrating inflammatory cells; in so doing, fibronectins tend to delay cell apoptosis. Fibronectins also act as a scaffold for collagen deposition. Fibronectins have chemotactic ability to attract macrophages and fibroblasts. Meek et al<sup>9</sup> and Tomasek et al<sup>13</sup> have demonstrated abundant levels of fibronectin in Dupuytren-diseased tissue.<sup>10</sup>



**Fig. 3.** The effects of free radicals, cytokines, growth factors, and LPA on fibroplasia and myofibroblast contraction. AMP indicates adenosine mono-phosphate; EGF, epithelial growth factor; IL, interleukin; PDGF, platelet derived growth factor.

### COLLAGENASE INHIBITORS

The quantity of collagen in the nodules and cords of Dupuytren’s disease is significantly affected by an increased presence of tissue inhibitors of matrix metalloproteinases (TIMP) (collagenase). Ulrich et al<sup>17</sup> showed a markedly elevated level of TIMP-1 in the sera and cords of patients with active Dupuytren’s disease. Collagenases (matrix metallo-proteinases) in normal fibrous tissue help maintain a steady-state balance between collagen production and degradation. In Dupuytren’s disease, they are inhibited by TIMPs. Along with fibroblast proliferation, this results in increased amounts of collagen.<sup>17</sup>

With activation and contraction of the actin-myosin complex by LPA, the force of that contraction is transmitted via the fibronexus to fibronectin fibrils, adjacent cells, and collagen fibrils, which flow down the extracellular matrix, using it as a scaffold.

### MECHANISM OF CONTRACTURE

Tomasek et al<sup>13</sup> have shown that the contracture process is of a ratcheting, lock-step nature, in which a

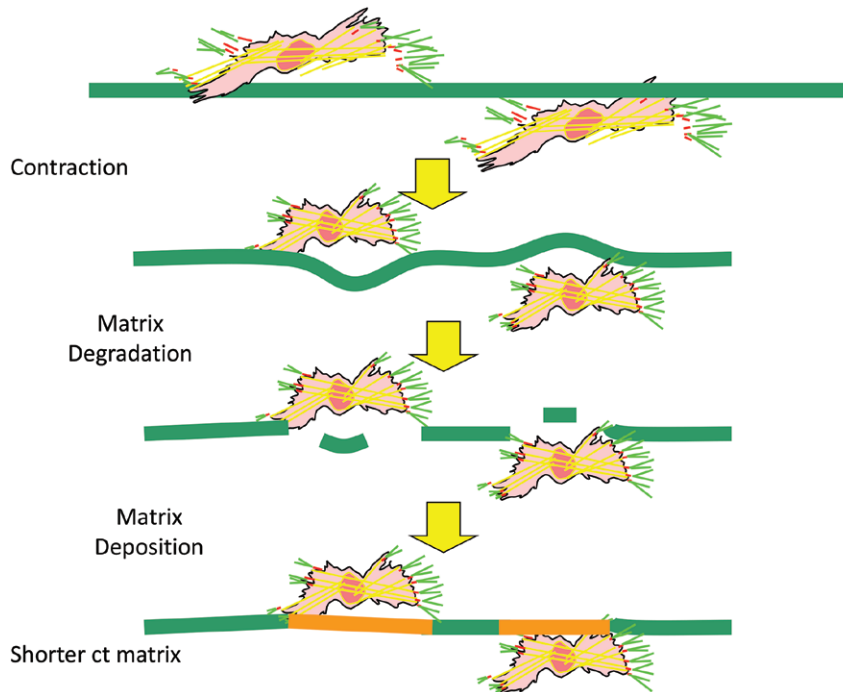
collagenase found in Dupuytren’s disease removes a section of collagen or extracellular matrix after a period of contraction by myofibroblasts. The remaining collagen unites by cross-linking and thus shortens the cord (Fig. 4). The force of contraction generated by myofibroblasts has been measured in granulation tissue. The amount of isometric force generated is approximately 1/10th that generated by smooth muscle<sup>13</sup>; the length of contracture in vitro is approximately 1 cm/mo.

### COALESCENCE AND CONTRACTURE

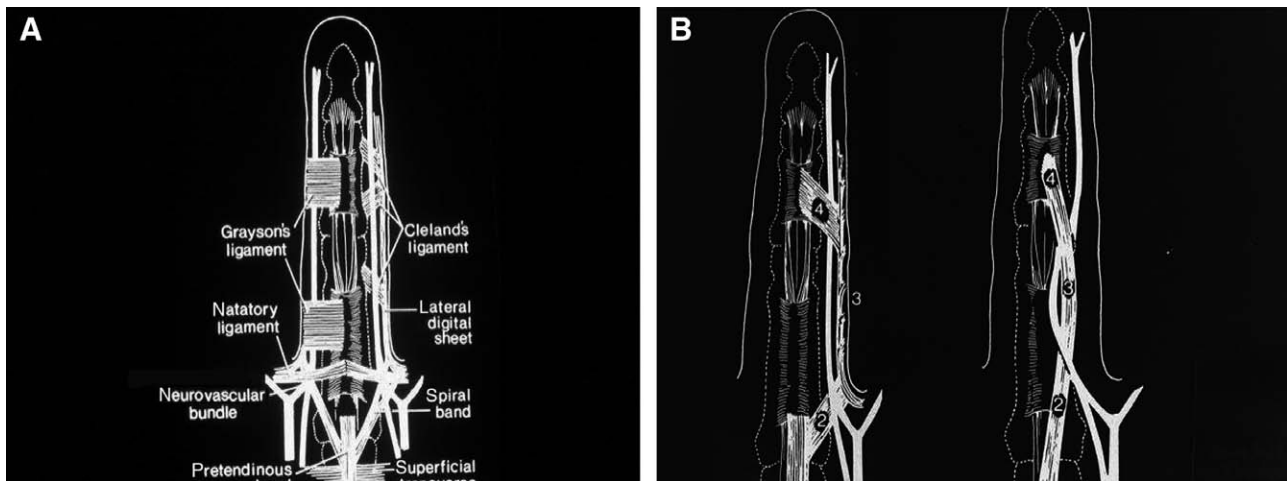
The extracellular matrix, including collagen, attaches and coalesces to normal structures, such as palmar fascia, the bands of Legueu and Juvara, the lateral digital fascia, Grayson’s ligament, the annular pulleys, and other normal structures, which they ultimately deform through the contractile process<sup>18</sup> (Fig. 5).

### WHERE DOES THE PROCESS START?

The origin of the Dupuytren’s disease process is relevant to the outcome of any treatment, which may



**Fig. 4.** Schematic showing the mechanism of contracture in Dupuytren's disease, as proposed by Tomasek et al.<sup>13</sup> After a period of contraction of a myofibroblast, the force of which is transmitted to collagen molecules in the extracellular matrix, a section of a collagen molecule is removed by collagenase found in Dupuytren's diseased tissue; the remaining segments are cross-linked together, shortening the cord and producing contracture.



**Fig. 5.** A, Normal structures in a hand. B, These structures have been coalesced by Dupuytren's disease, contracting a finger, as well as drawing a neurovascular bundle toward the midline. Reprinted with permission from Gosset J. Normal anatomy of the palmodigital aponeurosis. In: Hueston JT, Tubiana R, eds. *Dupuytren's Disease*. 2nd ed. Edinburgh: Churchill Livingstone; 1985:21.

be directed not only at removing diseased tissue, but also at preventing recurrence of the disease. It was previously known by enzymatic assays that type III collagen (which rarely is found in the skin and subcutaneous tissue of normal individuals) was found in abundance in tissue removed from patients with Du-

puytren's disease. However, because the tissue had to be emulsified in performing those assays, the location of the type III collagen could not be accurately determined. The question of origin was decoded when Fitzgerald et al<sup>3</sup> removed sections of skin, subcutaneous tissue, and palmar aponeurosis in patients with

Dupuytren's contracture and stained the tissue with Herovici's picropolychrome stain. This stain differentially marks types I and III collagen. It was determined that the highest concentration of type III collagen was in the papillary layer of the dermis with decreasing amounts in the reticular layer of the dermis, nodules and subcutaneous tissue, and the cords. They showed that nodules stained more like dermis than cords.<sup>3</sup>

McCann et al<sup>5</sup> studied similar sections of diseased Dupuytren's tissue, looking for evidence of actin smooth muscle markers for myofibroblasts, and found that in 12 of 15 samples, the marker for myofibroblasts extended into the dermis of the skin and in 3 cases actually reached the epidermis.

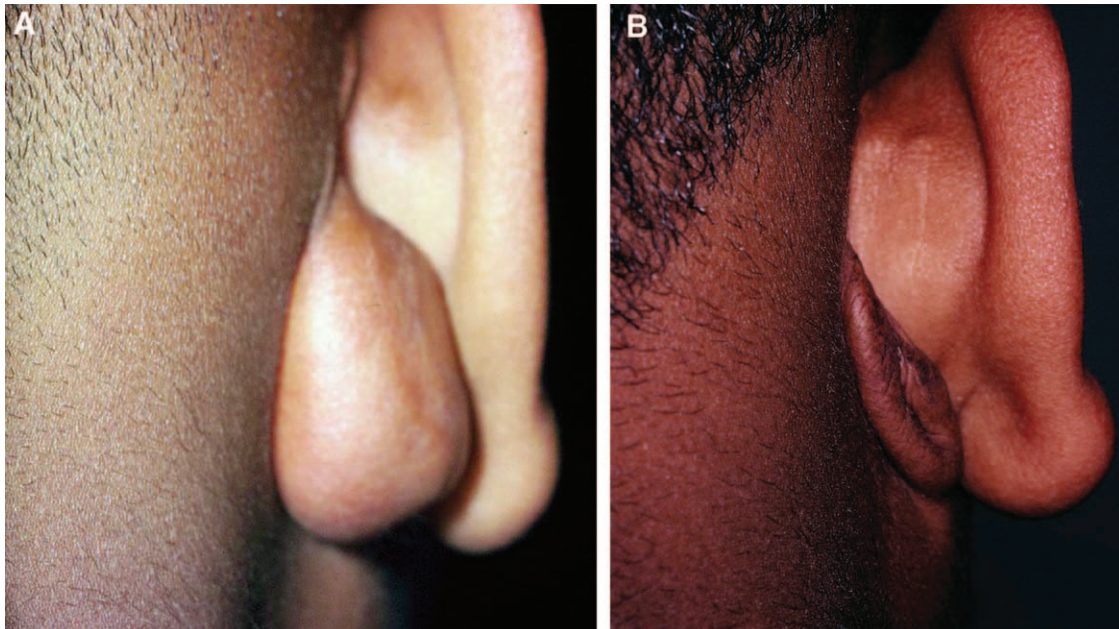
Dupuytren<sup>19</sup> felt that the disease originated in the palmar aponeurosis. It is certainly possible that in some cases it may; it is true that the disease is never seen on the dorsal side of the aponeurosis, only the volar side. If it originated in the palmar aponeurosis, one would expect to see the disease on both volar and dorsal sides of the aponeurosis. It is of interest that if the aponeurosis is removed in the course of a limited fasciectomy, and there is a recurrence of disease requiring reoperation, the disease frequently has the same appearance that it did at the initial operation, even though the fascia had been removed in that area.

An argument for a prominent role of the dermis in the development of the disease is that Hueston<sup>20</sup> found that if diseased dermis was removed along with

fascia and replaced with a skin graft from an area of the body that does not become involved with Dupuytren's disease, recurrent disease is not seen beneath the skin graft. The author has published a series of cases spanning 36 years with an average recurrence rate of 9%, using expanded dermofasciectomy and full-thickness skin grafts.<sup>21</sup> This is in contrast to an average recurrence rate of approximately 50% for limited fasciectomy without dermofasciectomy and skin graft, as determined by Tubiana and Leclercq<sup>21</sup> in a review of multiple studies on limited fasciectomy.<sup>22</sup> These data indicate not only strong evidence for the origin of Dupuytren's disease in many cases to be in the skin and subcutaneous tissue of affected hands, but of equal importance in the treatment of such patients, the necessity of not leaving behind such sources of potential disease that can lead to high rates of recurrence.

### TRIAMCINOLONE

There is strong evidence for an inflammatory role in the etiology of the nodule.<sup>9,23</sup> The nodule of Dupuytren's disease is analogous to a keloid scar, which is an aberrant form of wound healing. Keloids have been shown to be effectively treated by a potent anti-inflammatory agent such as triamcinolone,<sup>24</sup> so it seemed that a natural extension of the use of triamcinolone would be in the intralesional treatment of nodules of Dupuytren's disease (Fig. 6).



**Fig. 6.** A, A postauricular keloid before treatment with triamcinolone. B, The same keloid 6 months after having been treated at 6-week intervals with triamcinolone. The insoluble collagen in the keloid was converted to salt-soluble collagen which was absorbed, leaving an empty sack of skin. Reprinted with permission from Ketchum LD, Smith J, Robinson DW, et al. The treatment of hypertrophic scar, keloid and scar contracture by triamcinolone acetate. *Plast Reconstr Surg.* 1966;38:209–218.

Triamcinolone has beneficial effects in several areas of wound healing: it does not degrade insoluble collagen directly, but when added to collagenase and incubated *in vitro* with insoluble collagen, it doubles the yield of salt-soluble collagen compared with that which was obtained by collagenase alone. This occurs by potentiating the activity of collagenase.<sup>25</sup>

*In vivo*, the triamcinolone injection of rat-tail tendons converts the insoluble collagen there into salt-soluble collagen, which is absorbed and excreted.<sup>25</sup>

Triamcinolone blocks the action of  $\alpha$ -2 macroglobulin, which is a tissue inhibitor of collagenase; this is how triamcinolone enhances the activity of collagenase and increases the degradation of insoluble collagen into salt-soluble collagen. The injection of hydrocortisone into a collagen structure does not yield salt-soluble collagen, but rather, acid-soluble collagen, which is not extracted and excreted, but remains as acid-soluble collagen.<sup>25</sup> This is why hydrocortisone is ineffective in reducing the size and hardness of hypertrophic scars, as well as Dupuytren's nodules. It is the fluoridation of the hydrocortisone molecule at the #9 position that enhances its effectiveness and makes triamcinolone 9- $\alpha$ -flouro-hydrocortisone.

In addition to its effect on collagen, triamcinolone affects the macrophage > fibroblast > collagen cascade in a dose-dependent manner, which is similar to the effect of administering antimacrophage serum.

In both cases, fibroblast and subsequent collagen production are preempted by blocking macrophage production. It has repeatedly been observed that with the administration of a dose of triamcinolone sufficient to produce the effect, one can reopen a wound 3 weeks after wounding and observe the appearance of a wound one would expect to see 60 minutes after wounding. There would be a few neutrophils, but minimal to no macrophages, fibroblasts, or collagen.

Meek et al<sup>9,23</sup> have demonstrated reduction in fibronectins, proinflammatory cytokine production, and TGF- $\beta$ 1 production in Dupuytren's tissue after treatment with steroids. This effect is caused by decreasing the transendothelial migration of inflammatory cells and by reducing local reproduction of cells already present at the inflammatory site, all of which play a role in inflammatory cell apoptosis.<sup>9,23</sup>

The above effect explains why triamcinolone, when injected into wound edges after excision of a keloid or hypertrophic scar, delays or prevents recurrence of those lesions (Fig. 7). This has obvious implications on the recurrence of Dupuytren's disease after fasciectomy.

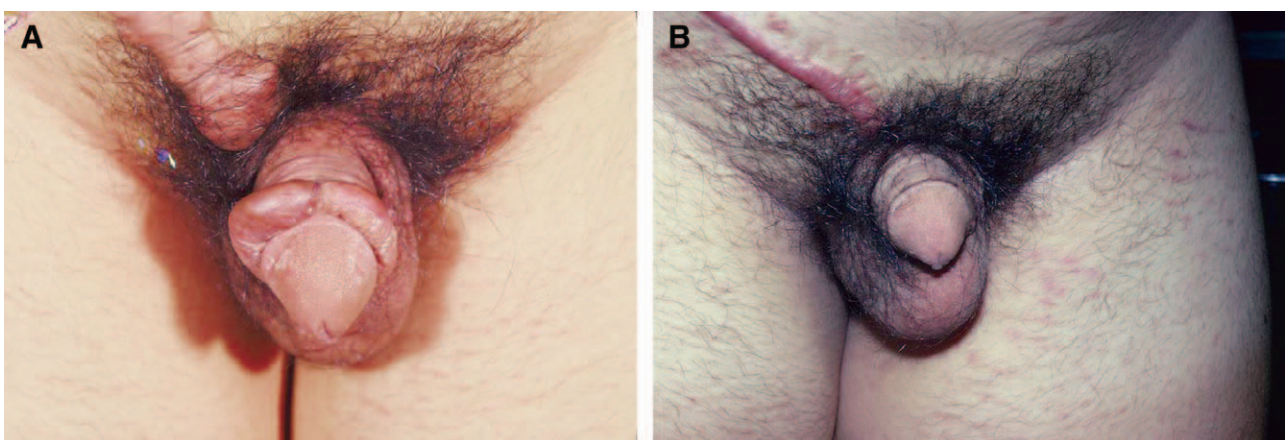
The practical application of triamcinolone in the treatment of the nodule is based on the following information.

### NATURAL HISTORY OF DUPUYTREN'S DISEASE

The intralesional injection of triamcinolone is founded on the natural history of the disease as observed by Millesi<sup>26</sup> who showed that in 5 years, 50% of individuals with a nodule will develop progression of the disease beyond stage zero (ie, the nodule alone) and that in 10 years, there would be a joint contracture. Also at 10 years, in 50% of cases there will be bilateral disease.<sup>26</sup>

The almost universally taught dictum in treating Dupuytren's disease is to wait until there is a 20-degree joint contracture of a metacarpal-phalangeal joint; at that time, some type of surgical release of the contracture would be recommended. Based on the author's 40-year experience with intralesional injections of Dupuytren's nodules with triamcinolone, a more proactive approach is recommended.

A 4-year window into that experience was examined, and it was found that 93% of patients, whose nodules of Dupuytren's disease were injected



**Fig. 7.** A, Keloids following circumcision and inguinal herniorrhaphy. B, The same structures following excision of the keloids and injection of the wound edges with triamcinolone. At 6 months, there is minimal recurrence.

intralesionally with triamcinolone, experienced softening and flattening of their nodules. Some experienced complete resolution, but usually there was some residual amount of nodule present. Even so, what happened in the great majority of cases was a moratorium on the progression of the disease, in 1 case over 30 years.<sup>27</sup> The usual scenario is that there is reactivation of the nodule in 1–3 years. Nevertheless, prompt reinjection more often than not returns the nodule to a quiescent state. The smaller the nodule when first treated, the more satisfactory the response.

Over the 40-year period, the author has seen 2 flexor tendon ruptures, both in women; and in both cases, guidelines to the recommended protocol were not followed, that is, waiting 6 months before reinjecting, after a series of 3 injections 6 weeks apart.

### TRIAMCINOLONE PROTOCOL

After a patient is diagnosed with a nodule of Dupuytren's disease, he or she is given the option of watchful waiting or proceeding with a series of injections. If injections are requested, an area proximal to the nodule is injected with lidocaine to minimize motion. If lidocaine is mixed with the triamcinolone when the injection is performed, there is not enough time for the lidocaine to become effective and the patient's hand may move, permitting injection into normal tis-

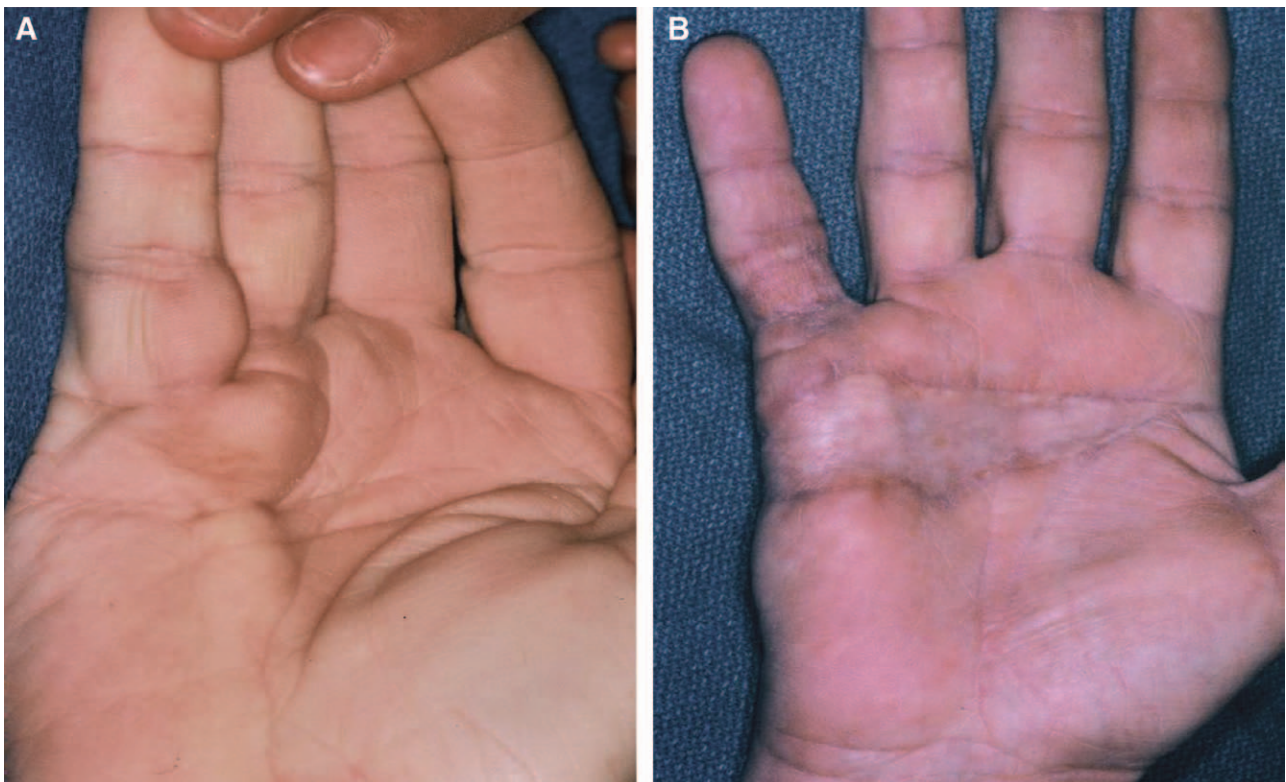
ues. Additionally, lidocaine precipitates the triamcinolone, making it less effective. Most patients require 3 injections, 6 weeks apart. The dosage for smaller nodules is 40–60 mg and for larger nodules, 80–120 mg. In women, 100 mg is usually the maximum dose because of temporary adrenal suppression.<sup>27</sup>

With the above dosage schedule, no untoward systemic signs or symptoms have been observed. Patients with diabetes mellitus are warned that their blood sugar will be elevated for 3–4 days.

After the third injection, the patient is asked to return in 6 months to determine whether an additional injection is indicated. Intralesional injections with triamcinolone into plantar nodules or knuckle pads are very effective. Surgical excision is not recommended for plantar nodules as the patient would be applying weight to a scar in a dependent position. Excision of knuckle pads is also not recommended because motion at the proximal inter-phalangeal joint postoperatively is painful and healing may be slowed.

### SURGICAL OPTIONS

In patients with large multiple nodules or aggressive rapidly progressing disease, we do not recommend the injections. Instead, dermofasciectomy and full-thickness graft(s) are the recommended treatment of Ketchum<sup>28</sup> (Fig. 8).



**Fig. 8.** Dupuytren's contracture of the right palm and digits 4 and 5 (A) and 6 months after dermofasciectomy and full-thickness grafts of right palm and fifth digit (B).



As is well known, nodules of Dupuytren's disease are not usually painful; however, at the distal palmar crease, the disease process can follow the bands of Legueu and Juvara down and along each side of the first annular pulley. With contracture of the diseased tissue, stenosis of the first annular pulley can occur, producing a trigger finger. That condition usually responds favorably to a triamcinolone injection into the nodule and superficial to the pulley.

Some patients will request excision of a nodule, perhaps at the time of a trigger finger release. At that time, in addition to excising the nodule and releasing the A-1 pulley, a Z-plasty can be performed to decrease mechanical tension on the skin, and the wound edges can be injected with triamcinolone, which may beneficially modify the inflammatory phase of wound healing and decrease the chance of recurrence of the nodule, as seen in Figure 9.

Pre- and post-triamcinolone injection photographs of a patient with nodules of Dupuytren's disease are seen in Figure 10. Subcutaneous atrophy and depigmentation are seen in some cases. These are transient complications that usually resolve within 6 months of the last injection.

### OTHER NONSURGICAL TREATMENTS OF DUPUYTREN'S NODULES

Other nonsurgical treatments of Dupuytren's nodules that have been proposed address the reduction of free radicals, the use of prostaglandin prostaglandin E2, verapamil, and phosphatase B, the reduction of triglycerides as well as the use of interferon- $\gamma$  to block the contractile mechanism of myofibroblasts, and the use of decorin to modify TGF $\beta$ -1 production.

These are all biochemical attacks on the early pathological changes in the nodule that have been

proposed by Al-Qattan,<sup>1</sup> Hurst and Badalamente,<sup>30</sup> Lee et al,<sup>31</sup> Rayan,<sup>32</sup> Tomasek et al,<sup>13</sup> and Hsu and Chang,<sup>33</sup> respectively.

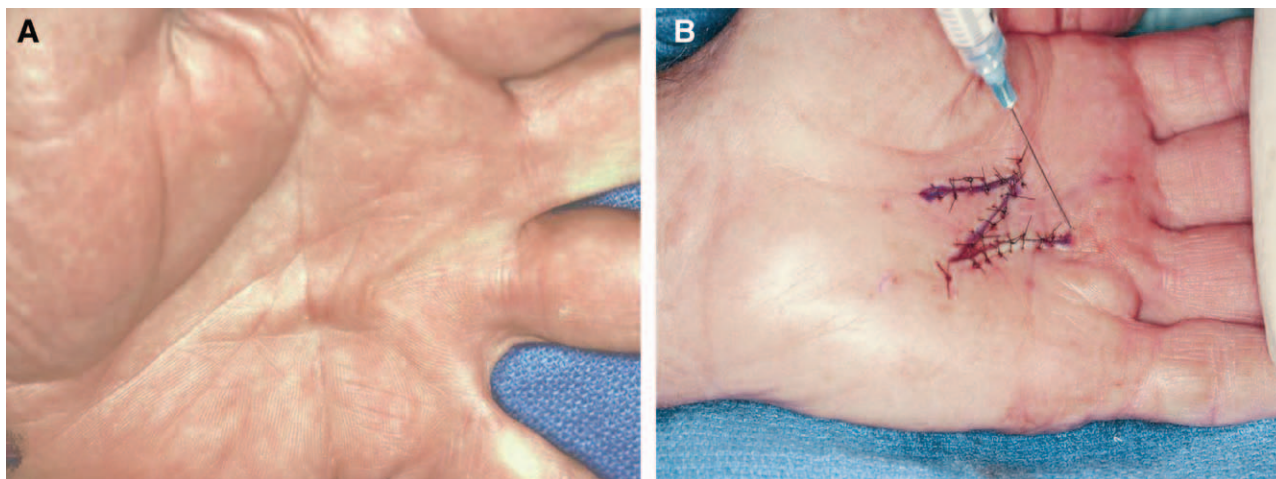
These nonsurgical treatments of Dupuytren's nodules are intriguing and have significant theoretical value, but at this time, they have minimal clinical application.

### XIAFLEX

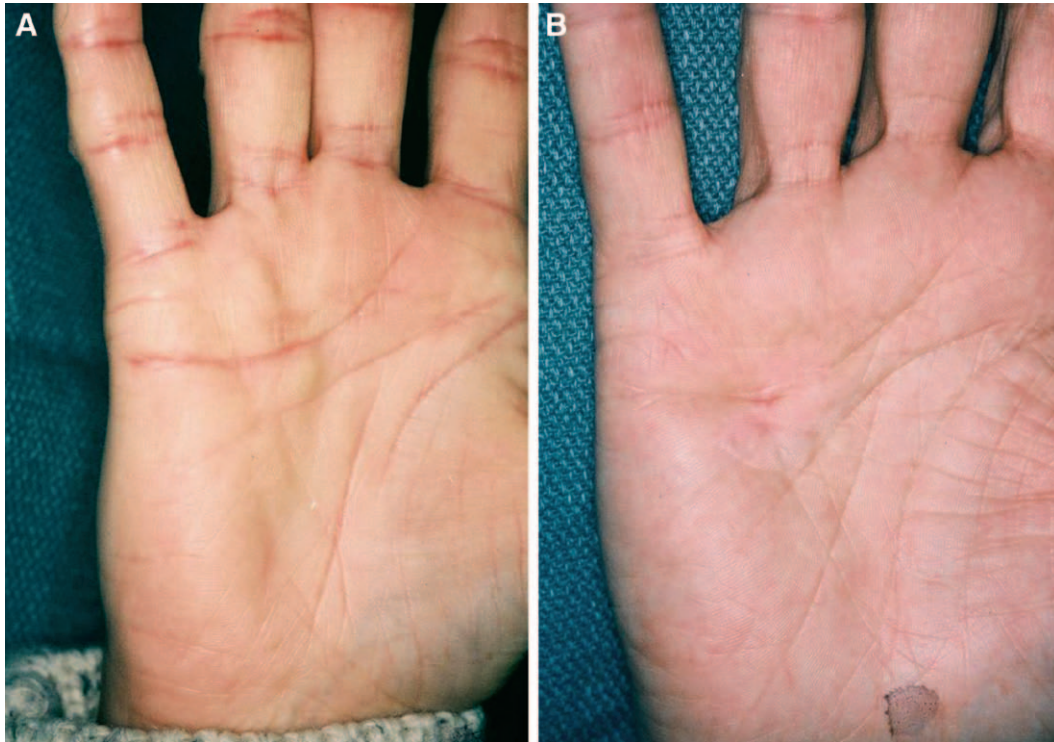
Xiaflex, developed by Hurst and Badalamente,<sup>34</sup> is a powerful and important new adjunct in the treatment of Dupuytren's disease; its main effect is not on the nodule but on the disruption of cords through collagenolysis. Cost may be a consideration in the use of Xiaflex.

### NEEDLE APONEUROTOMY

Needle aponeurotomy is also a new and increasingly popular means of treating established discreet contractures; this is accomplished by scarifying a cord with an 18-gauge needle. In so doing, the cross-sectional area and thus the tensile strength of the cord are diminished in several places to the extent that it can be ruptured. It is especially effective when used in the palm; in a contracted digit, where flexor tendons and neurovascular structures are in close proximity to a cord, caution must be used to avoid injury to those structures. Both Xiaflex and needle aponeurotomy have a significant rate of recurrence at 3 years, with that of needle aponeurotomy being higher than that of Xiaflex. Both options focus on treatment of the cords in Dupuytren's disease, rather than the nodule. As previously stated, the focus of this article is on the development and treatment of the nodule, which is the engine of the disease process.<sup>35</sup>



**Fig. 9.** Nodule and cords of left palm going into the third and fifth digits, preoperatively (A), and after excision with a Z-plasty to relieve skin tension and injection of the wound edges with triamcinolone to modify wound healing (B).



**Fig. 10.** Nodules of Dupuytren’s disease in the right palm, status preinjection with triamcinolone (A). The same hand 6 months post injection, demonstrating flattening of the nodules with some transient depigmentation (B).

### CONCLUSIONS

The most effective management of Dupuytren’s disease is early recognition and treatment of the nodule, before the development of a joint contracture. As there is evidence of a significant inflammatory role in the development of the nodule, the process of fibroplasia can be minimized by altering the macrophage > fibroblast > collagen cascade by the intralesional injection of a potent anti-inflammatory agent such as triamcinolone, which also blocks tissue inhibitors of collagenase, thus enhancing the action of native collagenase, and reduces the size and firmness of nodules and, at least temporarily, arrests their progression.

**Lynn D. Ketchum, MD**  
 4402 West 111th Terrace  
 Leawood, KS 66211  
 E-mail: ldkmd5701@aol.com

### REFERENCES

- Al-Qattan MM. Factors in the pathogenesis of Dupuytren’s contracture. *J Hand Surg Am.* 2006;31:1527–1534.
- Luck V. Dupuytren’s contracture. A new concept of the pathogenesis correlated with surgical management. *J Bone and Joint Surg.* 1959;41:635–664.
- Fitzgerald AMP, Kirkpatrick JJR, Foo ITH, et al. A picropolychrome staining technique applied to Dupuytren’s tissue. *J Hand Surg.* 1995;20:519–524.
- Meister P, Gokel JM, Remberger K. Palmar fibromatosis-“Dupuytren’s contracture”. A comparison of light electron and immunofluorescence microscopic findings. *Pathol Res Pract.* 1979;164:402–412.
- McCann BG, Logan A, Belcher H, et al. The presence of myofibroblasts in the dermis of patients with Dupuytren’s contracture. A possible source for recurrence. *J Hand Surg Br.* 1993;18:656–661.
- Murrell GAC. The role of the fibroblast in Dupuytren’s contracture. *Hand Clin.* 1991;7:669–680.
- Vracko R. Basal lamina layering in diabetes mellitus. Evidence for accelerated rate of cell death and cell regeneration. *Diabetes* 1974;23:94–104.
- Cloud J. Why genes aren’t destiny. *Time* 2010;49–53.
- Meek RM, McLellan S, Crossan JF. Dupuytren’s disease. A model for the mechanism of fibrosis and its modulation by steroids. *J Bone Joint Surg Br.* 1999;81:732–738.
- Badalamente MA, Hurst LC. The biochemistry of Dupuytren’s disease. *Hand Clin.* 1999;15:35–42, v.
- Baird KS, Crossan JF, Ralston SH. Abnormal growth factor and cytokine expression in Dupuytren’s contracture. *J Clin Pathol.* 1993;46:425–428.
- Badalamente MA, Sampson SP, Hurst LC, et al. The role of transforming growth factor beta in Dupuytren’s disease. *J Hand Surg Am.* 1996;21:210–215.
- Tomasek JJ, Vaughan MB, Haakma CJ. Cellular structure and biology of Dupuytren’s disease. *Hand Clin.* 1999;15:21–34.
- van der Bend RL, Brunner J, Jalink K. Identification of a putative membrane receptor for the active biolipid, lysophosphatidic acid. *J Endo.* 1992;11:2495–2501.

15. Gabbiani G, Majno G. Dupuytren's contracture: fibroblast contraction? An ultrastructural study. *Am J Pathol.* 1972;66:131–138.
16. Badalamente MA, Stern L, Hurst LC. The pathogenesis of Dupuytren's contracture: contractile mechanisms of the myofibroblasts. *J Hand Surg Am.* 1983;8:235–243.
17. Ulrich D, Hrynyschyn K, Pallua N. Matrix metalloproteinases and tissue inhibitors of metalloproteinases in sera and tissue of patients with Dupuytren's disease. *Plast Reconstr Surg.* 2003;112:1279–1286.
18. Bilderback KK, Rayan GM. The septa of Legueu and Juvara: an anatomic study. *J Hand Surg Am.* 2004;29:494–499.
19. Dupuytren G. Permanent retraction of the fingers, produced by an affection of the palmar fascia. *Lancet* 1834;2:222–225.
20. Hueston JT. The control of recurrent Dupuytren's contracture by skin re-placement. *Br J Plast Surg.* 1969;22:152–156.
21. Tubiana R, Leclercq C. Recurrent Dupuytren's disease. In: Hueston JT, Tubiana R, eds. *Dupuytren's Disease.* 2nd ed. New York, N.Y.: Grune and Stratton; 1985:204.
22. Hueston JT. Comment on the role of the fibroblast in Dupuytren's contracture. *Hand Clin.* 1991;7:661.
23. Meek RMD, McClellan S, Reilly J, et al. The effect of steroids on Dupuytren's disease: role of programmed cell death. *J Hand Surg.* 2002;27:270–273.
24. Ketchum LD, Smith J, Robinson DW, et al. The treatment of hypertrophic scar, keloid and scar contracture by triamcinolone acetonide. *Plast Reconstr Surg.* 1966;38:209–218.
25. Ketchum LD, Robinson DW, Masters FX, et al. Degradation of mature collagen with triamcinolone acetonide: a laboratory study. *Plast Reconstr Surg.* 1967;40:89–91.
26. Millesi H. The clinical and morphological course of Dupuytren's disease. In: Hueston JT, Tubiana R, eds. *Dupuytren's Disease.* 2nd ed. New York, N.Y.: Grune and Stratton; 1985:114–121.
27. Ketchum LD, Donahue TK. The injection of nodules of Dupuytren's disease with triamcinolone acetonide. *J Hand Surg Am.* 2000;25:1157–1162.
28. Ketchum LD. Expanded dermofasciectomy and full-thickness grafts in the treatment of Dupuytren's contracture. A 36 year experience. In: Eaton C, Seegenschmiedt MR, Bayat A, et al, eds. *Dupuytren's Disease and Related Hyperproliferative Disorders.* Heidelberg: Springer; 2012:213–220.
29. Jacob T, Hingorani A, Ascher E. Overexpression of transforming growth factor-beta1 correlates with increased synthesis of nitric oxide synthase in varicose veins. *J Vasc Surg.* 2005;41:523–530.
30. Hurst LC, Badalamente MA, Makowski J. The pathobiology of Dupuytren's contracture: effects of prostaglandins on myofibroblasts. *J Hand Surg Am.* 1986;11:18–23.
31. Lee RC, Doong H, Jellema AF. The response of burn scars to intralesional verapamil. Report of five cases. *Arch Surg.* 1994;129:107–111.
32. Rayan GM, Parizi M, Tomasek JJ. Pharmacologic regulation of Dupuytren's fibroblast contraction in vitro. *J Hand Surg Am.* 1996;21:1065–1070.
33. Hsu C, Chang J. Clinical implications of growth factors in flexor tendon wound healing. *J Hand Surg Am.* 2004;29A:551–563.
34. Hurst LC, Badalamente MA. Non-operative treatment of Dupuytren's disease. *Hand Clin.* 1995;1:97–107.
35. Eaton C. A technique of needle aponeurotomy for Dupuytren's contracture. In: Eaton C, Seegenschmiedt MH, Bayat A, et al, eds. *Dupuytren's Disease.* Heidelberg: Springer; 2012:267.