


AUTHOR QUERY FORM

 ELSEVIER	Journal: BONSOI	Please e-mail or fax your responses and any corrections to:
	Article Number: 3965	E-mail: corrections.esme@elsevier.thomsondigital.com
	Fax: +33 (0) 1 71 16 51 88	

Dear Author,

Please check your proof carefully and mark all corrections at the appropriate place in the proof (e.g., by using on-screen annotation in the PDF file) or compile them in a separate list. Note: if you opt to annotate the file with software other than Adobe Reader then please also highlight the appropriate place in the PDF file. To ensure fast publication of your paper please return your corrections within 48 hours.

For correction or revision of any artwork, please consult <http://www.elsevier.com/artworkinstructions>.

Any queries or remarks that have arisen during the processing of your manuscript are listed below and highlighted by flags in the proof. Click on the 'Q' link to go to the location in the proof.

Location in article	Query / Remark: click on the Q link to go Please insert your reply or correction at the corresponding line in the proof
Q1 Q2	<p>Please confirm that given names and surnames have been identified correctly. Please provide a conflict of interest statement. If there is no conflict of interest, please state that.</p> <div style="border: 1px solid black; padding: 10px; margin-top: 20px;"> <p>Please check this box or indicate your approval if you have no corrections to make to the PDF file <input type="checkbox"/></p> </div>

Thank you for your assistance.



Available online at
SciVerse ScienceDirect
www.sciencedirect.com

Elsevier Masson France
EM|consulte
www.em-consulte.com/en



Letter to the editor

Abrupt development of Dupuytren's contractures with the BRAF inhibitor vemurafenib

ARTICLE INFO

Keywords:
Vemurafenib
Dupuytren
BRAF inhibitor

Vemurafenib, a serine-threonine kinase inhibitor, has recently been approved for the treatment of patients with metastatic melanoma harbouring a BRAF V600E mutation. While vemurafenib significantly improves overall survival of treated patients [1], it frequently induces skin toxicity, which affects more than 90% of patients [2]. It primarily involves phototoxicity, maculopapular rashes, the development of verrucal papillomas, squamous cell carcinomas, hand-foot syndrome and even *de novo* melanomas [2–4]. Rheumatological adverse events are also common, primarily in the form of inflammatory arthralgia, which is identified in 50% of cases, of grade 2 or 3 in more than 20% of cases [1]. We describe here the abrupt onset of Dupuytren's contractures after introduction of vemurafenib. This adverse event has never previously been reported.

A 66-year-old male patient was managed for melanoma with unresectable metastatic cervical lymph nodes. Lymph node metastases carried a V600E mutation and vemurafenib was started (Zelboraf®, 960 mg, twice daily orally). After 6 weeks of treatment, the patient noted the rapidly progressive development of fixed digital flexion contractures affecting the metacarpophalangeal joints of the small and ring fingers, with visible cords adhering to the skin (Fig. 1). The impairment was bilateral but asymmetrical. The

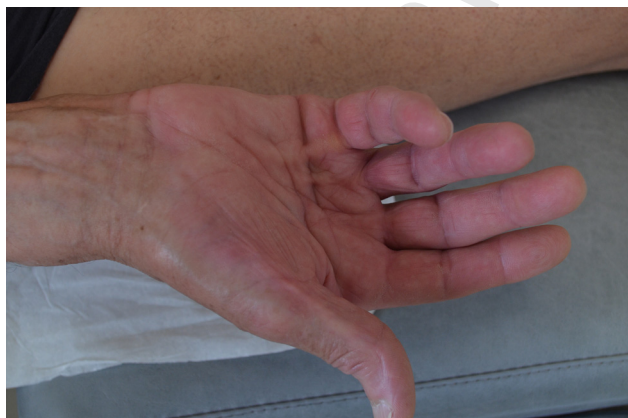

Fig. 1. Visible cords after 6 weeks of treatment.

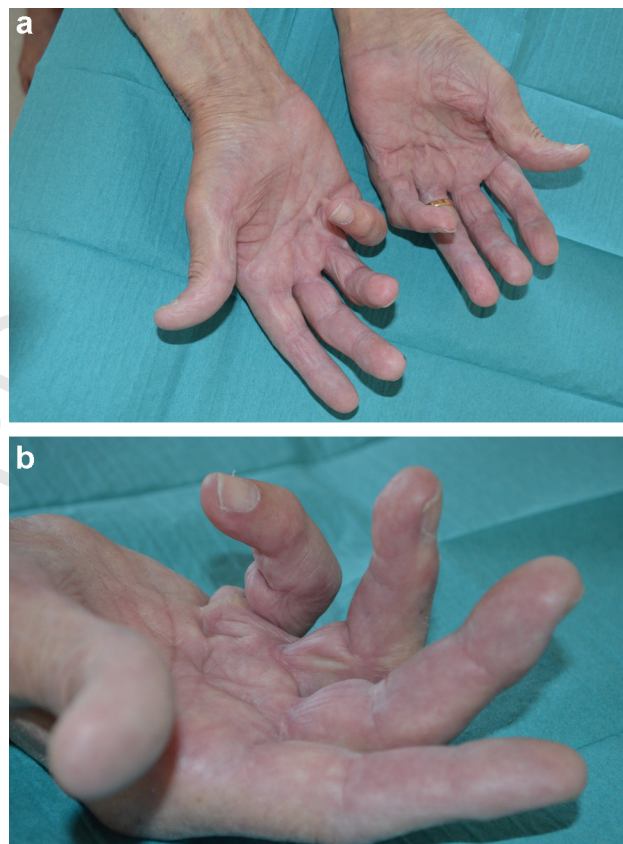


Fig. 2. a, b Persistent fixed digital flexions.

diagnosis of Dupuytren's contractures was adopted, with a Tubiana score of 10 (left) and 7 (right), respectively. No associated nodules were identified and knuckle pads and Garrod's nodes as well as Ledderhose disease were not found either. The lesions rapidly worsened, considerably affecting certain activities of daily living. It was then decided to definitively discontinue the treatment. Three months later, the digital cords remained globally stable without worsening or improving (Fig. 2a and b).

Dupuytren's disease usually occurs in isolation but can sometimes be associated with several risk factors, including genetic predisposition, diabetes, smoking, alcohol consumption, HIV infection, use of anticonvulsant drugs, and exposure to recurrent trauma [5–7]. It has also been very exceptionally reported in patients treated for advanced cancer with matrix metalloproteinase inhibitors [8]. Although Dupuytren's disease is more prevalent in Caucasian males over the age of 60 years [5,7], its onset in our patient seems to be no coincidence here. First, the patient displayed none of the known associated factors described above. Most

importantly, the lesions developed very rapidly after the introduction of vemurafenib and became clearly symptomatic within just a few weeks, not following the conventional, slow, three-stage progression of Dupuytren's disease [5–7]. Lastly, a link between the development of Dupuytren's contractures and the use of BRAF inhibitor has been suggested very recently in a patient enrolled in a clinical trial [9]. The pathophysiology of Dupuytren's disease is still poorly understood and the cause of myofibroblast proliferation is a matter of speculation [5,6]. We can here hypothesize that vemurafenib induces a paradoxical proliferation in wild type-BRAF myofibroblasts, similar to the mechanism previously described in keratinocytes and melanocytes devoid of a BRAF mutation, leading to the development of skin tumours in treated patients [2–4].

Finally, we can suggest in this context that a local management with fasciotomy should be more appropriate than aponeurectomy [10].

Addendum: this adverse event has been reported to both Centre régional de pharmacovigilance and Pharmacovigilance department of Roche® (Ref AG/VY-LRN 2130961), and subsequently to the French Health Authorities.

Disclosure of interest

The authors have not supplied their declaration of conflict of interest.

References

- [1] Chapman PB, Hauschild A, Robert C, et al. Improved survival with vemurafenib in melanoma with BRAF V600E mutation. *N Engl J Med* 2011;364:2507–16.
- [2] Lacouture ME, Duvic M, Hauschild A, et al. Analysis of dermatologic events in vemurafenib-treated patients with melanoma. *Oncologist* 2013;18:314–22.
- [3] Sibaud V, Lamant L, Maisongrosse V, et al. Adverse skin reactions induced by BRAF inhibitors: a systematic review. *Ann Dermatol Venereol* 2013;140:510–20.

- [4] Boussemaert L, Routier E, Mateus C, et al. Prospective study of cutaneous side-effects associated with the BRAF inhibitor vemurafenib: a study of 42 patients. *Ann Oncol* 2013;24:1691–7.
- [5] Picardo NE, Khan WS. Advances in the understanding of the aetiology of Dupuytren's disease. *Surgeon* 2012;10:151–8.
- [6] Khashan M, Smitham PJ, Khan WS, et al. Dupuytren's disease: review of the current literature. *Open Orthop J* 2011;5:283–8.
- [7] Michou L, Lermusiaux JL, Teyssedou JP, et al. Genetics of Dupuytren's disease. *Joint Bone Spine* 2012;79:7–12.
- [8] Hutchinson JW, Tierney GM, Parsons SL, et al. Dupuytren's disease and frozen shoulder induced by treatment with a matrix metalloproteinase inhibitor. *J Bone Joint Surg Br* 1998;80:907–8.
- [9] Taylor L, Bicknell M, Ciura A, et al. Dupuytren's contractures secondary to BRAF kinase inhibitor therapy. *J Am Acad Dermatol* 2013;68:AB179.
- [10] Beaudreuil J, Lellouche H, Orcel P, et al. Needle aponeurotomy in Dupuytren's disease. *Joint Bone Spine* 2012;79:13–6.

Vincent Sibaud* Q1

Dermatology, Claudius Regaud Institute,
Comprehensive Cancer Center, 20–24, rue du Pont
Saint-Pierre, 31052 Toulouse, France

Christine Chevreau

Medical Oncology Departments, Claudius Regaud
Institute, Comprehensive Cancer Center, Toulouse,
France

* Corresponding author. Tel.: +33 5 61 42 46 17;
fax: +33 5 61 42 46 21.
E-mail address: sibaud.vincent@claudiusregaud.fr
(V. Sibaud)

Accepted 12 December 2013
Available online xxx