

Hueston Revisited: Use of Acellular Dermal Matrix Following Fasciectomy for the Treatment of Dupuytren's Disease

Michael J. Terry, MD, Gloria R. Sue, MA, Carolyn Goldberg, MD, and Deepak Narayan, MD

Abstract: Various surgical treatment modalities have been advocated for the treatment of Dupuytren's disease. However, recurrence following surgical treatment of Dupuytren's disease remains a common problem. Previous studies have demonstrated lower recurrence rates with use of a full-thickness skin graft. We therefore postulated that use of acellular dermal matrix may be associated with a similar outcome, based on the common inhibitory effect on underlying myofibroblasts. We performed a retrospective cohort study of 43 patients undergoing open fasciectomy for Dupuytren's disease from years 2005 to 2012 at our academic institution. Standard fasciectomies of the affected palmar and digital fascia were performed via Brunner incisions on all patients. Patients in the experimental group had a sheet of acellular dermal matrix (Alloderm; LifeCell, Bridgewater, NJ) sutured into the surgical bed with interrupted absorbable sutures before closure, whereas patients in the control group were not closed with acellular dermal matrix. Patients were then evaluated at follow-up for disease recurrence, defined as presence of Dupuytren's tissue in an area previously operated on with a contracture greater than that recorded following the surgical fasciectomy, or presence of contracture requiring surgery. Among our cohort of 43 patients, 23 (53.5%) were treated with acellular dermal matrix while 20 (46.5%) were not. The median age of our cohort was 66.5 years (range 54–91 years). The median follow-up was 1.8 years. During this follow-up period, recurrence of contracture was observed in 1 of 23 patients in the group receiving acellular dermal matrix, compared to 5 of 20 in the control group ($P = 0.045$). No differences in the incidence of minor wound complications were observed. Our novel technique of placement of acellular dermal matrix into the wound bed following fasciectomy for Dupuytren's disease may be an important surgical strategy to reduce recurrence rates in patients with Dupuytren's disease.

Key Words: acellular dermal matrix, Dupuytren's contracture, recurrence

(*Ann Plast Surg* 2014;72: 00–00)

Dupuytren's disease is a slowly progressive condition involving abnormal thickening and contraction of connective tissue elements of the hand. There is a wide spectrum of disease presentation, ranging from isolated palmar pits and nodules to disabling flexion contractures of the metacarpophalangeal and interphalangeal joints.

Surgery has been the mainstay of treatment since the 1800s and include fasciotomy,^{1,2} limited or extensive fasciectomy,³ and dermofasciectomy.⁴ Surgical procedures are highly effective in treating the contractures. Disease recurrence, however, has been a major challenge for hand surgeons, with a recent meta-analysis reporting a 39% recurrence rate for fasciectomy and a 62% recurrence rate for fasciotomy at a median follow-up of 4 years.⁵

Received October 2, 2013, and accepted for publication, after revision, December 13, 2013.

From the *Department of Surgery, Section of Plastic and Reconstructive Surgery, Yale University School of Medicine, New Haven, CT.

This work was presented as an oral presentation at the 30th Annual Meeting of the Northeastern Society of Plastic Surgeons on September 20, 2013.

Conflicts of interest and source of funding: none declared.

Reprints: Deepak Narayan, MD, Department of Surgery, Section of Plastic Surgery, Yale University School of Medicine, P.O. Box 208062, New Haven, CT 06520.

E-mail: deepak.narayan@yale.edu

Copyright © 2014 by Lippincott Williams & Wilkins

ISSN: 0148-7043/14/7203-0000

DOI: 10.1097/SAP.0000000000000133

In 1962, Hueston reported on a series of patients who underwent dermofasciectomy for treatment of Dupuytren's contracture, consisting of excision of overlying skin in addition to the diseased fascia, followed by application of full-thickness skin grafts to the resulting wound bed.⁶ Since that time, multiple retrospective case series have reported that Dupuytren's disease rarely recurs beneath skin grafts.^{7–16} The mechanism behind this phenomenon remains unclear. Myofibroblasts play a role in the development of the disease, and in 1979, Rudolph et al demonstrated that myofibroblasts are inhibited by the presence of full-thickness skin grafts.¹⁷ In 1993, McCann et al observed that in a large proportion of tissue samples from patients with Dupuytren's disease, myofibroblasts were found extending into the dermis.¹⁸ These findings potentially implicate an abnormal interaction between the overlying dermis and underlying connective tissue layers in the development of the disease, and may explain why procedures that leave the overlying dermis intact have such a high recurrence rate.

We hypothesized that blocking interactions between the dermis and wound bed with a mechanical and physiological barrier would lead to the same low recurrence rates observed with dermofasciectomy. We therefore incorporated thick sheets of acellular dermal matrix into our standard fasciectomy procedure for Dupuytren's disease, placing the sheet in the wound bed overlying the region of excised fascia before skin closure. Here, we present the results of the pilot series of patients.

MATERIALS AND METHODS

We performed a retrospective cohort study of 43 patients undergoing open fasciectomy for Dupuytren's disease from years 2005 to 2012 performed by a single surgeon (D.N.) at our academic institution. Only patients with symptomatic Dupuytren's disease with presence of nodules and/or joint contracture were included in this study. Standard fasciectomies of the affected palmar and digital fascia were performed via Brunner incisions on all patients. Sequential patients presenting from 2005 through 2007 were included in the control group, while patients presenting from 2008 through 2012 all were treated with acellular dermal matrix. Patients in the latter group had a sheet of acellular dermal matrix (Alloderm; LifeCell) sutured into the surgical bed with interrupted absorbable sutures before closure (Fig. 1), whereas patients in the control group were not closed with acellular dermal matrix. Patients were then evaluated at periodic follow-up visits for disease recurrence, defined as presence of Dupuytren's tissue in an area previously operated on with a contracture greater than that recorded following the surgical fasciectomy, or presence of a contracture requiring surgical treatment. Bivariate analysis was performed using chi-square using IBM SPSS Statistics version 19.0.0 (IBM, Armonk, NY). This study was approved by the Human Investigations Committee at the Yale University School of Medicine.

RESULTS

Among our cohort of 43 patients, 23 (53.5%) were treated with acellular dermal matrix while 20 (46.5%) were not. The median age of our patient cohort was 66.5 years (range 54–91). There were no statistically significant differences between the 2 patient groups in terms of age, length of follow-up, severity of disease on initial

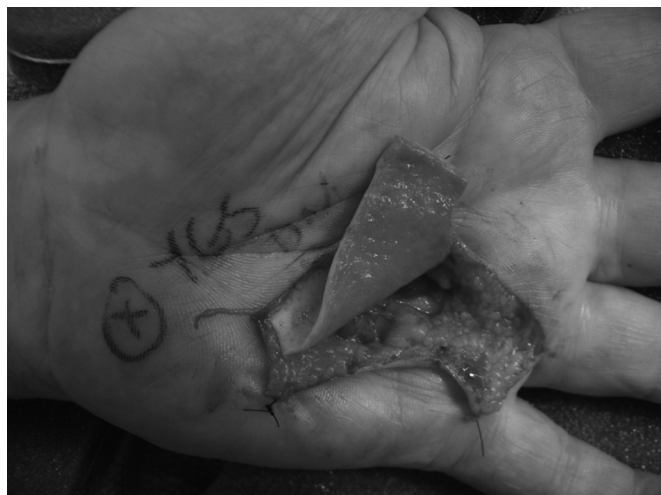

FIGURE 1. Insetting of dermal matrix to the wound bed.

presentation, presence of diabetes or prostate cancer, use of beta-blockers or alcohol, and presence of seizure disorder (Table 1). The distribution of the areas of the hand with Dupuytren's tissue was also similar between the 2 groups (Table 2).

The median follow-up time was 1.8 years. During this follow-up period, recurrent disease was noted in 5 of 20 (25.0%) patients in the control group, and 1 of 23 (4.3%) patients in the group treated with acellular dermal matrix ($P = 0.045$) (Fig. 2). There were 3 patients with minor wound complications in each group. These complications consisted of small wound separations that healed with local wound care in all cases. There were no complications associated directly with the use of acellular dermal matrix, as no seromas, infections, or extrusions were observed. Interestingly, 2 patients receiving the experimental treatment presented in follow-up with disease extension beyond the borders of the acellular dermal matrix with no evidence of disease recurrence under the area covered by acellular dermal matrix, attesting to the possible inhibitory effects of the acellular dermal matrix.

DISCUSSION

In this pilot study, we observed 1 recurrence in 23 patients who underwent fasciectomy with implantation of acellular dermal matrix, yielding a recurrence rate of 4.3% at 1.8 years median follow-up. We report a recurrence rate of 25.0% for standard open fasciectomies. The complication rates between the standard open fasciectomy and fasciectomy with acellular dermal matrix are comparable—all were minor wound complications that resolved with local wound care.

The optimal treatment for primary Dupuytren's disease remains controversial. In recent years, non-operative methods such as injection of clostridial collagenase have been explored. However, randomized, controlled trials have shown that these injections are

TABLE 1. Characteristics of Control and Acellular Dermal Matrix Patient Cohorts

Characteristic	Control Group (n = 20)	Dermal Matrix Group (n = 23)
Median age	66	69
Diabetes	5	4
Prostate cancer	8	8
Beta blockers	3	7
Significant alcohol history	7	9
History of seizure disorder	1	2

TABLE 2. The Distribution of Affected Areas of the Hand are Similar Between the 2 Groups

Affected Part of Hand	Control Group	Dermal Matrix Group
Small finger	11	11
Ring finger	14	15
Middle finger	5	7
Index finger	1	1
Thumb	0	2
Palm	8	9

able to restore only 50% to 64% of joints to normal or near-normal extension.^{19,20} Additionally, 96% to 100% of patients who received collagenase reported at least 1 treatment-related adverse event, compared to 21.2% of those who received placebo.^{19,20} Data from long-term follow-up of patients injected with collagenase suggest that the recurrence rate is an astounding 75% at 8 years following the initial injection.²¹ Therefore, operative treatment currently remains the mainstay of therapy for Dupuytren's disease.

Reported recurrence rates for open fasciectomy in the treatment of Dupuytren's contracture vary widely in the literature. However, multiple large studies with long-term follow-up suggest that open fasciectomy is associated with high recurrence rates. A recent meta-analysis of 48 studies involving outcomes of fasciectomy and fasciotomy in European patients observed an average recurrence rate of 39% following fasciectomy, and 62% following fasciotomy.⁵ However, a separate meta-analysis concluded that comparison of techniques or results is complicated by the disparities in scoring systems, definition of recurrence, and recording of complications.²²

In 1962, Hueston published his observation that no recurrences were observed in a group of 8 patients who had undergone full-thickness excision of skin and diseased fascia, and full-thickness skin grafting, a procedure later termed "dermofasciectomy."⁶ He followed this up in 1969 by reporting a series of 65 dermofasciectomy procedures, 33 performed for primary Dupuytren's disease and 32 for recurrent.¹¹ With patient follow-up ranging from 1 to 10 years, a few cases of disease extension were observed, but no recurrence of disease beneath the skin grafts was observed.¹¹

Since that time, 8 retrospective case series and one retrospective comparative study have been published on recurrence rates following dermofasciectomy. Five hundred fifty-three rays were

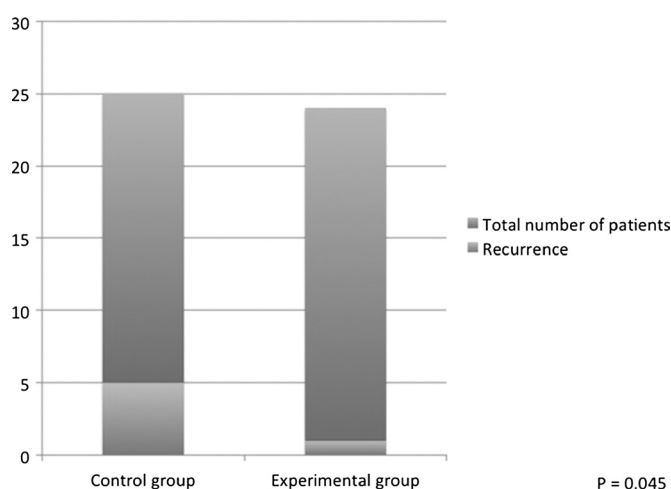


FIGURE 2. Difference in recurrence rate in the control and experimental patient cohorts.

operated on in these series, with a total of 23 definite recurrences noted underneath the skin grafts, for a recurrence rate in these series of 4%. Follow-up in these studies ranged from 9 months to 17 years. This recurrence rate is strikingly lower than most published rates for fasciectomy procedures.^{7–16}

The success of dermofasciectomy in terms of reducing recurrence rates, as well as the studies of Rudolph and McCann, suggests a link between the dermis overlying the diseased fascia and disease recurrence. However, despite its effectiveness, dermofasciectomy currently plays only a limited role in the treatment of Dupuytren's disease. The main reason for this is the significant morbidity associated with the excision and subsequent full-thickness skin grafting of the patient's native skin on the volar surface of the hand.

We hypothesized that introducing a barrier between the wound bed and the overlying dermis could replicate the success rate of dermofasciectomy by blocking interaction between the wound bed and dermis, while avoiding the disadvantages inherent in excising the skin completely and using full-thickness skin grafts. Alloderm (Lifecell Corp., Branchburg, NJ) is a natural biologic material consisting of human cadaver skin that has been treated to remove all cellular and immunogenic components. Alloderm retains the structural components of human skin and therefore does not have to be cross-linked, avoiding the unfavorable wound reactions and increased myofibroblast differentiation associated with that procedure.²³ Also, in contrast to other biologic materials, the basement membrane is retained in Alloderm. The laminin and collagen IV in the basement membrane have been shown to have a beneficial effect on wound healing and may contribute to a physiologic barrier as well as a purely mechanical one.^{24,25} These factors led us to select Alloderm as the dermal substitute for our study.

One limitation of our study is our limited sample size. Though we were able to detect a statistically significant difference between our 2 patient groups, the effect size of the utilization of acellular dermal matrix can be better elucidated with a larger study cohort. Additionally, we are also potentially limited in our ability to observe disease recurrence in our relatively limited follow-up of 1.8 years. However, our preliminary findings suggest that our novel technique of placing acellular dermal appears to reduce disease recurrence among surgically treated patients compared to the standard fasciectomy. Further studies performed in a randomized, controlled manner with larger patient cohorts and long-term follow-up are needed to better clarify the utility of this technique.

REFERENCES

1. Dupuytren G. Clinical lectures on surgery. *Lancet*. 1834;23:56–59.
2. Luck JV. Dupuytren's contracture; a new concept of the pathogenesis correlated with surgical management. *J Bone Joint Surg Am*. 1959;41-A:635–664.
3. Hamlin E Jr. Limited excision of Dupuytren's contracture. *Ann Surg*. 1952;135:94–97.
4. Hueston JT. Dermofasciectomy for Dupuytren's disease. Bulletin of the Hospital for Joint Diseases Orthopaedic Institute. *Bull Hosp Joint Dis Orthop Inst*. 1984;44:224–232.
5. Crean SM, Gerber RA, Le Graverand MP, et al. The efficacy and safety of fasciectomy and fasciotomy for Dupuytren's contracture in European patients: a structured review of published studies. *J Hand Surg Eur Vol*. 2011;36:396–407.
6. Hueston JT. Digital Wolfe grafts in recurrent Dupuytren's contracture. *Plast Reconstr Surg Transplant Bull*. 1962;29:342–344.
7. Abe Y, Rokkaku T, Kuniyoshi K, et al. Clinical results of dermofasciectomy for Dupuytren's disease in Japanese patients. *J Hand Surg Eur Vol*. 2007;32:407–410.
8. Armstrong JR, Hurren JS, Logan AM. Dermofasciectomy in the management of Dupuytren's disease. *J Bone Joint Surg Br*. 2000;82:90–94.
9. Brotherston TM, Balakrishnan C, Milner RH, et al. Long term follow-up of dermofasciectomy for Dupuytren's contracture. *Br J Plast Surg*. 1994;47:440–443.
10. Hall PN, Fitzgerald A, Sterne GD, et al. Skin replacement in Dupuytren's disease. *J Hand Surg Br*. 1997;22:193–197.
11. Hueston JT. The control of recurrent Dupuytren's contracture by skin replacement. *Br J Plastic Surg*. 1969;22:152–156.
12. Kelly SA, Burke FD, Elliot D. Injury to the distal radius as a trigger to the onset of Dupuytren's disease. *J Hand Surg Br*. 1992;17:225–229.
13. Logan AM, Brown HG, Lewis-Smith P. Radical digital dermofasciectomy in Dupuytren's disease. *J Hand Surg Br*. 1985;10:353–357.
14. Ketchum LD, Hixson FP. Dermofasciectomy and full-thickness grafts in the treatment of Dupuytren's contracture. *J Hand Surg Am*. 1987;12(5 Pt 1):659–664.
15. Tonkin MA, Burke FD, Varian JP. Dupuytren's contracture: a comparative study of fasciectomy and dermofasciectomy in one hundred patients. *J Hand Surg Br*. 1984;9:156–162.
16. Searle AE, Logan AM. A mid-term review of the results of dermofasciectomy for Dupuytren's disease. *Ann Chir Main Memb Super*. 1992;11:375–380.
17. Rudolph R. Inhibition of myofibroblasts by skin grafts. *Plast Reconstr Surg*. 1979;63:473–480.
18. McCann BG, Logan A, Belcher H, et al. The presence of myofibroblasts in the dermis of patients with Dupuytren's contracture. A possible source for recurrence. *J Hand Surg Br*. 1993;18:656–661.
19. Hurst LC, Badalamente MA, Hentz VR, et al. Injectable collagenase *Clostridium histolyticum* for Dupuytren's contracture. *N Engl J Med*. 2009;361:968–979.
20. Gilpin D, Coleman S, Hall S, et al. Injectable collagenase *Clostridium histolyticum*: a new nonsurgical treatment for Dupuytren's disease. *J Hand Surg Am*. 2010;35:2027–2038. e2021.
21. Watt AJ, Curtin CM, Hentz VR. Collagenase injection as nonsurgical treatment of Dupuytren's disease: 8-year follow-up. *J Hand Surg Am*. 2010;35:534–539, 539 e531.
22. Becker GW, Davis TR. The outcome of surgical treatments for primary Dupuytren's disease—a systematic review. *J Hand Surg Eur Vol*. 2010;35:623–626.
23. van der Veen VC, van der Wal MB, van Leeuwen MC, et al. Biological background of dermal substitutes. *Burns*. 2010;36:305–321.
24. Ralston DR, Layton C, Dalley AJ, et al. The requirement for basement membrane antigens in the production of human epidermal/dermal composites in vitro. *Br J Dermatol*. 1999;140:605–615.
25. Krejci NC, Cuono CB, Langdon RC, et al. In vitro reconstitution of skin: fibroblasts facilitate keratinocyte growth and differentiation on acellular reticular dermis. *J Invest Dermatol*. 1991;97:843–848.