



Evaluation of scars in children after treatment with low-level laser

Jehan Alsharnoubi¹ · Kamal El-Sayed Shoukry² · Mary Wadie Fawzy³ · Omnia Mohamed⁴

Received: 17 April 2018 / Accepted: 22 June 2018
© Springer-Verlag London Ltd., part of Springer Nature 2018

Abstract

Burn scars are known for their tendency to worsen with hypertrophy and contracture, causing esthetic and functional problems. The objective is to analyze the effectiveness of low-level laser therapy on post-burn hypertrophic scar tissue in children. A randomized controlled study included 15 children, ranging from 2 to 10 years of age, presented with post-burn hypertrophic scars. They received He-Ne laser and topical treatment. Each scar was divided into two halves. One half was treated with laser therapy and topical treatment (study area), and the other half was treated with topical treatment only (control area). The children were evaluated before, and after 3 months of the study by Vancouver Scar Scale (VSS), ultrasonography, and laser Doppler perfusion imaging. Significant improvement was reported in the studied area, compared to the control area for patients with *P* values ($P = 0.003$) and ($P = 0.005$), for VSS and U/S scores, respectively. No differences were detected for blood perfusion of the scar between both areas ($P = 0.73$). In addition, no adverse effects were reported. Photobiomodulation (PBM) is an efficient and safe therapeutic modality for post-burn hypertrophic scars in children, with no side effects, and should be considered a part of combination therapy for better results.

Keywords Burn · Scars · Photobiomodulation

Introduction

Scars cause functional, cosmetic, and emotional issues to affected patients, as well as being permanent reminders of traumatic events behind them. Patients with hypertrophic scars have a compromised quality of life with physical, psychological, and social challenges. Some scars heal quickly, while others are transformed into hypertrophic scars or keloids. These problematic scars usually need to be treated for months or even years, leading to significant functional and psychological problems [1]. The best treatment strategy is prevention of

keloid and hypertrophic scars. There are no accepted treatment modalities that result in complete and permanent hypertrophic scar or keloid amelioration [2].

The treatment of burn scars is one of the most important clinical challenges in all cultures, in developing countries in specific, for its tremendous treatment cost. For example, in the USA alone, the cost reached about \$4 billion per year. The huge medical and rehabilitation charges are even higher in developing countries, because of the increased number of burn incidences [3].

There are many traditional treatments and preventive measures for hypertrophic scars, such as using pressure garments, massage therapy, corticosteroid injections, silicone gel sheeting, laser and light emitting diodes, cryotherapy, Fluorouracil (5-FU), interferon, bleomycin, imiquimod 5% cream, and surgical interventions [4].

New advances in laser and technique refinements have made laser therapy one of the most important modalities for the treatment of hypertrophic scars. The application of photobiomodulation (PBM) as a therapeutic tool has grown significantly last year, leading to improvement in the treatment of dermatological conditions. Moreover, it is being used as a promising technique, improving skin scars' appearance, leading to improvements in body functions [5].

✉ Jehan Alsharnoubi
broncojena@gmail.com

¹ Pediatrics Department, National Institute of Laser Enhanced Sciences (N.I.L.E.S), Cairo University, House 2 street 6 Zahraa Helwan, Cairo, Egypt
² Physical Therapy Department of Growth and Developmental Disorder in Children and its Surgery, Faculty of Physical Therapy, Cairo University, Cairo, Egypt
³ Lecturer of Internal Medicine, Internal Medicine Department, Faculty of Medicine, Cairo University, Cairo, Egypt
⁴ Pediatrics Department, Aboelreesh Hospital, Cairo, Egypt

Recently, it was found that He-Ne lasers have the power to suppress the proliferation and collagen formation in skin fibroblast, and increase cell apoptosis. Studies have shown that the effect of He-Ne laser on cells depends on the energy and power density [6]. They reported that He-Ne laser irradiation of 10 J/cm² energy density could damage normal and injured skin fibroblasts in vitro [7]; while He-Ne laser irradiation of 5 J/cm² every other day improved migration of fibroblasts. They have also found that a power of 16 J/cm² could suppress it with DNA damage.

The possibility of affecting fibroblasts, during skin healing by PBM, should point to trials to find a wavelength that has an inhibitory role in the treatment of hypertrophic wounds [8].

The aim of this prospective study is primary to analyze the effectiveness of PBM on burn scar tissue in children, and to compare between laser therapy and medical treatment.

Patients and methods

After the approval of the Laser Institute's Research Ethical Committee, the present study was carried out in the pediatric clinic of the National Institute of Laser Enhanced Sciences, Cairo University, as well as the burn clinic at Kasr El-Aini Hospital, Cairo University, Egypt. The study included 15 patients, of both sexes, ages ranging from 2 to 10 years old, complaining of hypertrophic burn scar with skin type ranged from II to IV, according to Fitzpatrick Skin Type chart [9].

They have no associated disorders, pregnancy, immunodeficiency, HIV, AIDS, or diabetes. Patients who had skin abnormalities, such as active skin disease within the treatment areas (i.e., psoriasis, cancer, or autoimmune disease), were excluded from the study, as well as patients with evidence of bleeding disorder or unstable heart disease, who had a history of photosensitivity, who had dark skin, or scars over growing joints, and those with history of the use of any other treatments for the scar in the past 4 weeks prior to the initiation of therapy were also excluded from the study. Every patient was subjected to a detailed history taking and physical examination. The selected treatment protocol was discussed with the children's parents, and written consent was obtained. The hypertrophic scars were divided into two halves; one half, in the studied area, received topical treatment: Scaro cream (company: Macro, active ingredients: **Decamethyltetrasiloxane + Polydimethylsiloxane + Cyclopentasiloxane**) in addition to He-Ne laser scanning technique. The other half, the controlled area, received only Scaro cream.

The research was done after ethical approval from the Institute committee.

All parents read, approved, and signed informed consent.

Treatment modalities

A laser device "bravo terza serie HE NE laser (ASA s.r.i)" (Fig. 1) with a wave length 632.8 nm (head source with aimed beam) was used. The time of application took a duration of 25 min with a power density of 119 mW/cm² and energy density of 16 J/cm².

The treatment started 3 months after wound healing. Both patient and therapist wore protective eye goggles. The head of the 632.8-nm laser was stabilized in horizontal alignment, opposite to the patient, but the beam of laser was in perpendicular direction to the hypertrophic scar. The distance between the laser probe and the burn was 70-cm length using the scanning technique, and the treatment interval was twice per week, for 12 weeks.

Patient evaluation

- A. History taking including personal history name, sex, and age at initial presentation, as well as medical history of associated diseases, if any, was recorded. Present history of scars, their duration, preliminary causes, and previous treatment modalities are also recorded.
- B. Clinical examination including 1—grading system: using the Vancouver Scar Scale (VSS). This was done to evaluate the skin thickness, pigmentation, and vascularity. 2—Ultrasonography: Ultrasound imaging system (LOGIQ P6 GE healthcare, Japan) used to measure the thickness of the skin. 3—Laser Doppler perfusion imager (LDPI): A PIM II laser Doppler perfusion imager used (Lisca AB, Linköping, Sweden). Each scar was evaluated by a blind evaluator before the treatment (pre-test), and 3 months after (post-test).

Statistical analysis

Descriptive statistics and *t* test were conducted for comparison of the mean age between both groups. *T* test was conducted for comparison of treatment mean values of scar thickness,

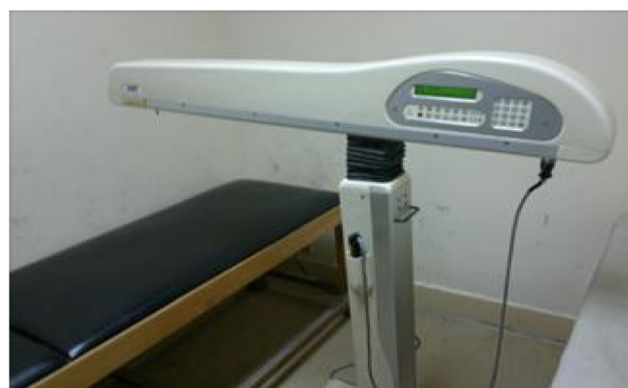

Fig. 1 He Ne laser scanning technique

and perfusion between both groups. Paired *T* test was conducted for comparison between treatment mean values of scar thickness, and perfusion before, and after treatment in each group, as well as areas in-between the study, and control areas in each group. Mann–Whitney *U* test was conducted for comparison of VSS between both groups. Wilcoxon signed ranks test was conducted for comparison of VSS between treatment before and after in each group. The level of significance for all statistical tests was set at $P < 0.05$. All statistical measures were performed through the statistical package for social studies (SPSS) version 19 for windows.

Results

The He-Ne group included 15 patients, five males and 10 females, with mean age of 4.73 ± 1.79 years, and no significance regarding genetic inheritance. They had skin type range from type II to type IV (Table 1).

Mean \pm SD for the etiology of the scars were 8(53.3%) flam burn and 7(46.7%) scaled burn. The results showed a significant difference before and after treatment regarding skin thickness of the hypertrophic scar, by ultrasonography in both the control and study areas. Before treatment, the mean \pm SD value of the whole scar was $(0.52 \pm 0.17$ mm), but the post-treatment value of the controlled area was 0.43 ± 0.13 mm and that of the studied area was $(0.34 \pm 0.09$ mm) with *P* value of (0.001) (Fig. 2).

Also, there was a significant difference before and after treatment between skin perfusion of the hypertrophic scar by LDPI in both the controlled and studied areas. Before treatment, the mean value of the whole scar was $(1.27 \pm 0.54$ V). After treatment, the value of the control area was $(0.77 \pm 0.24$ V), and that of the study area was $(0.8 \pm 0.23$ V) with *P* value of (0.0001) (Fig. 3a, b).

Table 1 Demographic data of the He-Ne group

| | He-Ne (<i>n</i> = 15) |
|---------------------|------------------------|
| Sex | |
| Male | 5 (33.3%) |
| Female | 10 (66.7%) |
| Age (mean \pm SD) | 4.73 ± 1.79 |
| Consanguinity | |
| Positive | 9 (60%) |
| Negative | 6 (40%) |
| Skin Type | |
| Type I | 0 (0%) |
| Type II | 1 (6.67%) |
| Type III | 5 (33.3%) |
| Type IV | 9 (60%) |
| Type V | 0 (0%) |

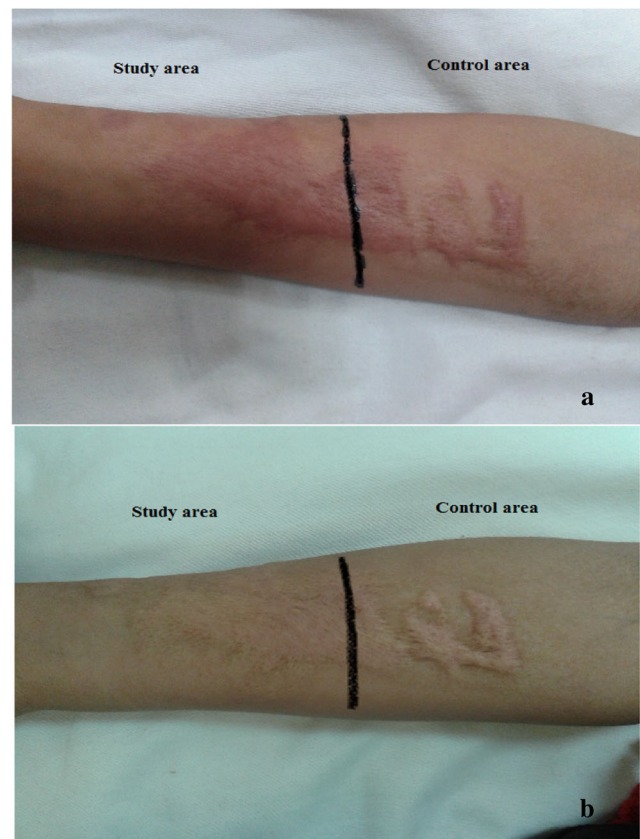


Fig. 2 a The study and control area in forearm before treatment. b The result after 12 weeks of treatment with much improvement in the studied area

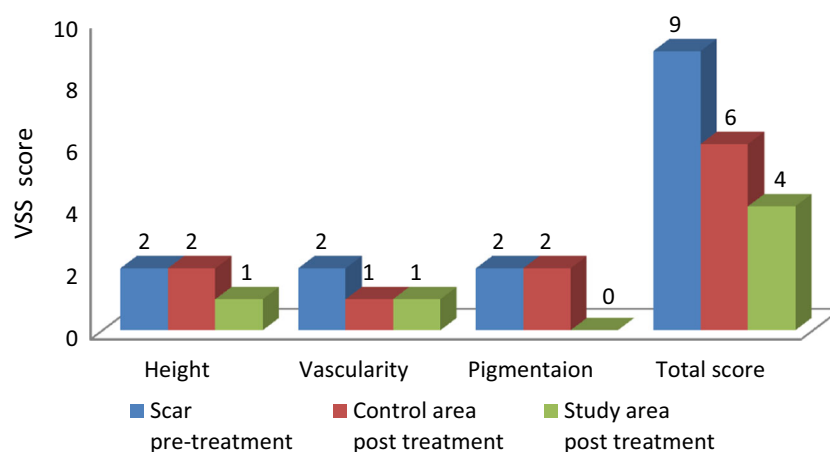
When we compared, the median values before treatment, to those after treatment of Vancouver Scar Scale, we found a significant decrease, since before treatment, the median value of the whole scar was 9, and after treatment, the value of the controlled area was 6, whereas that of the studied area was four with *p* value of (0.001) for both areas. Also, there was a noticeable decrease in the median values of VSS total score of the study area post-treatment, compared to the control area post-treatment, as detected by the Wilcoxon signed ranks test ($P = 0.003$). On analyzing the VSS individual items, the pigmentation and the height were significantly better, after 12 weeks with *P* values of 0.02 and 0.03 respectively.

Discussion

Scarring following burn injuries is difficult to manage. Both the physicians and their patients are highly concerned with the prevention and improvement of scar appearance. They appreciate any minimal improvements in scarring [10]. Low-level lasers showed good therapeutic effects during healing of injuries. However, there have been little studies using PBM in burn scar management, and the improvement of their blood perfusion [8].

This study analyzed the effect of PBM 12-week treatment on scar thickness, perfusion, and macroscopic aspect. Our

Fig. 3 Pre- and post-treatment median values of VSS



study clearly shows that PBM has a beneficial effect on burn hypertrophic scars. When comparing the median values of VSS total score post-treatment, there was a crucial decrease in the studied area to that of the controlled area, indicating clear effects. This is consistent with the results of a study conducted by Shu et al., as they reported that recurrent irradiation with a He-Ne laser, at special power densities, decreases fibroblast proliferation and collagen formation, therefore inhibiting the development of hypertrophic scars [11]. Moreover, our results were supported by a study conducted in 2012, revealing significant changes, after 8 weeks of PBM [12]. However, it questioned scores per item, as it was subjective in evaluating scars depending on who applies the evaluations [13]. This aspect was partially controlled in our study, as evaluations were done by the same researcher.

The U/S scores decrease significantly in both controlled and studied areas after 3 months of treatment, with further decrease in the studied area indicating laser effect, and the U/S as an evaluating tool in scar thickness. Freitas et al. calculated scar thickness by using echography, as ultrasound high frequency measures not only the distance to the surface of the scar skin, but also in-depth fibrosis [14]. We found inhibitory effect of PBM in the studied area, confirmed by a study on scars, as it stated that human skin fibroblasts viability was controlled by the Trypan blue exclusion. It found a significant decline in cellular viability, and an increase in apoptosis when using 632.8-nm He-Ne laser in comparison to normal cells [15].

The perfusion of blood in the scar was measured using the LDPI, which is usually used to detect perfusion in human and animal studies, and is used to determine the role of various mediators on vessel perfusion, as well as how they control healing of burn wounds and evaluate the inflammatory response [16]. In the present study, there was a reduction observed in both controlled and studied areas in the scar perfusion 3 months after. However, when comparing the controlled to the studied areas post-treatment, no significant change was detected, indicating no effect of low-level laser therapy on perfusion to the scar. This

was observed in a study done by Stewart et al., as they evaluated perfusion during scar maturation, showing that the affected skin had respected higher flow than in normal skin. In addition, over time, perfusion over the burn scar gets to normal levels [17].

In the present study, we used He-Ne laser with energy density of 16 J/cm² since it was mentioned in a study by other group that higher doses (10 and 16 J/cm²) cause inhibition of cell viability and mitochondrial activity [18]. Also, this is in agreement with a study by Zungu et al. as they studied low-level laser irradiation effect on mitochondria of normal and injured skin tissues. They found that the power of (5 J/cm²) leads to increase in mitochondrial responses when compared to non-irradiated cells. On the other hand, power of (16 J/cm²) results in a significant decrease in proliferation [15]. Similarly, in another study using He-Ne laser, they compared the exposure to 5 and 16 J/cm². They found that 5 J/cm² increased cellular migration, while a power of 16 J/cm² inhibited it. This could be attributed to DNA damage of normal fibroblast in human skin cells in vitro [16].

Performing laser procedures on patients, with richly pigmented skin (Fitzpatrick skin types IV–VI), results in higher risks for pigmentary alterations, such as potential complications of the procedure. Specifically, hyperpigmentation or hypopigmentation or erythema can occur post procedure, depending on the type of device used, generally the high-power lasers, as discussed in a study done in 2002 [19], while the low-power lasers cause no such side effects as were detected in our results, and many other reported studies.

Conclusion

There are beneficial effects of He-Ne laser (632.8 nm–16 J/cm²) suggesting that a planned regime of treatment with PBM can have significant results of considerable proportions to patients, during the post-burn rehabilitation stage. Also, U/S is an effective evaluating tool for the progress of scar healing,

and its blood perfusion. Further studies are needed with more patient numbers to evaluate the He-Ne laser effect in hypertrophic scar lesions.

Acknowledgements We would like to thank all workers in Pediatrics and Burn Clinics in Cairo University for their cooperation during the research.

Compliance with ethical standards

Conflict of interest The authors declare that they have no conflict of interest.

References

1. Ferguson MW, Duncan J, Bond J, Bush J, Durani P, Lavery H (2009) Prophylactic administration of avotermin for improvement of skin scarring: three double-blind, placebo-controlled, phase I/II studies. *Lancet* 373(9671):1264–1274
2. Alster TS, Tanzi EL (2003) Hypertrophic scars and keloids. *Am J Clin Dermatol* 4(4):235–243
3. Aarabi S, Longaker MT, Gurtner GC (2007) Hypertrophic scar formation following burns and trauma: new approaches to treatment. *PLoS Med* 4(9):e234
4. Anna I, Arno, Gerd G, Gauglitz, Juan P, Barret, and Marc G. Jeschke Up-to-date approach to manage keloids and hypertrophic scars: a useful guide. *Burns* 2014 Nov; 40(7): 1255–1266. Published online 2014 Apr 24. <https://doi.org/10.1016/j.burns.2014.02.011>
5. Guirro E. & Guirro R. (2002) *Fisioterapia dermatofuncional: fundamentos, recursos e patologias*. 3rd ed. Sao Paulo: Manóle
6. Hawkins D, Abrahamse H (2005) Biological effects of helium neon laser irradiation on normal and wounded human skin fibroblasts. *Photo med Laser Surg* 23:251–259
7. Houreld N, Abrahamse H (2008) Laser light influences cellular viability and proliferation in diabetic-wounded fibroblast cells in a dose-and wavelength-dependent manner. *Lasers Med Sci* 23(1): 11–18
8. Gauglitz GG (2013) Management of keloids and hypertrophic scars: current and emerging options. *Clin Cosmet Investig Dermatol* 6:103
9. Ravnbak MH: Objective determination of Fitzpatrick skin type. *Dan Med Bull* 2010 Aug;57(8):B4153
10. Webb C, Dyson M (2003) The effect of 880 nm low level laser energy on human fibroblast cell numbers: a possible role in hypertrophic wound healing. *J Photochem Photobiol B Biol* 70(1):39–44
11. Shu B, Ni GX, Zhang LY, Li XP, Jiang WL, Zhang LQ (2013 May) High-power helium-neon laser irradiation inhibits the growth of traumatic scars in vitro and in vivo. *Lasers Med Sci* 28(3):693–700. <https://doi.org/10.1007/s10103-012-1127-y>
12. Brusselaers N., Pirayesh A., Hoeksema H., Verbelen J., Blot S. & Monstrey S. (2010). Burn scar assessment: a systematic review of different scar scales. *J Surg Res*, 164(1), e115-e123
13. Mozzati M, Martinasso G, Cocero N, Pol R, Maggiora M, Muzio G, Canuto RA (2011) Influence of superpulsed laser therapy on healing processes following tooth extraction. *Photomed Laser Surg* 29(8):565–571
14. Freitas CP, Melo C, Alexandrino AM, Noites A (2013) Efficacy of low-level laser therapy on scar tissue. *J Cosmetic Laser Ther* 15: 171–176
15. Zungu IL, Hawkins Evans D, Abrahamse H (2009) Mitochondrial responses of normal and injured human skin fibroblasts following low level laser irradiation—an in vitro study. *Photochem Photobiol* 85(4):987–996
16. Houreld N, Abrahamse H (2007) In vitro exposure of wounded diabetic fibroblast cells to a Helium-Neon laser at 5 and 16 J/cm². *Photomed Laser Surg* 25(2):78–84
17. Stewart CJ, Frank R, Forrester KR, Tulip J, Lindsay R, Bray RC (2005) A comparison of two laser-based methods for determination of burn scar perfusion: laser Doppler versus laser speckle imaging. *Burns* 31(6):744–752
18. Denise H, Hawkins M, Abrahamse H (2006) The role of laser fluence in cell viability, proliferation, and membrane integrity of wounded human skin fibroblasts following helium-neon laser irradiation. *Lasers Surg Med* 38(1):74–83
19. Goh CL, Khoo (2002) Laser skin resurfacing treatment outcome of facial scars and wrinkles in Asians with skin type III/IV with the Unipulse CO₂ laser system. *Singapore Med J* 43(1):28–32