

Characterization of Skeletal Muscle Strain Lesion Induced by Stretching in Rats: Effects of Laser Photobiomodulation

Luciano Ramos, PhD,¹ Rodrigo Labat Marcos, PhD,² Romildo Torres-Silva, PhD,³ Rodney Capp Pallota, PhD,² Tatiana Magacho, MSc,¹ Fernando Francisco Pazello Mafra, MSc,³ Michel Monteiro Macedo, MSc,³ Rodrigo Leal de Paiva Carvalho, PhD,⁴ Jan Magnus Bjordal, PhD,⁵ and Rodrigo Alvaro B. Lopes-Martins, PhD⁶

Abstract

Background: Unusual and exhaustive physical exercise can lead to muscle lesions depending on the type of contraction, intensity, duration, age, and level of conditioning. Different therapies have been proposed to prevent or reduce exercise-induced muscle damage. In this study, we investigate the effects of low-level laser therapy on skeletal muscle strain in an experimental model in rats. **Materials and methods:** Male Wistar rats (200 g) were used. The animals were randomized into groups of six animals. We performed tibialis muscle elongation using a previously described protocol. The animals were anesthetized and submitted to passive stretching of the anterior tibial muscle attached to a weight corresponding to 150% of the body mass of the animal for 20 min, rested for 3 min, and received a second traction for 20 min. The cytokines, tumor necrosis factor- α (TNF- α), interleukin-1 β (IL-1 β), IL-6, and IL-10, edema, and C-reactive protein (CRP) levels were determined in the tibialis anterior muscle. **Results:** Plasma extravasation of groups treated with different doses of laser energy, lesion +1 J (2.61 ± 0.46), lesion +3 J (2.33 ± 0.13), lesion +6 J (2.92 ± 0.91), and lesion +9 J (2.80 ± 0.55), shows a significant reduction of extravasation when compared with the injury group (5.46 ± 1.09). Laser therapy was able to significantly reduce CRP and cytokine levels (TNF- α , IL-1 β , IL-6, and IL-10). **Conclusions:** Laser photobiomodulation reduced skeletal muscle edema as well as cytokines and CRP, leading to a significant reduction in inflammatory markers.

Keywords: LLLT, inflammation, skeletal muscle strain, photobiomodulation

Introduction

UNUSUAL AND EXHAUSTIVE PHYSICAL exercise leads to structural, ultrastructural, and biochemical reversible and focal changes.^{1,2} Such alterations have an acute pattern called exercise myopathy (EM). Many signs and symptoms that are associated with EM are dependent on the type of contraction (eccentric vs. concentric), intensity, duration,^{3–6} and intrinsic factors, such as age and level of physical conditioning.⁶

Passive elongation and muscle plasticity cause infiltration on muscle fibers, inducing pain after training. These micro-

lesions promote pain, edema, increase of protein synthesis, and an increased muscle size sensation.^{14–16}

This type of exercise promotes histochemical and morphological changes that can affect muscle functioning.^{17,18} Therefore, the main morphological changes occurring at structural and ultrastructural levels in skeletal muscle fibers after intense passive stretching are identified by disarrangement and rupture of myofilaments, Z-lines, sarcomeres, disruption of the architecture, and organelle disorganization. The presence of inflammatory cells and/or satellite cells, basophilia, an increase in ribosomal activity, and centralized

¹Faculdade Pitágoras Guarapari–Rod, Governador Jones dos Santos Neves, Guarapari, Espírito Santo, Brazil.

²Postgraduate Program in Biophotonics Applied to Health Sciences, Universidade Nove de Julho, São Paulo, Brazil.

³Postgraduate Program in Biomedical Engineering, Technological Research Center–NPT, Universidade de Mogi das Cruzes (UMC), Mogi das Cruzes, Brazil.

⁴Laboratório de Pesquisa em Fisioterapia, PPG em Fisioterapia, Universidade do Sagrado Coração, Bauru, São Paulo, Brazil.

⁵Department of Health Sciences, University of Bergen, Bergen, Norway.

⁶Instituto de Pesquisa and Desenvolvimento, Universidade do Vale do Paraíba (UNIVAP), São José dos Campos, São Paulo, Brazil.

nuclei with prominent nucleoli, characterizing protein synthesis and hypercontraction of myofilaments, indicates calcium accumulation.¹⁹ Triggers of muscle injury are promoted by excessive influx of calcium, which is generated by the sarcoplasm damage of fiber. This process causes tissue degeneration, which leads to loss of homeostasis and calcium-dependent proteolysis.^{20,21}

After injury, immune cells are recruited to the tissue. Neutrophils, monocytes, and lymphocytes are recruited to the inflammatory site by prostaglandins. Tumor necrosis factor- α (TNF- α) and interleukin (IL-1 β and IL-6) signaling produce proteolytic enzymes that promote tissue regeneration. Injured muscle fiber is removed by neutrophils by the activated nicotinamide adenine dinucleotide phosphate oxidase enzyme (NADPH oxidase) system and the release of proteolytic enzymes from their intracellular granules. Without being specific, normal adjacent cells to the injured site can be damaged.^{22,23}

Initially, the proinflammatory cytokines, TNF- α and IL-1 β , are synthesized, which stimulate IL-6 synthesis. IL-6 plays the role of the primary mediator of the acute phase reaction, stimulating hepatic production of acute phase proteins such as C-reactive protein (CRP) and protease inhibitors (such as the α -1 protease inhibitor). The acute phase response restores depleted or damaged proteins and still reverses the damaging effects of the initial inflammatory response, so from this angle, IL-6 plays a more restorative rather than a proinflammatory role and further stimulates the pituitary gland to release the adrenocorticotropic hormone, increasing the release of cortisol from the adrenal cortex.^{22,24}

Muscle injury can be indirectly measured, especially in humans, using aspecific protocols. The significant decrease in the maximum voluntary isometric force,^{7–10} a significant increase in muscle discomfort,^{11,12} and IL-1 β , IL-6, lactate dehydrogenase, and glutamic oxaloacetic transaminase¹³ are indirect markers of muscle injury. The levels of these cytokines are elevated when acute muscle injury occurs; however, there is no quantitative relationship between these markers and injury. For muscle injury, different types of pharmacological and nonpharmacological therapies have been proposed with the aim of preventing or at least minimizing the deleterious results of muscle injury. Anti-inflammatory drugs, nutritional supplements (such as creatine and arginine), cryotherapy, massage therapy, electrotherapy, and laser photobiomodulation are some of the proposed therapies.

In this study, we investigate the effects of laser photobiomodulation on skeletal muscle strain in an experimental model in rats. Very few articles have investigated the effects of laser therapy on skeletal muscle injury, especially considering stretching injuries. The hypothesis of the present study is that low-level laser therapy (LLLT) operating in the near-infrared (810 nm) region has anti-inflammatory action and is capable of accelerating the skeletal muscle recovery process after acute injury induced by stretching.

Materials and methods

Animals

Two hundred ten male Wistar rats weighing around 200 g were obtained from the central laboratory of the Institute of Biomedical Sciences of the University of São Paulo (USP). The animals were kept under standard conditions of tem-

perature (22°C–24°C), relative humidity (40–60%), 12-h light–12-h dark cycle, and with water and feed *ad libitum*. Rats were randomized and divided into groups of six animals. The experimental protocols were approved by the Ethics Committee on Animal Experimentation of the Institute of Biomedical Sciences of the University of São Paulo (ICB_USP) (n° 115, 37:2 from June 17th of 2010).

Muscle injury model by passive elongation

We performed tibialis muscle elongation adapted from Nikolaou et al.'s²⁵ protocol described previously. For this procedure, the animals were anesthetized with a mixture of ketamine: xylazine (80:16 mg/kg; König, Avellaneda, Argentina) intraperitoneally (i.p) before being submitted to the passive stretching protocol of the anterior tibial muscle.

Stretching was performed without surgical exposure of the muscle to avoid recruitment of inflammatory cells and other histopathological changes. After weighing the animal, it was positioned, in dorsal decubitus, on a cork attached to the stretching system. The right hind limb was firmly fastened with a line that passed through a pulley and was attached to a weight corresponding to 150% of the body mass of the animal. This line was fixed on the back of the animal's paw, performing a plantar flexion, stretching the anterior tibial muscle of the right hind paw. The protocol was performed only once and the animal received traction for 20 min, rested for 3 min, and received a second traction for 20 min.

Biochemical analysis

Evans blue extravasation. Determination of Evans extravasation as a marker of vascular permeability alteration in rat tibial muscle was performed according to Moitra.²⁶ A 2.5% solution of Evans blue (MERCK article 3169) was prepared in saline solution and subsequently filtered through a sterilizing membrane (0.22 μ m; MILLIPORE).

After anesthesia with ketamine and xylazine, the animals received the Evans blue dye (25 mg/kg, intravenous) 1 h before being sacrificed. After the animals were sacrificed with an anesthetic overdose, the muscle was collected, weighed, and subsequently stored for 24 h at 37°C in a glass tube with a solution of formamide (MERCK article 9684.1000, 5 mL/g) to extract the Evans blue from the samples of muscle.

Then, the tubes were shaken for 15 sec and finally 200 μ L of the dye extracted by formamide was transferred to 96-well microplates for enzyme-linked immunosorbent assay (ELISA; Spectra Max plus 384) at 620 nm, when the formamide solution was used as a blank. The readings were interpolated on a standard dye curve (concentrations between 1000 and 9 μ M). Sample concentrations were calculated in nanograms of Evans blue per milligram of muscle tissue.

C-reactive protein

Latex CRP was determined according to the commercial kit from Wiener Lab (Argentina) as described by Singer et al.²⁷ It is a qualitative and semiquantitative slide agglutination test for rapid determination of CRP, in diluted serum samples, by reaction with specific antibodies absorbed on an inert latex carrier. If a sample has CRP, it reacts with the latex suspension and visible agglutination is formed in 2 min.

For semiquantitative determinations, the serum samples were diluted progressively with saline (1:2, 1:4, 1:8, and 1:16, etc). The last positive (agglutination) dilution was used to calculate the PCR concentration in the sample. The approximate concentration of CRP in the sample was calculated with the following formula: $CRP \text{ (mg/dL)} = \text{titer} \times \text{reaction sensitivity (6 mg dL)}$, where titer is the inverse of the maximum dilution in which macroscopically visible agglutination was produced.

Evaluation of cytokine levels in skeletal muscle

The cytokines, TNF- α , IL-1 β , IL-6, and IL-10, in the tibialis anterior samples were evaluated by the ELISA following commercial kit instructions (R & D System). The reading was carried out using a SpectraMax Plus 384 spectrophotometer (Sunnyvale, CA) at a wavelength of 450 nm with correction at 570 nm. The sample concentrations were calculated from standard curves obtained with the recombinant cytokines. The detection limit for IL-1 β , IL-10, and TNF- α was 1.95 pg/mL, whereas for IL-6, it was 15.6 pg/mL.

Experimental groups of edema development

Characterization of the time curve related to the muscle injury induced by passive elongation using the Evans blue dye to determine plasma extravasation in the tibialis anterior muscle of Wistar rats:

- Group 1: Control—Healthy;
- Group 2: Preinjury—Evans blue was administered 1 h before passive stretching and sacrificed immediately after the lesion;
- Group 3: Injury 1 h—Evans blue was injected immediately after the lesion and sacrificed after 1 h;
- Group 4: Injury 3 h—Evans blue was injected 1 h before sacrifice and sacrificed 3 h after the passive stretching protocol;
- Group 5: Injury 6 h—Evans blue was injected 1 h before sacrifice and sacrificed 6 h after the passive stretching protocol;
- Group 6: Injury 12 h—Evans blue was injected 1 h before sacrifice and sacrificed 12 h after the passive stretching protocol;
- Group 7: Injury 24 h—Evans blue was injected 1 h before sacrifice and sacrificed 24 h after the passive stretching protocol.

Experimental groups of treatments

To compare the effects of different treatments, the following groups were used:

Control group: Healthy animals

Control +3 J: Healthy animals irradiated with 3 J of laser energy

Injury: Animals submitted to the stretching protocol

Diclofenac: Animals submitted to the stretching protocol and treated with sodium diclofenac, 1 mg/Kg

Laser 1 J: Animals submitted to the stretching protocol and treated with 1 J of laser energy

Laser 3 J: Animals submitted to the stretching protocol and treated with 3 J of laser energy

Laser 6 J: Animals submitted to the stretching protocol and treated with 6 J of laser energy

Laser 9 J: Animals submitted to the stretching protocol and treated with 9 J of laser energy

Low-intensity laser therapy

A Theralase (DMC[®]) with 100 mW potency was used, operating at the wavelength of 810 nm, at 1, 3, 6, and 9 J of total energy. For energy delivery, irradiations were performed for 10, 30, 60, and 90 sec consecutively. The laser spot size was 0.028 cm² that resulted in a fluence of 35.7, 107.14, 214.28, and 321.42 J/cm² and power density of 3.57 W/cm².

Statistical analysis

The results are expressed as mean \pm SEM and submitted to unpaired Student *t*-test or analysis of variance, followed by the Student–Newman–Keuls test for multiple comparisons. Values of $p < 0.05$ were considered statistically significant.

Results

Characterization of the time course of edema formation in the skeletal muscle after injury

Figure 1A shows Evans blue extravasation in the anterior tibial muscle of rats after the passive stretching protocol at different times. We observed a statistically significant extravasation of Evans blue in the lesion group at 6 h (6.87 ± 1.47 ng/mL) compared with the control group (3.63 ± 0.50 ng/mL). Figure 1B shows Evans blue plasma extravasation in the anterior tibial muscle in rats in the different groups (control, control +3 J laser, injury, injury + diclofenac, injury + laser 1 J, injury + laser 3 J, injury + laser 6 J, and injury + laser 9 J) within 6 h after the passive stretching protocol. We observed a statistically significant increase in extravasation of the lesion group (5.46 ± 1.09 ng/mL) when compared with the control group (2.73 ± 0.43 ng/mL) ($p < 0.05$).

Plasma extravasation of the groups treated with different doses of laser energy, lesion +1 J (2.61 ± 0.46 ng/mL), lesion +3 J (2.33 ± 0.13 ng/mL), lesion +6 J (2.92 ± 0.91 ng/mL), and lesion +9 J (2.80 ± 0.55 ng/mL), shows a significant reduction of extravasation when compared with the injury group (5.46 ± 1.09 ng/mL) ($p < 0.05$).

Characterization of the time curve of the levels of CRP related to muscle injury induced by passive elongation using the Evans blue dye to determine plasma extravasation in the tibialis anterior muscle of Wistar rats and analysis of levels of CRP after injury and treatment with diclofenac and LLLT

Figure 2A shows levels of CRP in the plasma of rats, on a time curve, after the passive elongation protocol at different times. We observed a significant increase in the 6-h injury group (1382.4 ± 153.60 ng/dL) ($p < 0.001$) and injury 12 h (883.20 ± 282.18 ng/dL) ($p < 0.01$) and injury 24 h (640.00 ± 80.954 ng/dL) ($p < 0.01$) groups when compared with the control group (not detected). When compared with the injured groups, a significant increase in CRP levels was observed in the 6-h injury group (1382.4 ± 153.60 ng/dL) when

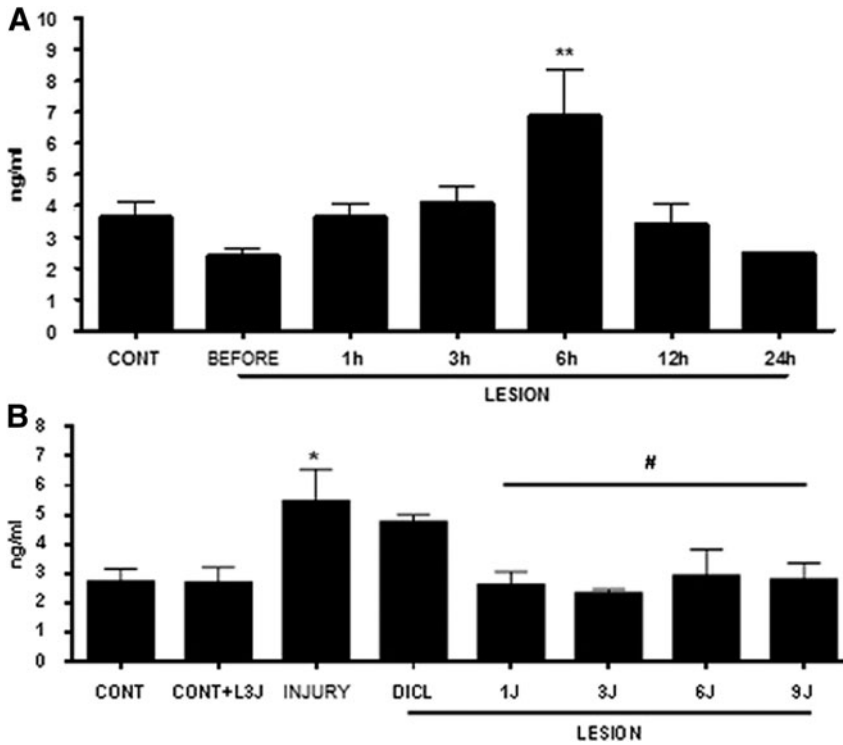


FIG. 1. (A) Characterization of Evans blue plasma extravasation in the tibialis anterior muscle of Wistar rats after a passive stretching protocol at different times; (B) Plasma extravasation of Evans blue in the tibialis anterior muscle of Wistar rats 6 h after the passive stretching protocol. Data represent the mean \pm SEM, $n=5$. (ANOVA, followed by the Student–Newman–Keuls test, ** $p<0.01$ and * $p<0.05$ vs. CONT, # $p<0.05$ vs. INJURY). ANOVA, analysis of variance.

compared with the groups of 12-h (883.20 ± 282.18 ng/dL) ($p<0.05$) and 24-h (640.00 ± 80.954 ng/dL) ($p<0.01$) lesions.

To understand the kinetics of injury, we performed the evaluation of CRP at two different times (Fig. 2B). Figure 2B shows plasma CRP levels in the different groups (control,

control +3J laser, lesion + diclofenac, injury, lesion + laser 1J, lesion + laser 3J, lesion + laser 6J, and lesion + laser 9J) 6 h after the passive stretching protocol. We observed a significant increase in CRP levels when we compared the lesion group (1382.4 ± 153.6 ng/dL) with the control (undetected)

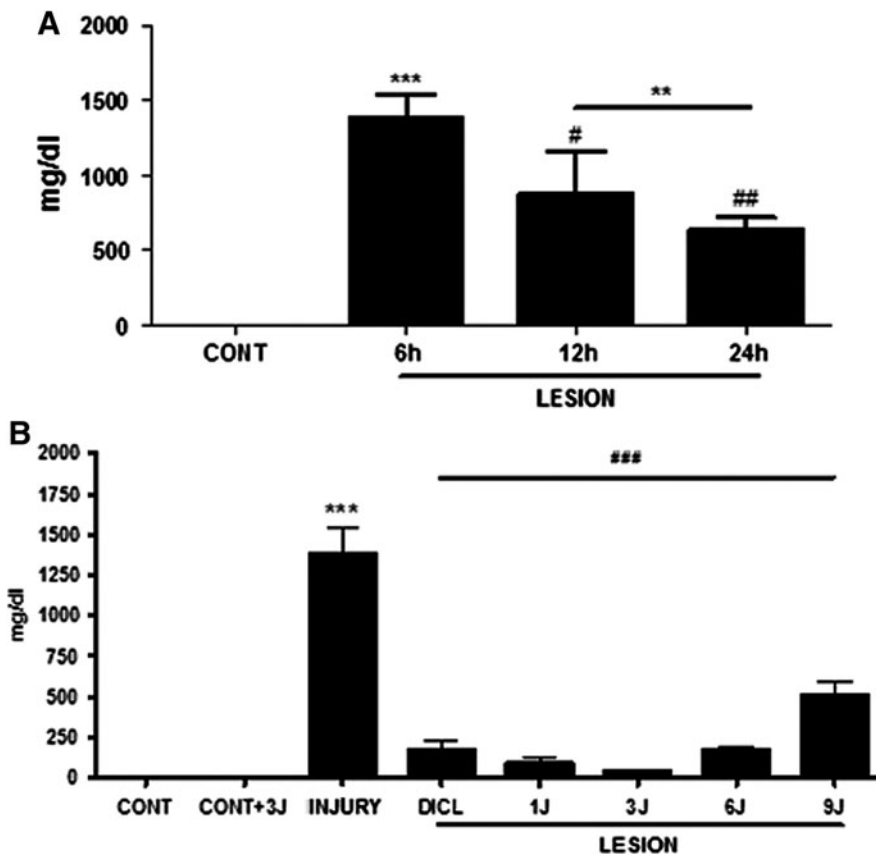


FIG. 2. (A) Characterization of CRP plasma levels of Wistar rats after the passive stretching protocol at different times. The data represent the mean \pm SEM, $n=5$. (ANOVA, followed by the Student–Newman–Keuls test, *** $p<0.001$ and ** $p<0.01$ vs. CONT, # $p<0.05$ and $p<0.01$ vs. injury 6h); (B) Levels of CRP in the plasma of Wistar rats 6 h after the passive stretching protocol. The data represent mean \pm SEM, $n=6$. (ANOVA, followed by the Student–Newman–Keuls test, *** $p<0.01$ vs. CONT and CONT +3J, ### $p<0.01$ vs. INJURY). CRP, C-reactive protein.

and control +3 J (undetected) groups ($p < 0.01$). When we compared the lesion + diclofenac (176.0 ± 50.5 ng/dL), lesion +1 J (96.0 ± 30.3 ng/dL), lesion +3 J (44.0 ± 4.0 ng/dL), lesion +6 J (172.8 ± 19.2 ng/dL), and lesion +9 J (512.0 ± 80.9 ng/dL) groups with the lesion group (1382.4 ± 153.6 ng/dL), we observed a significant reduction in CRP levels ($p < 0.01$) in all of these groups.

Analysis of cytokine levels, TNF- α , IL-1 β , IL-6, and IL-10, in the anterior tibial muscle of rats 12 h after the passive elongation protocol, treated with diclofenac and low-power laser therapy

Figure 3A shows the levels of TNF- α in the anterior tibial muscle of rats in the different groups (control, control +3 J laser, lesion + diclofenac, injury, lesion + laser 1 J, lesion + laser 3 J, lesion + laser 6 J, and lesion + laser 9 J) 12 h after the passive stretching protocol. We observed a statistically significant increase in TNF- α levels when we compared the lesion group (846.60 ± 34.256 pg/g) with the control (187.20 ± 39.047 pg/g) and control +3 J (246.25 ± 58.652 pg/g) ($p < 0.001$) groups. When we compared the lesion + diclofenac (99.200 ± 32.146 pg/g), lesion +1 J (106.00 ± 24.389 pg/g), lesion +3 J (193.00 ± 51.143 pg/g), lesion +6 J (167.20 ± 33.343 pg/g), and lesion +9 J (158.50 ± 25.198 pg/g) groups with the lesion group (846.60 ± 34.256 pg/g), we observed a statistically significant reduction in TNF- α levels in all these groups ($p < 0.001$).

IL-1 β increases (Fig. 3B) when comparing the lesion group (4233.8 ± 140.64 pg/g) with the control (1191.8 ± 202.12 pg/g) and control +3 J (1288.0 ± 158.59 pg/g) ($p < 0.001$) groups. All groups with lesions treated with diclofenac ($1055.6 \pm$

142.80 pg/g), 1 J (708.40 ± 173.66 pg/g), 3 J (1034.0 ± 243.89 pg/g), 6 J (949.00 ± 182.53 pg/g), and 9 J (979.20 ± 94.445 pg/g) had a significant decrease in IL-1 β levels ($p < 0.001$) compared with the lesion group (4233.8 ± 140.64 pg/g).

A significant increase in IL-6 levels (Fig. 3C) was found when comparing the lesion group (1329.3 ± 112.46 pg/g) with the control (351.67 ± 23.253 pg/g) and control +3 J (439.33 ± 55.659 pg/g) ($p < 0.001$) groups. All treated groups, lesion + diclofenac (828.50 ± 226.24 pg/g), lesion +1 J (390.50 ± 68.921 pg/g), +3 J (324.50 ± 12.168 pg/g), lesion +6 J (348.57 ± 29.661 pg/g), and lesion +9 J (401.00 ± 27.492 pg/g), demonstrated reduced levels of IL-6 ($p < 0.001$) when compared with the group (1329.3 ± 112.46 pg/g).

The levels of IL-10 increased (Fig. 3D) in the lesion group (2753.0 ± 351.37 pg/g) compared with the control (429.75 ± 132.44 pg/g) and control +3 J (366.25 ± 189.94 pg/g) ($p < 0.001$) groups. All treated groups, lesion + diclofenac (231.40 ± 77.024 pg/g), lesion +1 J (317.75 ± 94.204 pg/g), lesion +3 J (600.60 ± 179.13 pg/g), lesion +6 J (303.40 ± 60.024 pg/g), and lesion +9 J (447.00 ± 127.24 pg/g), had a statistically significant reduction in IL-10 cytokine levels ($p < 0.001$).

Discussion

In this work, we evaluated the effects of infrared laser irradiation on skeletal muscle injury, using muscle stretching of the rat tibial muscle.

The skeletal striated muscle is the one with greatest biological plasticity and the greatest capacity for remodeling in response to stimuli such as physical activity. In addition, it is also most affected by trauma from sports and daily activities.

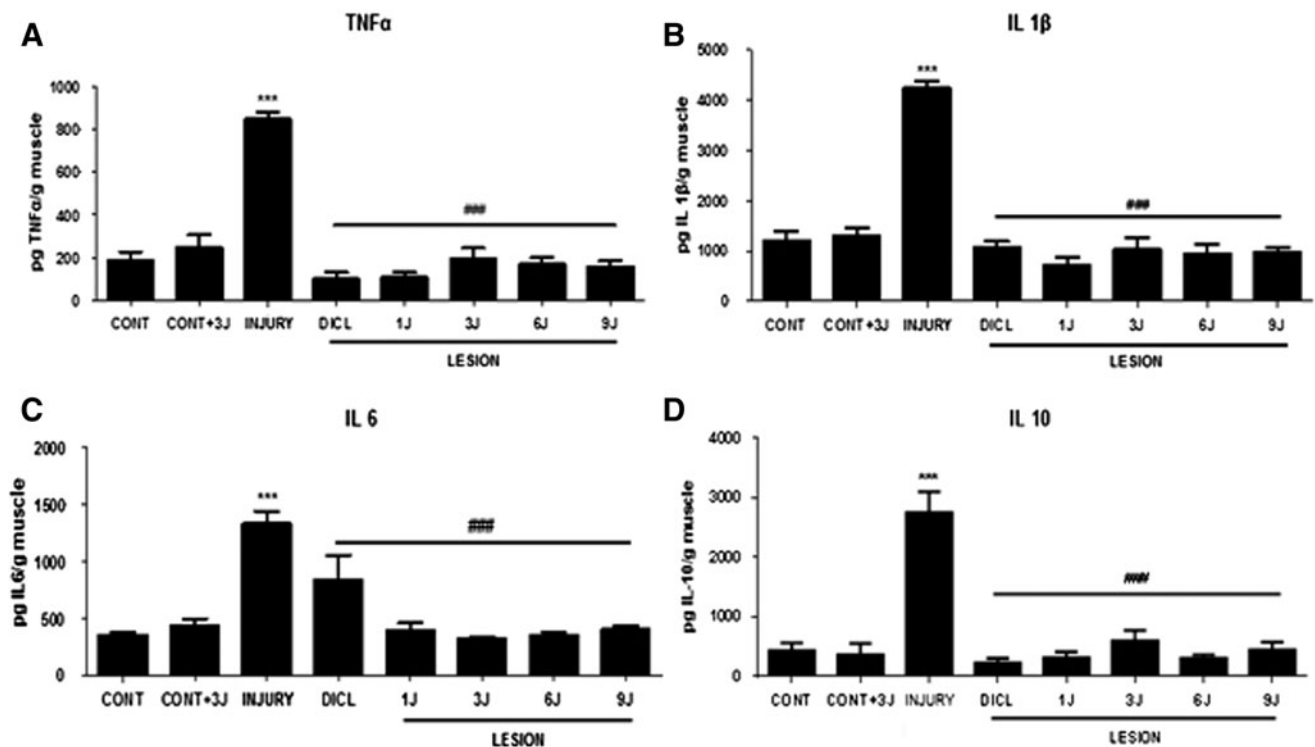


FIG. 3. Cytokine levels in the anterior tibial muscle of Wistar rats 12 h after the passive stretching protocol. (A) TNF- α levels, (B) IL-1 β levels, (C) IL-6 levels, and (D) IL-10 levels. The data represent the mean \pm SEM, $n = 5$. (ANOVA, followed by the Student–Newman–Keuls test, *** $p < 0.001$ vs. CONT and CONT +3 J, ### $p < 0.001$ vs. INJURY).

Muscle lesions often need a long time of immobilization and use anti-inflammatory drugs, which frequently can lead to deleterious effects for the muscles such as increases in collagen fibers as well as a decrease in muscle fibers, contributing to changes in muscle biomechanical properties.²⁸

In this study, we aimed to induce an acute inflammatory process with similar characteristics to those observed in humans, using the muscle stretching protocol. With the Evans blue extravasation method, we could evaluate the effects of laser photobiomodulation on vascular permeability changes due to the lesion. These changes usually occur due to the initial release of substances such as histamine, serotonin, and bradykinin, causing an arteriolar dilation as the main action for induction of vascular permeability increase and allowing extravasation of protein macromolecules from the plasma to the interstitium.²⁹ The edematogenic activity of these mediators may be enhanced by the concomitant action of prostaglandins.³⁰ However, extravasation is important during the inflammatory process.³¹ In addition, albumin extravasation into tissues is not significant under normal physiological conditions. In this experimental model, the Evans blue dye, combined with albumin, undergoes displacement of the intravascular space toward the extravascular space and accumulates in the interstitial space. Further, we observed protein extravasation, and the maximum peak in the injured muscle occurred in the 6-h period (Fig. 1).

In this study, we treated the groups with laser radiation at 1, 3, 6, and 9 J of energy. In parallel, one group was treated with diclofenac at a dose of 1 mg/kg IM (milligram per kilogram intramuscularly), and the results were evaluated 6 h after induction of the lesion. In injury, the tibial muscle reacts by increasing its vascular permeability and releasing various proinflammatory substances. The major cytokines that appear to be involved in these conditions are interleukin-1 (IL-1), TNF- α , and interleukin-6 (IL-6).^{22,24}

According to Ivandic,³² the laser radiation with wavelength of 810 nm was effective in increasing the microcirculatory arterial and capillary flow, being able to act in acute or chronic algic processes and acute or chronic inflammations. Another study by Yousefi-Nooraie³³ and Schindl et al.³⁴ reported the action of low-level laser on exudate reabsorption, elimination of allergic substances, reduction in prostaglandin synthesis, alteration in serotonin metabolism, stimulation of microcirculation, and restoration of normal venous and arteriolar permeability. The results of protein extravasation corroborate with the others studies since a reduction of this extravasation was observed at baseline in the laser-treated groups at 1, 3, 6, and 9 J of energy, 6 h after the injury. These results show an antiedematogenic activity, possibly interfering in the synthesis of prostaglandins, determining the reduction in changes provided by the inflammation, and also helping in resorption of the exudate.

Considering the role of proinflammatory cytokines in the release of prostaglandins, it is possible that the anti-inflammatory effect observed by laser irradiation results from inhibition of TNF- α , which was observed in the present study. Laser irradiation promoted a reduction of TNF- α levels in all treated groups. This effect has been previously described in different experimental models.^{35,36}

TNF- α is a soluble protein called monokine secreted by macrophages and activated by several types of stimuli, including bacterial products, affecting many pathological

processes.³⁷ TNF- α promotes several biological activities, including proliferation, differentiation, and cell death (apoptosis),^{38,39} which stimulate the production of collagenases and increase expression of adhesion molecules required for leukocyte extravasation and inflammation.

Albertini et al.⁴⁰ demonstrated the reduction of 30–40% in TNF- α , IL-1 β , and IL-6 mRNA 3 h after laser irradiation in carrageenan-treated rat subplantar muscle. These results demonstrated that laser photobiomodulation results in an anti-inflammatory action that possibly modulates transcription factors linked to the expression of COX-2 mRNA and proinflammatory cytokines. Aimbire et al.³⁶ administered LLLT in rabbit antiserum ovalbumin (BSA)-induced airway hyper-reactivity models and showed reduced expression of TNF- α levels in the bronchoalveolar lavage after irradiation.

Our results corroborated with the literature when we observed elevated levels of the cytokines, TNF- α , IL-1 β , IL-6, and IL-10, in the lesion induced by passive elongation, where, after the increase of TNF- α , there was an expressive elevation in levels of IL-1 β , indicating muscle injury. With the increase of IL-6, we can infer that there was a sequential release of IL-10 to control the inflammatory reaction.^{22,24}

In our study, we observed that laser irradiation was able to modulate the production of TNF- α to the basal level. TNF- α influences vascular permeability, providing extravasation of muscle injury markers such as the enzyme creatine kinase (CK). Through the obtained data, since muscle strain produces mechanical stress resulting in plasma extravasation and local edema and release of chemical mediators such as TNF- α and CK, laser photobiomodulation seems to inhibit or reduce vascular permeability and the inflammatory cascade.^{41,42}

Laser irradiation was also able to inhibit production of IL-1- β . This fact is crucial for the course of the injury since it suggests a decrease of pain and muscle discomfort and is directly related to the degree of injury. We show that laser photobiomodulation reduced the grade of the lesion in all the energy levels used.⁴³

IL-6 is an intercellular signaling molecule associated with the control and coordination of immune responses and is secreted by macrophages and lymphocytes in response to injury or infection. Increases in IL-6 production may interfere in cell migration and the muscle pain process. In this study, we observed inhibition of IL-6 production in laser-treated groups, which corroborates with inhibition of the inflammatory response.⁴⁴

Once IL-6 is released, it will lead to the synthesis of acute inflammatory phase proteins such as CRP.^{44,22,45} Determination of the plasma concentration of this protein is a good marker to evaluate the presence, extent, and activity of the inflammatory process as well as monitor the evolution and therapeutic response.

CRP can be found in many clinical situations such as rheumatic and cardiovascular diseases, infections, neoplasias, diabetes mellitus, obesity, periodontal disease, chronic obstructive pulmonary disease, smoking, and other diseases related to acute systemic inflammation and it represents a very important aspect in relation to its interaction with the complement system, which is one of the mechanisms of defense of the organism against foreign elements.^{46,47} CRP represents an extremely sensitive indicator of acute inflammation, corroborating the present study. A significant increase was

observed in the injured group in the protocol of 6 and 12 h, characterizing an acute inflammatory picture. After treatment with diclofenac and laser radiation at 1, 3, 6, and 9 J, after both 6 and 12 h, a significant reduction of inflammation with decrease in levels of CRP was observed.

Taken together, our results demonstrate that LLLT (810 nm) was effective in reducing the inflammatory process and muscle damage induced by muscle stretching in rats, leading to a significant improvement in inflammatory markers. Interestingly, all doses of laser energy were able to significantly reduce the inflammatory markers in the skeletal muscle tissue. These results demonstrate the beneficial and therapeutic effects of LLLT in the experimental model of muscle injury induced by stretching in rats.

Acknowledgments

L.R. would like to thank the CNPq for the PhD scholarship and R.A.B.L.M. would like to thank FAPESP for the financial support: Grants No. 2011/18330-1 and CEPID 2013/07276-1.

Author Disclosure Statement

No competing financial interests exist.

References

- Xiong Y, Wu YC, Jin HZ, Gu YH. Randomized controlled trials on the influence and mechanism of manipulation on delayed onset muscle soreness after eccentric exercise. *Zhongguo Gu Shang* 2009;22:669–673.
- Roberts JM, Wilson K. Effect of stretching duration on active and passive range of motion in the lower extremity. *Br J Sports Med* 1999;33:259–263.
- Philippou A, Maridaki M, Bogdanis G, Halapas A, Koutsilieris M. Changes in the mechanical properties of human quadriceps muscle after eccentric exercise. *In Vivo* 2009;23:859–865.
- Duarte J. Cellular lesions of skeletal muscle induced by physical exercise. [Thesis]. Porto: Faculty of Sport Sciences and Physical Education in the University of Porto, 1993.
- Magalhães P. Acute hematological alterations induced by different exhaustive and unusual physical exercise. Master Thesis—Faculty of Sport Sciences and Physical Education at the University of Porto, Porto, 2000.
- Soares J, Duarte J. Exercise myopathy. Etiology, pathophysiology and prevention. *Rev Port Med Desp* 1989;7:187–200.
- MacIntyre DL, Reid WD, Lyster DM, Szasz IJ, McKenzie DC. Presence of WBC, decreased strength, and delayed soreness in muscle after eccentric exercise. *J Appl Physiol* (1985) 1996;80:1006–1013.
- Newham DJ, McPhail G, Mills KR, Edwards RH. Ultrastructural changes after concentric and eccentric contractions of human muscle. *J Neurol Sci* 1983;61:109–122.
- Nosaka K, Clarkson PM. Influence of previous concentric exercise on eccentric exercise-induced muscle damage. *J Sports Sci* 1997;15:477–483.
- Buford TW, Cooke MB, Redd LL, Hudson GM, Shelmadine BD, Willoughby DS. Protease supplementation improves muscle function after eccentric exercise. *Med Sci Sports Exerc* 2009;41:1908–1914.
- Appell HJ, Soares JM, Duarte JA. Exercise, muscle damage and fatigue. *Sports Med* 1992;13:108–115.
- Clarkson PM, Byrnes WC, McCormick KM, Turcotte LP, White JS. Muscle soreness and serum creatine kinase activity following isometric, eccentric, and concentric exercise. *Int J Sports Med* 1986;7:152–155.
- Chen DB, Yang ZM, Hilsenrath R, Le SP, Harper MJ. Stimulation of prostaglandin (PG) F₂ alpha and PGE₂ release by tumour necrosis factor-alpha and interleukin-1 alpha in cultured human luteal phase endometrial cells. *Hum Reprod* 1995;10:2773–2780.
- Warren GL, Hayes DA, Lowe DA, Armstrong RB. Mechanical factors in the initiation of eccentric contraction-induced injury in rat soleus muscle. *J Physiol* 1993;464:457–475.
- LaRoche DP, Connolly DA. Effects of stretching on passive muscle tension and response to eccentric exercise. *Am J Sports Med* 2006;34:1000–1007.
- Liu XG, Zhou YJ, Liu TC, Yuan JQ. Effects of low-level laser irradiation on rat skeletal muscle injury after eccentric exercise. *Photomed Laser Surg* 2009;27:863–869.
- Teague BN, Schwane JA. Effect of intermittent eccentric contractions on symptoms of muscle microinjury. *Med Sci Sports Exerc* 1995;27:1378–1384.
- Philippou A, Bogdanis G, Maridaki M, Halapas A, Sourla A, Koutsilieris M. Systemic cytokine response following exercise-induced muscle damage in humans. *Clin Chem Lab Med* 2009;47:777–782.
- Garrett WE, Jr. Muscle strain injuries. *Am J Sports Med* 1996;24(6 Suppl):S2–S8.
- Chargé SB, Rudnicki MA. Cellular and molecular regulation of muscle regeneration. *Physiol Rev* 2004;84:209–238.
- Buford TW, Cooke MB, Shelmadine BD, Hudson GM, Redd L, Willoughby DS. Effects of eccentric treadmill exercise on inflammatory gene expression in human skeletal muscle. *Appl Physiol Nutr Metab* 2009;34:745–753.
- Nieman DC, Davis JM, Henson DA, Gross SJ, Dumke CL, Utter AC. Muscle cytokine mRNA changes after 2.5 h of cycling: influence of carbohydrate. *Med Sci Sports Exerc* 2005;37:1283–1292.
- Hong Ko HJ, Cho YR, Kim HJ, et al. Interleukin-10 prevents diet-induced insulin resistance by attenuating macrophage and cytokine response in skeletal muscle. *Diabetes* 2009;58:2525–2535.
- Lira FS, Koyama CH, Yamashita AS, et al. Chronic exercise decreases cytokine production in healthy rat skeletal muscle. *Cell Biochem Funct* 2009;27:458–461.
- Nikolaou PK, Macdonald BL, Glisson RR, Seaber AV, Garrett WE, Jr. Biomechanical and histological evaluation of muscle after controlled strain injury. *Am J Sports Med* 1987;15:9–14.
- Moitra J, Sammani S, Garcia JG. Re-evaluation of Evans Blue dye as a marker of albumin clearance in murine models of acute lung injury. *Transl Res* 2007;150:253–265.
- Singer JM, Plotz CM, Parker E, Elster SK. *Am J Clin Path* 1957;28:611.
- Järvinen TA, Józsa L, Kannus P, Järvinen TL, Järvinen M. Organization and distribution of intramuscular connective tissue in normal and immobilized skeletal muscles. An immunohistochemical, polarization and scanning electron microscopic study. *J Muscle Res Cell Motil* 2002;23:245–254.
- Breil I, Koch T, Belz M, Van Ackern K, Neuhof H. Effects of bradykinin, histamine and serotonin on pulmonary vas-

- cular resistance and permeability. *Acta Physiol Scand* 1997;159:189–198.
30. Rákos G, Kis Z, Nagy D, et al. Evans Blue fluorescence permits the rapid visualization of non-intact cells in the perilesional rim of cold-injured rat brain. *Acta Neurobiol Exp (Wars)* 2007;67:149–154.
 31. Yasuda S, Ikuta K, Uwatoku T, et al. In vivo magnetic resonance imaging of atherosclerotic lesions with a newly developed Evans blue-DTPA-gadolinium contrast medium in apolipoprotein-E-deficient mice. *J Vasc Res* 2008; 45:123–128.
 32. Ivandic BT, Ivandic T. Low-level laser therapy improves vision in patients with age-related macular degeneration. *Photomed Laser Surg* 2008;26:241–245.
 33. Yousefi-Nooraie R, Schonstein E, Heidari K, et al. Low level laser therapy for nonspecific low-back pain. *Cochrane Database Syst Rev* 2008 April 16;2:CD005107.
 34. Schindl A, Schindl M, Pernerstorfer-Schön H, Schindl L. Low-intensity laser therapy: a review. *J Investig Med* 2000; 48:312–326.
 35. Aimbire F, Bjordal JM, Iversen VV, et al. Low level laser therapy partially restores trachea muscle relaxation response in rats with tumor necrosis factor alpha-mediated smooth airway muscle dysfunction. *Lasers Surg Med* 2006; 38:773–778.
 36. Aimbire F, Lopes-Martins RA, Castro-Faria-Neto HC, et al. Low-level laser therapy can reduce lipopolysaccharide-induced contractile force dysfunction and TNF-alpha levels in rat diaphragm muscle. *Lasers Med Sci* 2006;21:238–244.
 37. Gwozdziejczová S, Lichnovská R, Ben Yahia R, Chlup R, Hřebíček J. TNF-alpha in the development of insulin resistance and other disorders in metabolic syndrome. *Biomed Pap Med Fac Univ Palacky Olomouc Czech Repub* 2005;149:109–117.
 38. Pausova Z, Deslauriers B, Gaudet D, et al. Role of tumor necrosis factor-alpha gene locus in obesity and obesity-associated hypertension in French Canadians. *Hypertension* 2000;36:14–19.
 39. Boucher J, Castan-Laurell I, Daviaud D, et al. Adipokine expression profile in adipocytes of different mouse models of obesity. *Horm Metab Res* 2005;37:761–767.
 40. Albertini R, Villaverde AB, Aimbire F, et al. Cytokine mRNA expression is decreased in the subplantar muscle of rat paw subjected to carrageenan-induced inflammation after low-level laser therapy. *Photomed Laser Surg* 2008;26:19–24.
 41. Felismino AS, Costa EC, Aoki MS, Ferraresi C, de Araujo Moura Lemos TM, de Brito Vieira WH. Effect of low-level laser therapy (808nm) on markers of muscle damage: a randomized double-blind placebo-controlled trial. *Lasers Med Sci* 2014;29:933–938.
 42. Leal Junior EC, Lopes-Martins RA, Frigo L, et al. Effects of low-level laser therapy (LLL) in the development of exercise induced skeletal muscle fatigue and changes in biochemical markers related to postexercise recovery. *J Orthop Sports Phys Ther* 2010;40:524–532.
 43. Zagatto AM, de Paula Ramos S, Nakamura FY, de Lira FS, Lopes-Martins RA, de Paiva Carvalho RL. Effects of low-level laser therapy on performance, inflammatory markers, and muscle damage in young water polo athletes: a double-blind, randomized, placebo-controlled study. *Lasers Med Sci* 2016;31:511–521.
 44. Smit E, Pretorius E, Anderson R, Oommen J, Potjo M. Differentiation of human monocytes in vitro following exposure to Canova in the absence of cytokines. *Ultrastruct Pathol* 2008;32:147–152.
 45. Rogero MM, Mendes RR, Tirapegui J. Síndrome de overtraining. *Arq Bras Endocrinol Metab* 2005;49:359–368.
 46. Danesh J, Wheeler JG, Hirschfield GM, et al. C-reactive protein and other circulating markers of inflammation in the prediction of coronary heart disease. *N Engl J Med* 2004; 350:1387–1397.
 47. Sin DD, Man SF. Why are patients with chronic obstructive pulmonary disease at increased risk of cardiovascular diseases? The potential role of systemic inflammation in chronic obstructive pulmonary disease. *Circulation* 2003; 107:1514–1519.

Address correspondence to:

Rodrigo Alvaro B. Lopes-Martins, PhD

Laboratory of Biophotonics and Experimental Therapeutics

Institute of Research and Development

University of Vale do Paraíba (UNIVAP)

Av. Shishima Hifumi 2911–Urbanova

São José dos Campos 12244-000

São Paulo

Brazil

E-mail: ralopesmartins@gmail.com

Received: March 26, 2018.

Accepted after revision: April 27, 2018.

Published online: August 7, 2018.